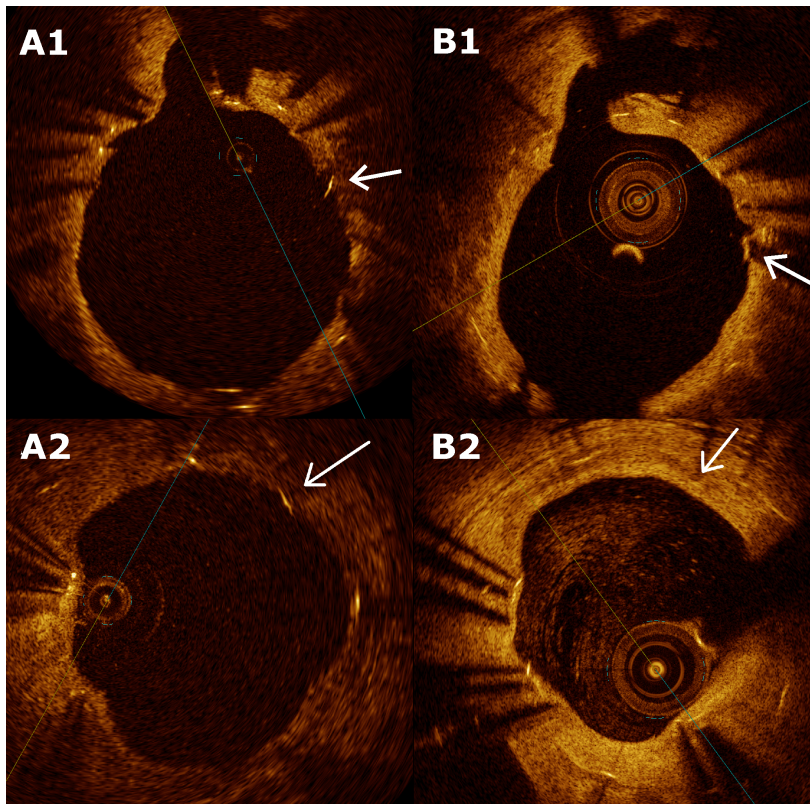


Suppl. Fig 4.

Strut coverage patterns in the very long-term follow-up.

Optical coherent tomography (OCT) serial documentation of change in strut classification in different types of DES. Panels demonstrate tissue growth over PES (A1, B1) and SES (A2, B2) strut at 3- and 9-year OCT follow up. On the panels (A1, A2) the strut pointed by white arrow is classified as well-apposed uncovered strut, whereas white arrow on the panels (B1, B2) point at the same strut already covered in 9-years follow up.



SES- sirolimus-eluting stent, PES – paclitaxel-eluting stent