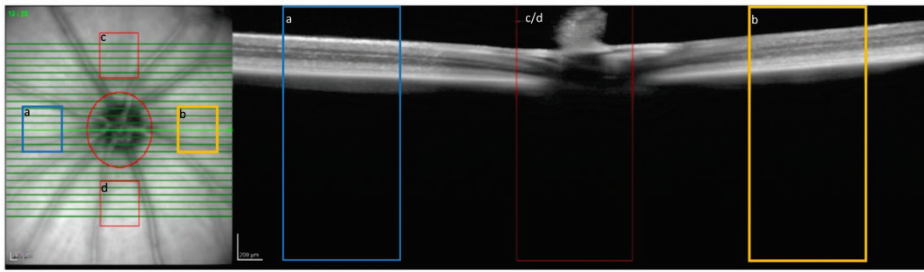


Supplementary Figure 4



Supplementary Figure 4. The template used for assessment of retinal layer thicknesses.

An infra-red fundus image (left) and the SD-OCT scan at the matching location (right). The Green arrow on the fundus image (left panel) indicates the position of the SD-OCT scan (right panel). The colored rectangles (marked a-d) denote the designated areas for measurement. A single measurement was taken within each sector, a total of 4 measurements per eye, per time point.