

## Supplementary Online Content

Vianello S, de Souza GS, Maia M, Belfort R Jr, de Oliveira Dias JR. Ocular findings in yellow fever infection. *JAMA Ophthalmol*. Published online January 10, 2019. doi:10.1001/jamaophthalmol.2018.6408

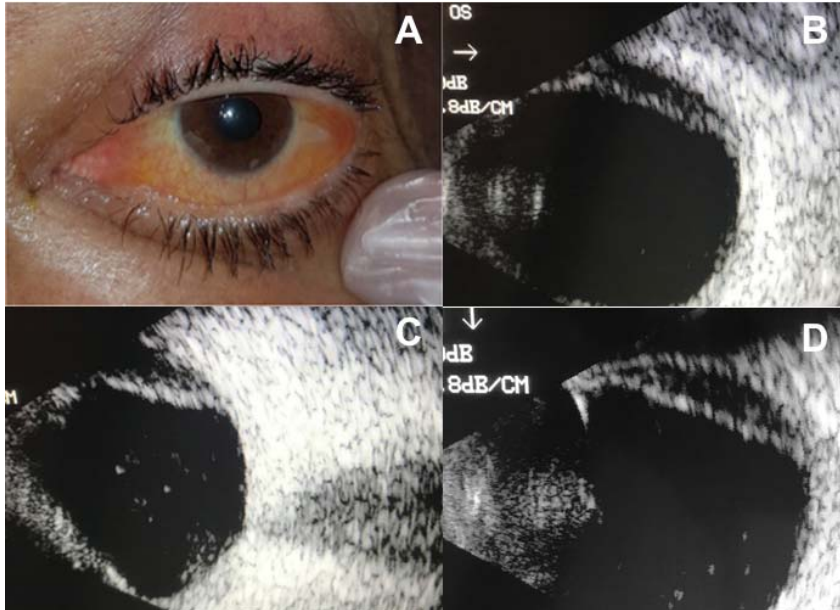
**eFigure 1.** Ocular Findings in Patient 1

**eFigure 2.** Ocular Findings in Patient 2

This supplementary material has been provided by the authors to give readers additional information about their work.

**eFigure 1. Ocular Findings in Patient 1**

**A**, An external image of the left eye shows mild conjunctival chemosis and icterus. **B-D**, Mid-peripheral choroidal detachments in the left eye and low-reflectivity echoes.



**eFigure 2. Ocular Findings in Patient 2**

**A, B,** The fundus autofluorescence is unremarkable in both eyes.

