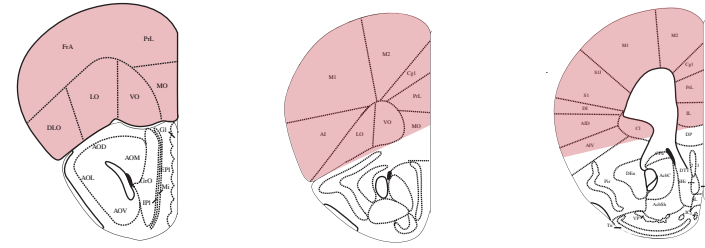
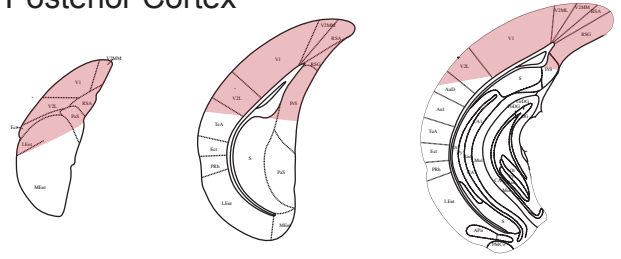


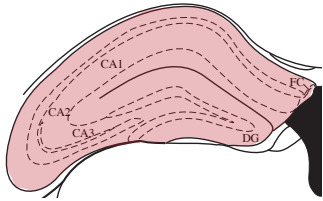
A. Frontal Cortex



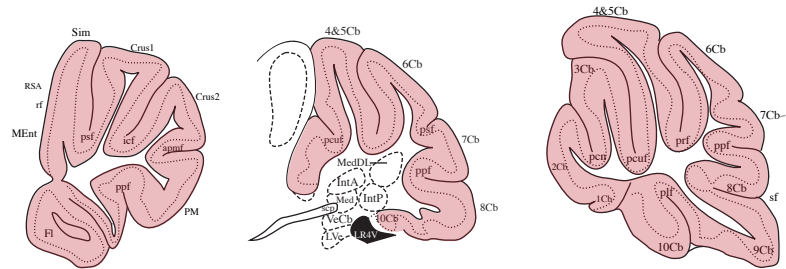
B. Posterior Cortex



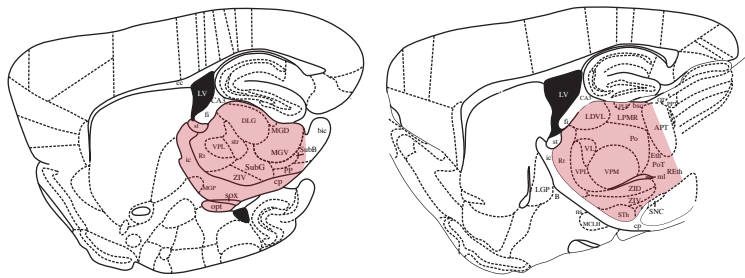
C. Hippocampus



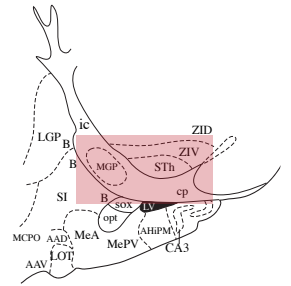
D. Cerebellum



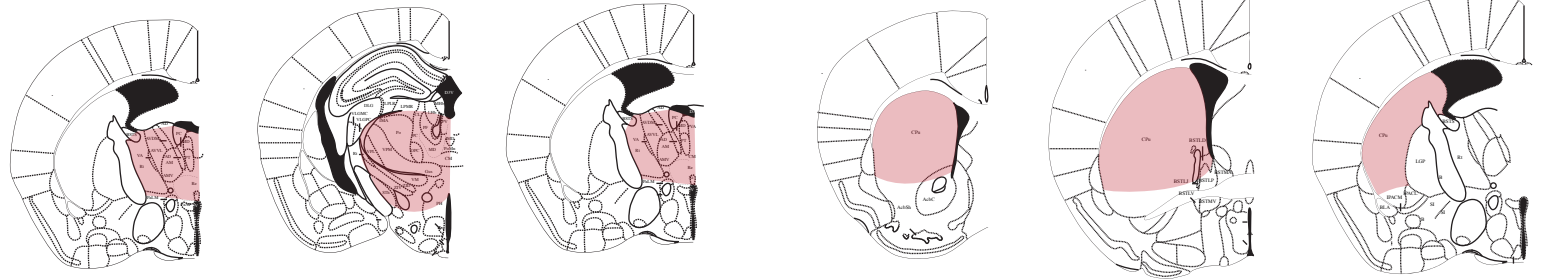
E. Thalamus



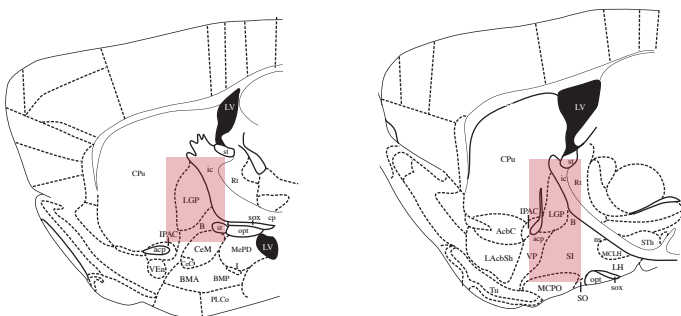
F. Entopeduncular Nucleus



G. Striatum



H. Globus Pallidus Externus / Nucleus Basalis



I. Substantia Nigra / Ventral Tegmental Area

