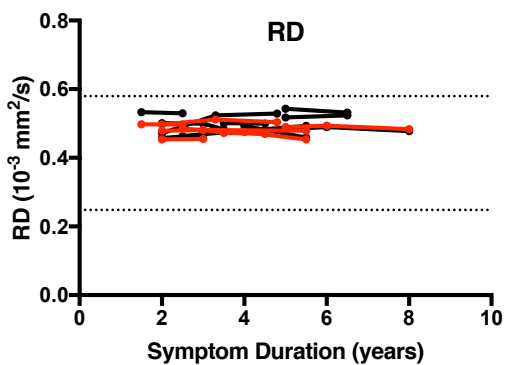
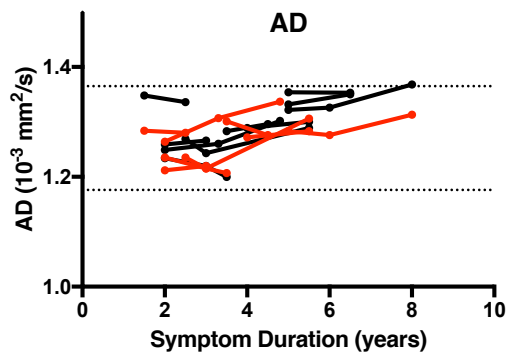
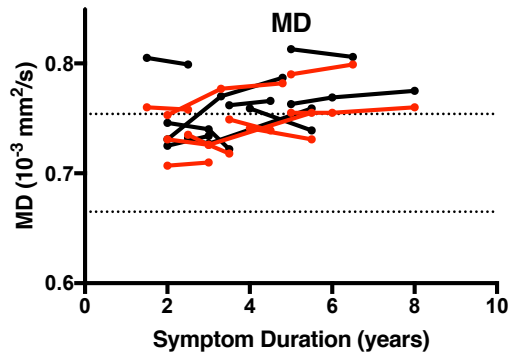
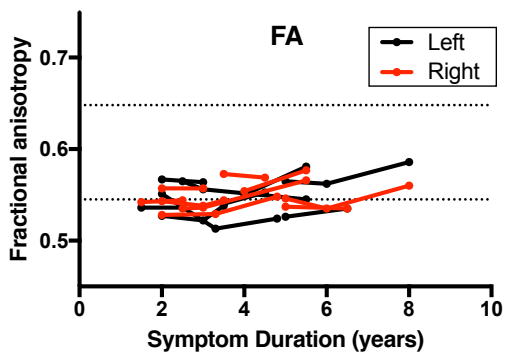
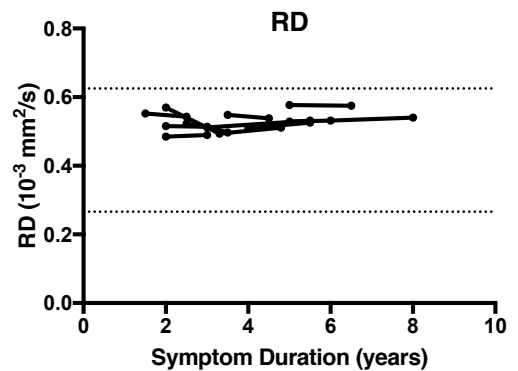
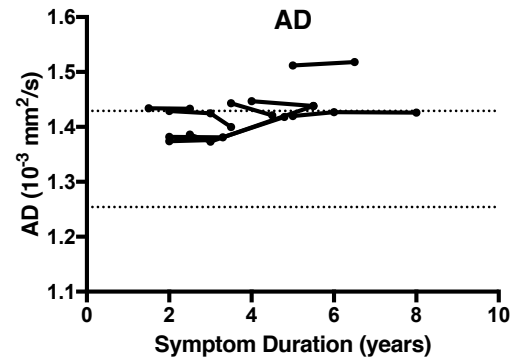
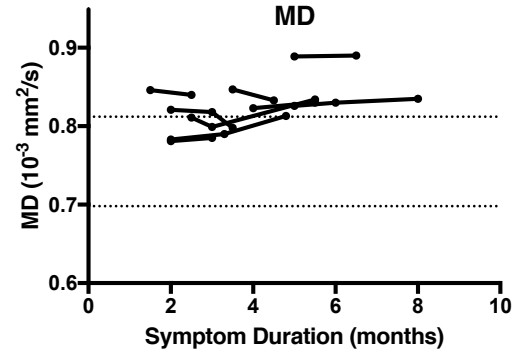
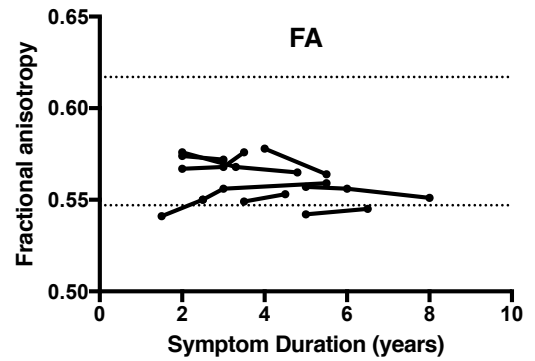


Corticospinal Tract



Callosal motor segment



Supplemental Figure. Longitudinal diffusion tensor measures of the corticospinal tract (left panels) and motor segment of the corpus callosum (right panels; red=right CST; black=left CST) in eight pre-PLS patients. Each line represents measures from an individual patient. Pre-PLS patients had 5 years or less of symptoms at first evaluation, and continued to have only upper motor neuron symptoms in subsequent clinical evaluations beyond 5 years. Dotted lines indicate 2SDs above and below control mean.