

Supplementary Information

The loss of succinate dehydrogenase B expression is frequently identified in hemangioblastoma of the central nervous system

Tae Hoon Roh^{1,+}, Hyunee Yim^{2,+}, Jin Roh², Kyi Beom Lee², So Hyun Park², Seon-Yong Jeong³,
Se-Hyuk Kim^{1,*}, Jang-Hee Kim^{2,*}.

¹ Department of Neurosurgery, Ajou University School of Medicine, Suwon, 16499, Korea

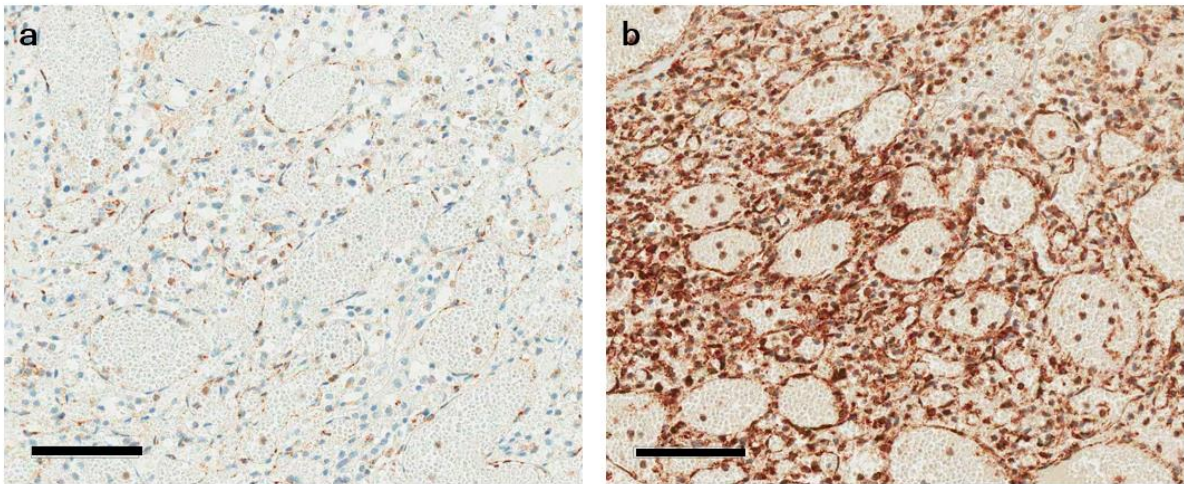
² Department of Pathology, Ajou University School of Medicine, Suwon, 16499, Korea

³ Department of Medical Genetics, Ajou University School of Medicine, Suwon, 16499, Korea

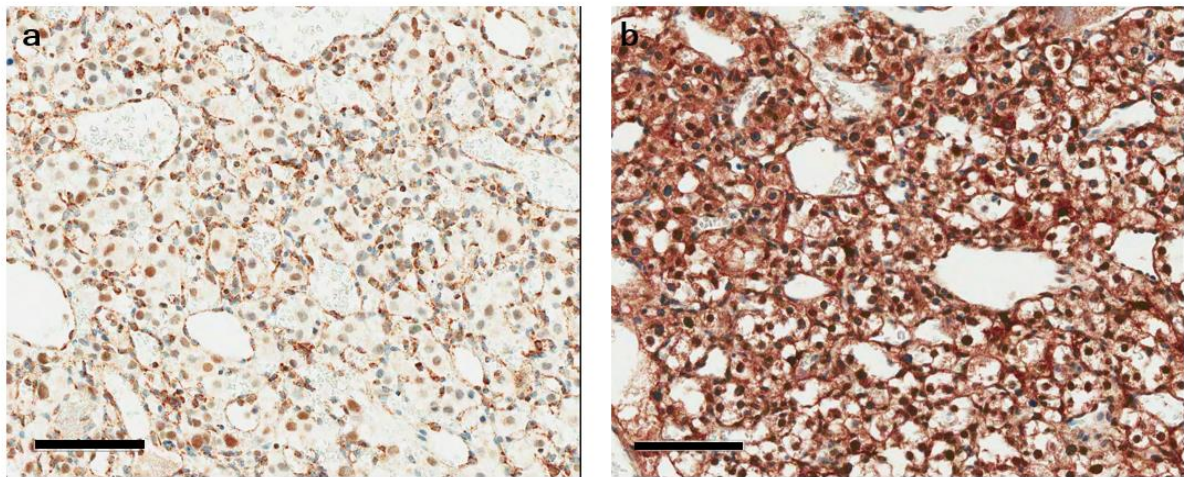
Contents

Supplemental Figure S1. SDHB and SDHA immunohistochemistry in hemangioblastoma.

Supplemental Figure S2. HIF-1 α expression in hemangioblastoma with a weak-diffuse pattern of SDHB immunostaining.



Supplementary Figure S1. SDHB and SDHA immunohistochemistry in hemangioblastoma. (a) Negative SDHB immunostaining in the stromal tumor cells and (b) Positive SDHA immunostaining at the corresponding area of hemangioblastoma. Bar indicates 100 μm .



Supplementary Figure S2. HIF-1 α expression in hemangioblastoma with a weak-diffuse pattern of SDHB immunostaining. (a) a weak-diffuse pattern of SDHB immunostaining (b) HIF-1 α immunostaining in the corresponding areas. Increased expressions of HIF-1 α are noted at the nuclei and cytoplasm of the stromal tumor cells in hemangioblastoma. Bar indicates 100 μm .