

Supplementary Data



HEALTHCAREIMAGING, LLC

ULTRASOUND

Medical Director, Board Certified Radiologist

Thyroid Ultrasound

Name: [REDACTED] DOB: [REDACTED] DATE: [REDACTED]

Referred by: [REDACTED]

History & Indications: R Thy nodules + A3p

Right: 3.4 x 1.9 x 1.7

Case #4

Nodules: Y N

MP: 1.5 x 1.4 x 1.4

MP: Bx 1.7 x 1.6 x 1.4

LP: 1.5 x 1.7 x 1.7

Isthmus: 1.2

Nodules: Y N

Size: _____

Left: 4.4 x 1.4 x 1.3

Nodules: Y N

UP: _____

MP: _____

LP: _____

Parathyroids: Y R _____ L _____

Abnormal LN: Y R _____ L _____

Biopsy: Y N/RT MID Isthmus _____ LT _____ RTLN _____ LTLN _____

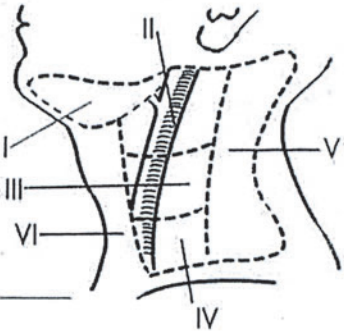
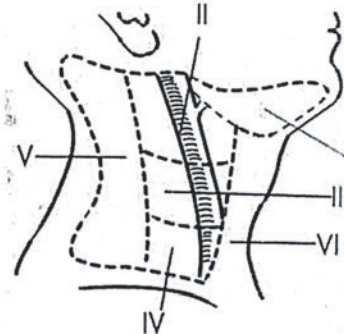
IMPRESSION:

Probable Benign: MNG _____ Colloid cyst _____ Hemorrhagic _____ Thyroiditis _____

Indeterminate: R/O follicular _____ R/O cancer _____

Consider: Pap _____ Med _____ Anaplastic _____ Other _____

LN: Probable Benign _____ Indeterminate _____ Consider Mets _____



SUPPLEMENTARY FIG. S1. Drawings of thyroid nodules with those sampled by fine-needle aspiration (FNA) marked as Bx by the ultrasonographer with the FNA. This is available at the time of gross examination of the thyroid resection.