

Multi-platform imaging in ABCA4-Associated Disease

Authors: Lijuan Chen^{1,2}, Winston Lee¹, Jose Ronaldo Lima de Carvalho-Jr^{1,3,4}, Stanley Chang¹, Stephen H. Tsang^{1,5}, Rando Allikmets^{1,5}, Janet R. Sparrow^{1,5*}

Affiliations:

¹Department of Ophthalmology, Columbia University, New York, New York, United States

²Department of Ophthalmology, People's hospital of Putuo District, Shanghai, China

³Departament of Ophthalmology, Empresa Brasileira de Servicos Hospitalares (EBSERH) - Hospital das Clinicas de Pernambuco (HCPE), Federal University of Pernambuco (UFPE), Recife, Brazil.

⁴Department of Ophthalmology, Federal University of São Paulo (UNIFESP), São Paulo, Brazil

⁵Department of Pathology and Cell Biology, Columbia University, New York, New York, United States

*Corresponding author: jrs88@cumc.columbia.edu

Supplementary Materials

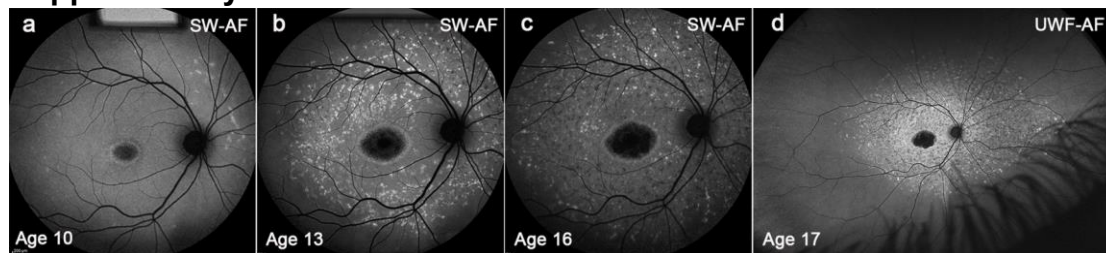


Figure S1. Longitudinal disease changes in STGD1 patient with early onset. Group III. Patient (P) 20. (a) Blue/SW-AF. At baseline, age 10, some flecks are visible in the superonasal field. (b) Blue/SW-AF. Age 13, flecks have spread throughout the 55° field. (c) Blue/SW-AF. Age 16. Flecks are more widespread than is visible within the 55° field (d) Green/UWF-AF. Age 17. Flecks extend into far peripheral retina.