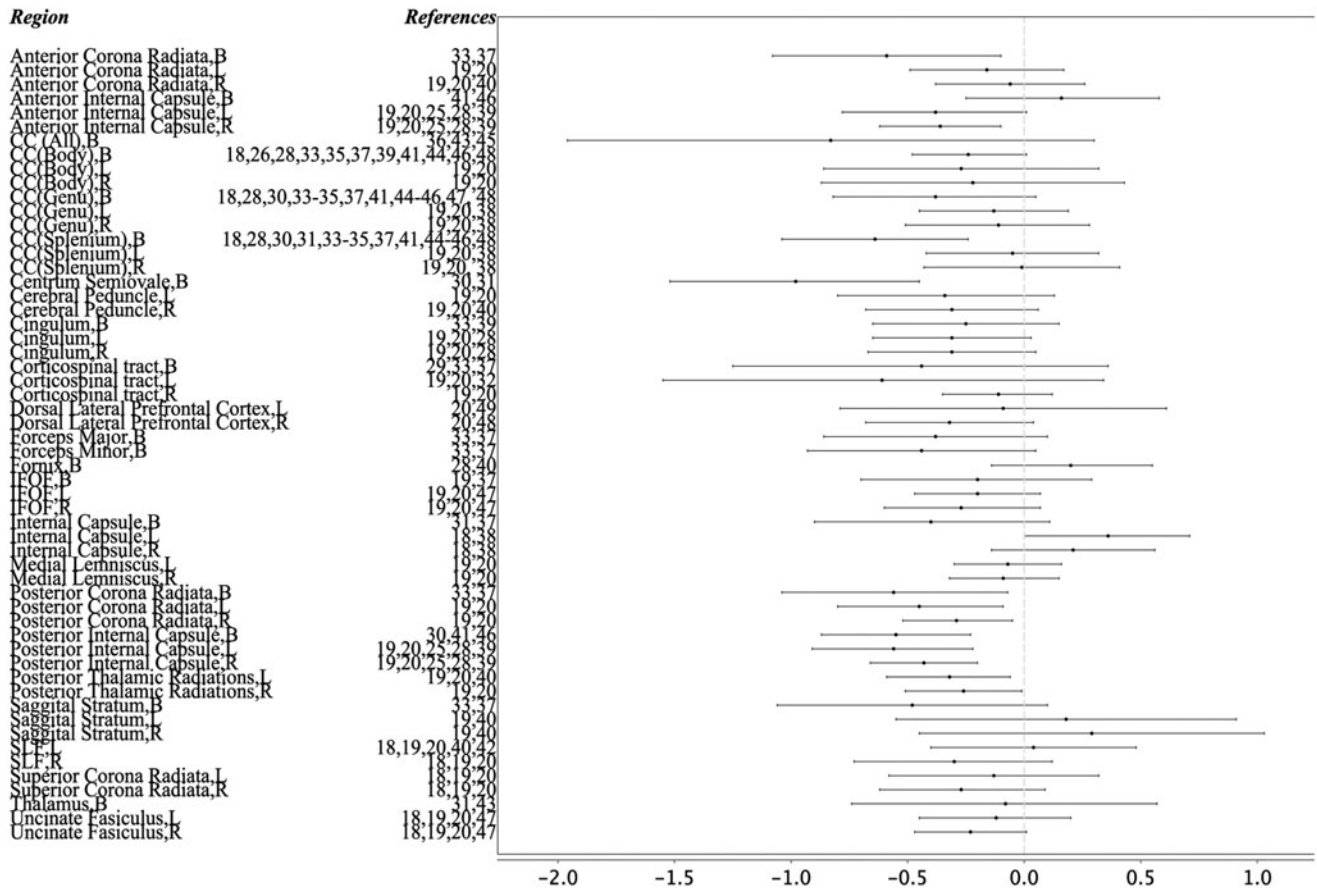


## Supplementary Data



**SUPPLEMENTARY FIG. 1.** Hedges'  $g$  and 95% confidence interval in all fractional anisotropy regions. B, bilateral; CC, corpus callosum; IFOF, inferior fronto-occipital fasciculus; L, left; R, right; SLF, superior longitudinal fasciculus.