

Field Methods for Collection and Preservation of Mammalian Parasites



Field lab for small mammal and parasite processing, Mongolia, 2016. From the front, clockwise: ectoparasite sweeps (Christina Frangel), specimen data (Schuyler Liphardt), carcass skinning (Justin Linn), tissue pulling (Donavan Jackson), endoparasite processing (Bat-Oyun Ochirbat, Stephen Greiman, Lily Moncman). Credit: K. E. Galbreath.

Citation: GALBREATH, K. E., E. P. HOBERG, J. A. COOK, B. ARMIEN, K. C. BELL, M. L. CAMPBELL, J. L. DUNNUM, A. T. DURSAHINHAN, R. P. ECKERLIN, S. L. GARDNER, S. E. GREIMAN, H. HENTTONEN, F. A. JIMÉNEZ, A. V. A. KOEHLER, B. NYAMSUREN, V. V. TKACH, F. TORRES-PÉREZ, A. TSVETKOVA, AND A. G. HOPE. 2019. Building an integrated infrastructure for exploring biodiversity: field collections and archives of mammals and parasites. *Journal of Mammalogy*. DOI:10.1093/jmammal/gyz048

"It will be observed, then, that our efforts are not merely to accumulate as great a mass of animal remains as possible. On the contrary, we are expending even more time than would be required for the collection of the specimens alone, in rendering what we do obtain as permanently valuable as we know how, to the ecologist as well as to the systematist."

Joseph Grinnell, 1910. The uses and methods of a research museum. *Popular Science Monthly* 77:163-169.



Joseph Grinnell preparing small mammal specimens in the field.

We dedicate this manual to Robert L. and Virginia R. Rausch who epitomized the concept of maximizing long-term value of every collected specimen for resolving biodiversity connections.



Shown here: (top) with American colleague Kenneth A. Neiland (seated) during field work in far eastern Siberia, on the Taigonos Peninsula, Magadanskaya Oblast, Russia, in 1977 (Credit: V. L. Kontramavichus); (bottom) Robert and Virginia Rausch.



TABLE OF CONTENTS

1. Introduction	p.1
2. Data tracking.....	p.3
3. Mammal collecting	p.5
4. Parasite collecting	p.6
4.1 Overview	p.6
4.2 Note on ethanol preservation.....	p.6
4.3 Ectoparasites	p.7
4.4 Endoparasites	p.9
4.4.1 General necropsy protocol for small mammals.....	p.10
4.4.2 Dissecting the small intestine	p.12
4.4.3 Dissecting the stomach.....	p.14
4.4.4 Dissecting the large intestine.....	p.14
4.4.5 Finishing steps	p.15
4.5 Necropsy protocol for shrews.....	p.15
4.6 Parasite collection during mammal skinning	p.16
4.7 Sampling tissue-dwelling nematodes of ungulates	p.16
4.8 Sampling for viruses, bacteria or protozoans.....	p.18
5. Helminth preservation.....	p.21
5.1 Nematodes	p.21
5.2 Cestodes.....	p.21
5.3 Trematodes	p.22
5.4 Acanthocephalans	p.22
6. Long-term storage of specimens	p.22
7. Personnel safety	p.24
8. Literature cited.....	p.25
9. Field processing equipment list	p.27
9.1 Trapping supplies.....	p.27
9.2 Small mammal processing supplies.....	p.27
9.2.1 Field lab	p.27
9.2.2 Study skins.....	p.28
9.3 Parasite processing supplies	p.29
9.3.1 Ecto- and endo-parasite sampling.....	p.29
9.3.2 Coccidia sampling.....	p.30
9.3.3 Fecal pellet sampling.....	p.30
9.3.4 Blood sampling	p.30
9.3.5 Protostrongylid larvae sampling.....	p.30

LIST OF FIGURES

Figure 1. Field lab set-up	p.2
Figure 2. Example data sheet	p.4
Figure 3. Example of cap and wrap barcode labels	p.5
Figure 4. Flow chart for small mammal necropsy	p.8
Figure 5. Beaker-Baermann protocol for isolating protostrongylid larvae	p.20

1. INTRODUCTION

This manual provides field-tested methods for collecting parasites from mammals. These methods are based on techniques that were established by earlier generations of parasitologists (e.g., Pritchard and Kruse 1982; Gardner 1996) and refined based on our own experiences conducting museum-based mammal-parasite surveys across diverse ecosystems spanning multiple continents. They complement detailed protocols described for other vertebrate groups (e.g., birds; Lutz et al. 2017). We owe a particular debt to Robert and Virginia Rausch, who pioneered integrated mammal-parasite investigations over six decades of field research in Alaska, Siberia, and around the world (e.g., Rausch 1952, 1957, 1963, 1994). Their contributions to both mammalogy and parasitology offer a model that demonstrates how integrated collections enhance understanding of the ecology and evolution of complex ecosystems.

Our goal is to arm a new generation of mammalogists with tools that allow them to collect and archive well-preserved parasite specimens from the mammals that they study. Implementation of these methods should not be considered to fully replace the contributions of a trained parasitologist on a field crew, but they serve as a set of best practices to help non-parasitologists collect parasite specimens of reasonable quality without requiring extensive specialized training. Despite efforts to keep our recommendations streamlined and practical for non-parasitologists to implement, we recognize that many mammalogists may not have time or resources to incorporate all of these methods into their own field protocols immediately. We encourage mammalogists not to feel that they must accomplish everything described here, but rather they should identify those aspects of mammal necropsy and parasite collection that they can fit into their existing field protocols so as to enhance the value of the mammals they collect and to open new avenues for investigation and collaboration. As interest grows and new opportunities arise, additional types of parasitological sampling can be incrementally added to their collecting programs. Most importantly, collected parasite specimens should be of high quality and associated with their host specimen.

A few key reminders should help to ensure that parasite specimens collected today will continue to be useful for addressing research questions into the future:

- i. Host and parasite data must remain linked and tracked from field, to museum, to products.
- ii. Mammals should be necropsied as soon as possible after death.
- iii. For morphological identification to be possible, helminths must be relaxed and killed using methods appropriate to the taxon prior to preservation.
- iv. In most cases, ectoparasites should be preserved in 95% ethanol and endoparasites should be preserved in 80% ethanol.
- v. As a rule of thumb, ethanol-preserved parasites should be stored at -20°C.

We advocate conducting field necropsies using an assembly-line model (e.g. cover image; Fig. 1), in which each specimen moves through a succession of stations at which individual workers complete specific necropsy tasks (e.g., ectoparasite sweeps, measurements, tissue pulling, gut examination). This maximizes the efficiency with which specimen preparation is completed to minimize limitations on the number of specimens that can be processed.

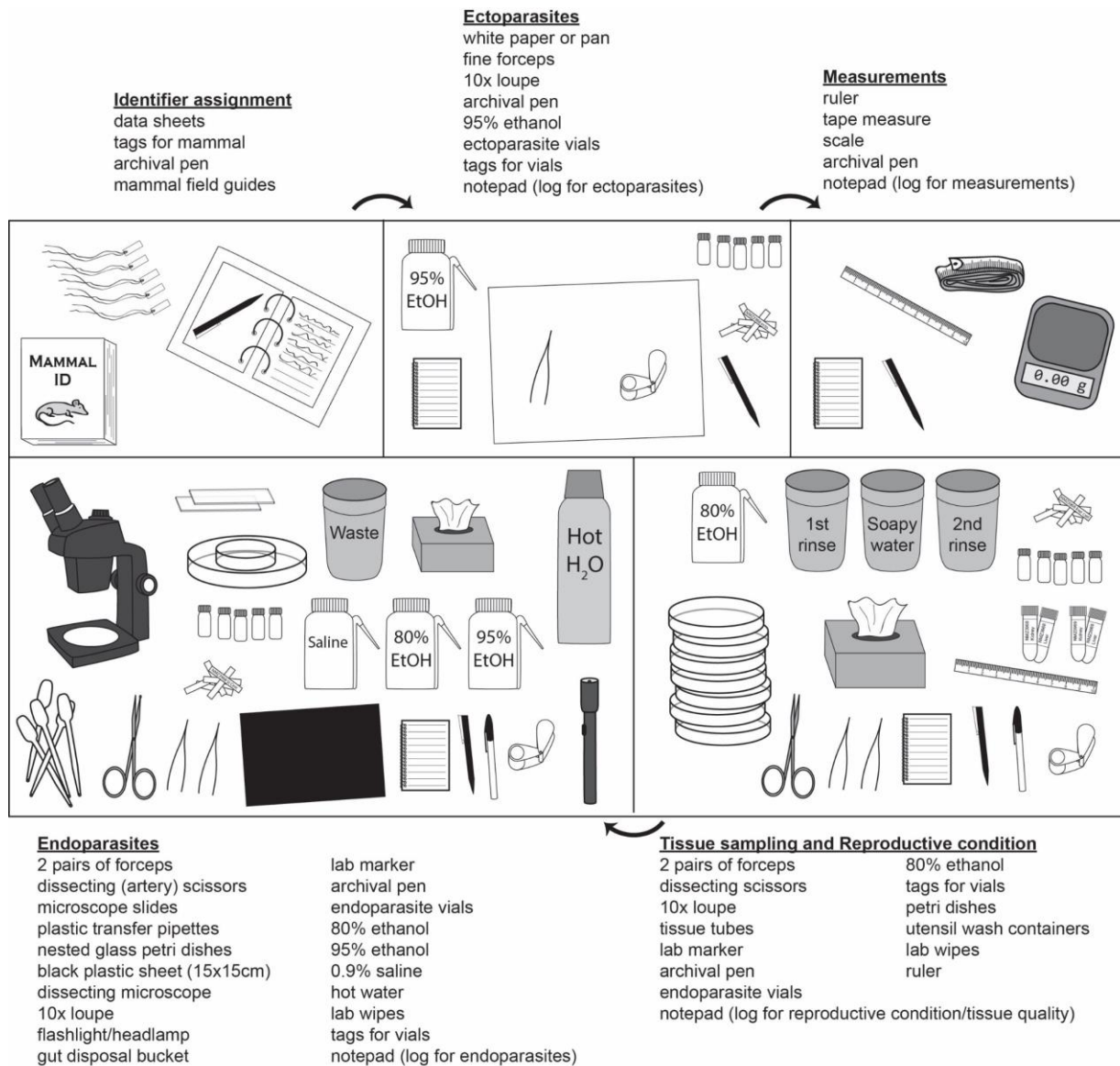


Fig. 1.—Schematic illustrating a typical “assembly line” set-up for a host-parasite field processing lab, along with required equipment for each prep station. Although we have found this model to be effective with a team of four persons, it is scalable to crews of different sizes. For example, in larger crews, multiple people can be assigned to endoparasite collecting or to other tasks including host study-skin preparation.

2. DATA TRACKING

Before initiating a program to survey mammals and their parasites, it is important to establish a clear procedure for tracking specimens and data. At minimum, host datasheets should include fields for tracking parasite material (Fig. 2), though it is also good practice to keep a separate parasite log for recording detailed notes describing which host organs were examined for parasites, the number, location, and condition of parasites found, the number of parasite vials collected, and other relevant observations. Every necropsied host should be recorded, even if no parasites were detected or preserved, to allow estimates of both parasite infection intensity and prevalence. If collected mammals are not necropsied, this should also be recorded.

Given that a major advantage of holistic sampling is the opportunity to investigate relationships between organisms, a single unique identifier (e.g., host voucher number/museum catalog number) should be used to directly link all parasite specimens back to the host. Likewise, relationships between materials derived from a single parasite should be maintained. For example, after specimens are retrieved from the field a portion of a tapeworm may be subsampled to provide tissues for molecular analyses, while the rest of the worm is stained and mounted for morphological examination. In this case, a unique identifier assigned to the individual parasite can be used to link products derived from a single organism.

Various labeling schemes can be used to track parasite specimens. One example is to use the host voucher number followed by a code to indicate type of parasite (e.g., T = trematode, N = nematode, C = cestode) followed by a digit to distinguish each vial from others from the same host. It is also helpful to note the parasite location (e.g., Stom. = stomach, SI = small intestine, LI = large intestine). For example, NMZ405T1 SI indicates that the vial contains trematodes from the small intestine of host number NMZ405. In this case additional trematodes from the large intestine would be labeled NMZ405T2 LI. Specimens that are later separated from one vial could be designated by a letter code (e.g., NMZ405T1A, NMZ405T1B,...). Labels should be written in archival permanent ink or pencil on heavy acid-free paper or cardstock and inserted inside parasite vials.

Though hand-written codes can be effective, they are prone to human error, especially when multiple individuals are recording data and writing labels. Permanent barcode stickers with unique codes provide an alternative method of tracking specimens that is less error prone. For example, barcode labels can be purchased in sets that provide two or more labels with the same code (Fig. 3). One label can be attached to a specimen vial and another matching label can be attached to a host datasheet, thereby efficiently linking the parasite to its host record while eliminating the potential for mistakes associated with poor penmanship or transcription error. Barcode labels should include both the barcode (1D or 2D as appropriate) and human-readable text to facilitate sorting without a scanner. Universal barcode scanners are readily available.

NMZ (= NMU:Mamm)2502

Collector: Kurt Galbreath DeathDate: 1 August 2018

Preparator: Kurt Galbreath PrepDate: 1 August 2018

Species: Ochotona princeps

Country/State: USA/ID Elevation: _____

District (e.g. island, county, Nat'l Park): Idaho Co.







Specific locality: 5 Km N, 2 Km E Salmon Mtn

Lat: 45.66092798 Long: -114.808835

Authority: GPS Datum: WGS 84 Max error: ±10m

Nature of voucher (circle one or more) skin skull skeleton

fluid preserved whole frozen tissues only other _____

Sample	Barcode	pres	Sample	Barcode	pres
H, K, Lu, Spl		<u>Fr</u>	ectoparasites		<u>E+O+H</u>
liver		<u>Fr</u>	nematode		<u>E+O+H</u>
kidney			cestode		
heart			trematode		
spleen			embryo		
muscle-adrenal		<u>formalin</u>	other: plasma		<u>Fr E</u>

Tissue condition (circle one): (poor) 1 2 3 4 5 (excellent)

Relationship: _____ of # _____

Sex: M F ? Repro condition: 2 PLSC (1R, 1L)

Measmts (total-tail-hindft-cfn=weight): 163-x-29-24 = 133g

Checked for ectos? Y N Type?: Fleas Ticks Lice Mites

Checked for endos? Y N Where?: stomach SI LI/caecum

Remarks: 2 Fleas, mites in ears
1 nematode in caecum

Field #: BL 377

Accn # _____

Fig. 2.—Example datasheet for mammal and parasite collecting. Barcode stickers cross-reference to barcode labels on parasite vials. Separate lines address whether specimens were screened for ectoparasites or endoparasites to permit meaningful calculations of prevalence for various parasites.




Fig. 3.—Example of “cap and wrap” barcode labels used to track parasite vials. Vials are labeled with the wrap and one cap sticker, while the remaining cap sticker is applied to the appropriate host datasheet (Fig. 2). Internal tags are still used to indicate the host voucher number and additional brief information (e.g., parasite taxon, location in host).

3. MAMMAL COLLECTING

The protocols described here would be most appropriately applied in studies involving lethal sampling of small to mid-sized mammals (<10 kg), but could be scaled to apply to necropsies of larger mammals. A discussion of methods for collecting mammals is far beyond the scope of this paper, but these have been reviewed elsewhere (Jones et al. 1996). Such methods vary by taxon of interest, research goals, and the requirements of institutional animal care and use committees and wildlife management agencies. Regardless of method of capture, specimen handling after euthanasia can significantly influence the quality of the parasitological material that is collected. A few key guidelines will help to maximize data and specimen quality:

- *Isolate mammal specimens* – All mammal specimens should be individually and immediately bagged at the point of collection (if using kill-traps) or following euthanasia to prevent ectoparasites from leaving the host or mixing between host organisms. Small zip-lock bags (e.g., Ziploc® or equivalent) are excellent for this purpose.
- *Keep mammals cool* – To maximize the window of time during which good quality parasite material can be collected, freshly collected specimens should be kept as cool as possible (without freezing) until they are necropsied. Holding specimens on ice and out of direct sunlight can dramatically improve the quality of parasite specimens preserved late in the necropsy process. Warm conditions lead to very rapid degradation of parasites and host tissues.

- *Necropsy mammals quickly* – Endoparasites and host tissues can degrade rapidly following death. Ideally all necropsies should be completed on specimens as quickly as possible (within a few hours of host collection). Smaller mammals (e.g., shrews, bats) should be necropsied before larger animals.
- *Freeze specimens only if necessary* – To get the best quality parasite material, mammals should be necropsied without first being frozen. In circumstances where mammal specimens cannot be necropsied immediately, they can be frozen. However, freezing has potential to damage morphological features of parasite specimens. If mammals are to be frozen, this should be done as soon as possible after capture and they should remain frozen until necropsy. Multiple freeze/thaw cycles will damage parasite morphology and degrade tissue quality.
- *Fluid-preserve whole hosts or gastrointestinal (GI) tracts only when immediate processing or freezing are not options* – While there are advantages to fluid preservation of whole organisms for some research applications, this should be considered a last resort for preservation of parasite material associated with un-necropsied host organisms. It is routine for multiple fluid-preserved specimens to be housed in a single container, leading to the potential for ectoparasites to be lost or transferred between hosts. Further, helminths in fluid-preserved hosts typically die in a contracted state, making morphological features impossible to discern. Ethanol preservation of GI tracts or whole specimens will retain some utility for genetic or metagenomic analyses (Greiman et al. 2018). An alternative compromise would be to remove and freeze the GI tract prior to ethanol preservation of the mammal. Use of formalin should be avoided unless specifically required for a targeted research application (e.g., histology) as formalin will degrade DNA. Long-term archival storage of ethanol-preserved materials must minimally use 70% ethanol to maintain tissue quality. Due to the high water content of unpreserved organisms, they should first be soaked in a large volume of 95% ethanol for >48 hours before being transferred to a solution of 70-80% ethanol. Ideally the holding solution should be refreshed again after several days. For whole-body preservation, it is critical to cut open the abdominal cavity (without rupturing the GI tract) and puncture the diaphragm to allow ethanol to penetrate and preserve the entire specimen quickly. In addition, during the initial ethanol soaks, the storage container should be gently agitated one or more times daily to mix ethanol as it dilutes from body fluids.

4. PARASITE COLLECTING

4.1. Overview.—We have provided a flowchart for parasite processing that illustrates the various stages of parasite retrieval, processing, and preservation (Fig. 4). This schematic in conjunction with the following descriptive methods provide a detailed account of the basic process of parasite collection, which will allow mammalogists to preserve high quality parasite material with maximal efficiency. It is not an exhaustive description of parasitological methods. In-depth explanations of additional techniques are described elsewhere (Pritchard and Cruze 1982; Lutz et al. 2017; Tkach et al. In Press).

4.2. Note on ethanol preservation.—The most convenient way to preserve parasites for diverse research purposes is to store them in vials of ethanol. Commonly parasitologists have used 70% ethanol for storing parasites, but some advocate the use of higher concentrations (Lutz

et al. 2017) under the expectation that this slows the degradation of DNA over time (see Section 6). Conversely, too high a concentration of ethanol can in some cases dehydrate specimens (especially helminths) to the point of distorting diagnostic morphological features. To date no study has comprehensively evaluated the relative effects of different concentrations of ethanol on different types of parasites for various downstream applications. That said, our experience suggests that the ethanol concentration of specimen holding fluid should never be below 70%, and higher concentrations are preferred. Helminths are best preserved in 80% ethanol, which balances concerns regarding DNA preservation against protecting morphology. Ectoparasites are best preserved in $\geq 95\%$ ethanol, as they are less likely to be damaged by dehydration. If a relatively large portion of a specimen vial's total volume will be filled by a parasite that itself is holding a considerable amount of water, this can result in a significant dilution factor. Use of denatured ethanol or isopropyl is not advised as this is rarely indicated on vials, and may interfere with genetic analyses. To ensure that ethanol concentration is maintained at an appropriate level for long-term storage follow these guidelines:

1. Always fill parasite vials completely with ethanol
2. Use a large enough vial to ensure that the parasites occupy no more than 25% of the total volume
3. For vials with especially large helminths, discard the ethanol and replace with fresh 80% ethanol after first 24 hours of preservation.

4.3. Ectoparasites.—Ectoparasites on mammals typically include parasitic flies, fleas, lice, ticks, and mites. Because many ectoparasites are capable of transmitting blood-borne pathogens, it is important to prevent them from escaping to potentially feed on members of the field crew! Further, many delicate morphological features of these small arthropods are diagnostic for species identification, and can be easily damaged by overly aggressive pinching with forceps in an effort to prevent them from fleeing.

To minimize both health risk and damage to parasites, mammal specimens should first be fumigated. Chemical inhalants commonly used for euthanasia of small mammals can also be used to kill or at least temporarily immobilize arthropods (Sikes et al. 2016; AVMA 2013). Chloroform is very effective, but concerns about toxicity to humans (AVMA 2013) suggest that it should only be used outdoors and with proper personal protective equipment. Isoflurane is less toxic, and can be acquired from veterinary suppliers, but it is less likely to kill ectoparasites. In our experience, isoflurane rapidly anaesthetizes insects, including fleas and lice, but ticks and mites are more resistant. Ethyl acetate offers another option that has been recommended for fumigating specimens that are euthanized by other means (Lutz et al. 2017). With care, a small syringe with hypodermic needle of appropriate gauge (e.g., 18 to 25 G) can be used to inject a small amount (0.5 ml) of chemical inhalant directly through the wall of a sealed plastic bag holding a mammal specimen. The rate at which ectoparasites succumb is influenced by temperature, which regulates how quickly the chemical vaporizes and fills the available volume of the bag. Vaporization can be encouraged by setting each treated specimen (i.e., plastic bag) in the sun for a few seconds, but prolonged heat should be avoided as it rapidly degrades parasites and tissues, particularly for shrews and their parasites.

Specimen bags should be opened only when they are ready to be swept for ectoparasites, and in a well-ventilated area. After removing the mammal, closely inspect the bag for ectoparasites that may have detached from the host. These can be gently swept out and into a full vial of 95% ethanol (see Section 6 for suggestions regarding vial selection) using forceps or a small brush dipped in ethanol. If the bag holds many ectoparasites, they can be washed into a corner of the bag using ethanol and transferred to a vial either using a transfer pipette or by cutting the corner of the bag to form a funnel over the vial.

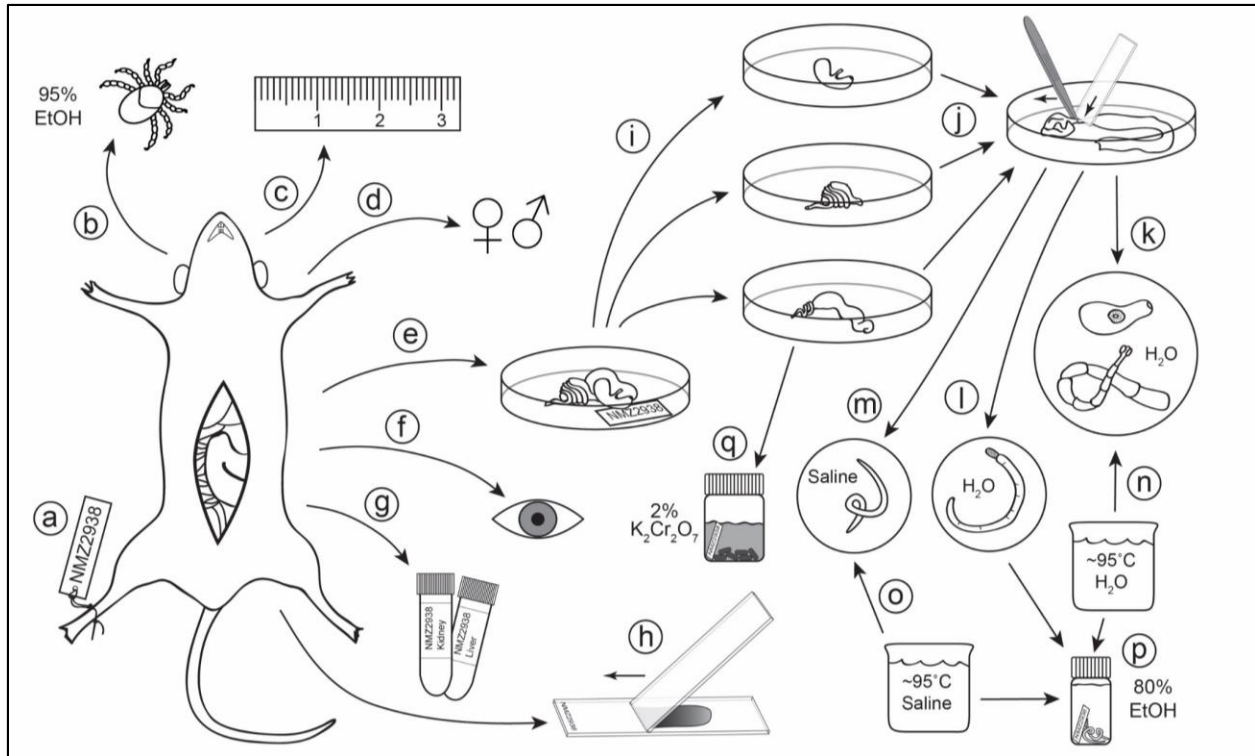


Fig. 4.— Flowchart for small mammal necropsy. A unique identifier is assigned to the mammal immediately upon capture (a); the mammal is swept for ectoparasites (b); standard mammal measurements are recorded (c); reproductive data are recorded (d); the gastrointestinal (GI) tract is transferred to a Petri dish and labeled (e); the body cavity and organs (e.g., liver) are visibly inspected for parasites (e.g., encysted metacestodes, nematodes, sarcosysts) (f); host tissues are collected and preserved (g); thin blood smears can be prepared from freshly euthanized hosts to sample blood borne pathogens (h); major sections of the GI tract are separated (stomach, small intestine, large intestine), straightened, and individually opened lengthwise (i); the lining is scraped by pulling it beneath the end of a microscope slide using forceps, and washed with saline to reveal helminths (j); after transfer of helminths to a new dish, trematodes and cestodes are washed in saline or water (k), acanthocephalans are soaked in water until the proboscis extends and the worm dies (l), and nematodes are washed in saline (m); trematodes and cestodes are simultaneously relaxed and killed by swirling in hot water (n); nematodes are killed using hot saline (o); helminths are preserved in ethanol (p); fecal pellets are collected from the colon and stored in potassium dichromate solution to sample coccidians (q).

Small mammals should be swept for ectoparasites by holding the animal by the tail or hind legs with the head hanging down toward a white sheet of paper or a white pan. Vigorously combing the fur toward the head using the side of a pair of forceps, a fine-tooth comb, or a brush will dislodge dead fleas, lice, adult mites, parasitic flies, and other unattached parasites. With comb or brush, care should be taken to ensure that no parasites are caught in the brush teeth or bristles and transferred to another mammal specimen. The body should be rotated so that all sides are swept, particularly around legs, base of the tail, chin, nape, and ears. As parasites fall, use forceps or a small brush dipped in ethanol to sweep them off the paper or pan and into the vial of 95% ethanol. Pinching the parasites with forceps can damage them, so this should be avoided if possible. Use of a 10X loupe, magnifying glass, or dissecting microscope can aid in identifying mites or lice (fleas and ticks are generally large enough to see clearly with the naked eye). Lice, for example, are easy to miss because they are miniscule and often light colored, resembling flakes of dead skin. They can be abundant when present (multiple objects of similar size, shape, and color generally deserve closer inspection), and generally have a red or brown color in their gut. Nits may also be visible attached to hairs.

Once all parasites that are removed easily by sweeping are collected, the mammal's body should be visually re-inspected. Ectoparasites can be found anywhere on a mammal's body, but locations that deserve particular attention include the head (especially on and inside the ears and under the chin), under the legs, around the anus and groin, and on the tail. Embedded ticks or larval mites may look like scales and can be extremely small (< 1 mm in diameter). Reddish colonies of tiny mites are commonly found in ears or groin areas of rodents. They will probably not be dislodged by sweeping and may require more effort to remove. To ensure that delicate features of the feeding apparatus that are critical to species identification (e.g., palps, hypostome) are not damaged, a fine pair of forceps can be used to grasp the skin immediately beneath the parasite's mouthparts, which can generally be pulled away from the host with the parasite still embedded. The skin can be dissected away later under a stereo microscope. Grasping the body of an embedded mite or tick to remove it will often result in critical structures being left behind in the integument of the host, or in other distortion or damage to the body.

Ensure that all utensils (e.g., combs, brushes) and the work surface are wiped clean before sweeping another specimen. If using white paper as the work surface, it can be replaced between animals to minimize the potential for carry-over of ectoparasites between specimens. We have effectively used plasticized paper taped to the table that may be wiped between specimens.

4.4. Endoparasites.—The endoparasitic worms (helminths) of mammals typically include nematodes (roundworms), cestodes (tapeworms), trematodes (flukes), and acanthocephalans (spiny-headed worms). As noted above, most helminths degrade rapidly upon the death of the host, so necropsies will ideally be conducted as soon as possible after capture and specimens should be kept as cool as possible while they await necropsy. Shrews, in particular, harbor a diverse helminth fauna that disintegrates very quickly after the host dies, and they should be necropsied first. If quality parasite material from soricids is the goal, traps (e.g., pitfalls) should be checked every few hours to ensure that the animals are processed immediately after they are euthanized. For small rodents and lagomorphs, specimens will ideally be necropsied within 3 hours of death (the sooner the better). As a rule of thumb, the length of time during which good

quality parasite material can be collected from a mammal correlates with host and parasite body size, so it is wise to start necropsies with small-bodied species followed by larger mammals. The time taken to complete a necropsy also is correlated with body size, so this approach permits more specimens to be processed before helminths have become heavily degraded. An exception to this policy is that adult individuals of a given species are more likely to harbor parasites than are juvenile individuals, so it may be desirable, in the interests of collecting the best representation of parasite diversity possible, to prioritize adult individuals in the processing line. If high numbers of captured specimens prevent timely completion of full necropsies, then immediately selecting a subsample of high-quality adult individuals for whole-body fluid preservation in 95% ethanol (see Section 3) before processing commences offers a way to process more specimens rapidly. This helps to avoid extensive degradation of specimens processed late in the day.

4.4.1. General Necropsy Protocol for Small Mammals.— To maximize the value of a given mammal specimen as a resource for research, standard body measurements, sex, and reproductive condition should be recorded once ectoparasites are collected. It is also desirable to collect tissues for future molecular analyses (e.g., spleen, kidney, heart, lung, liver, muscle). Tissue collection requires a mid-ventral incision through the abdominal muscle layer, which provides access to the internal organs where the majority of endoparasitic helminths are likely to be found.

- 1) If blood smears are to be collected, this should be done immediately upon the death of the mammal (see Section 4.8).
- 2) As soon as the animal is opened, the process of checking it for endoparasites begins with an inspection of the body cavity and outer surface of the internal organs.
 - a) Encysted nematodes may appear as white or beige disks or capsules within the body cavity or under the skin. Adult filaroid nematodes may occur in the body or thoracic cavity. Depending on the species they may be adhered to the mesenteric tissue or embedded. These can be placed in saline, heat killed (see Section 5), and preserved whole in 80% ethanol.
 - b) Larval cestodes (metacestodes) are generally bright white and easily visible to the naked eye, but they are wrinkled and formless. They may be loose in the body cavity or embedded within tissues (commonly the liver where they appear as embedded white spheres). These can be removed and preserved whole in 80% ethanol. Embedded metacestodes can be fully dissected out of the host tissue if desired, but it is also acceptable to preserve them while they are still embedded in a block of host tissue.
 - c) Digenean flukes (trematodes) also occupy the liver, where they can sometimes be detected by dark trails of damaged tissue left behind as they feed and migrate. Flukes can be dissected out of the liver using pairs of forceps to tear the tissue apart until the flukes are free. Use of a dissecting microscope is helpful. Adult flukes must be heat-killed and relaxed before they are preserved (see Section 5).
 - d) Nematodes and trematodes can occupy the lungs, where they may form hard nodules that can be felt between the fingers when pinched. Flukes can be freed using pairs of forceps to shred the lung tissue prior to relaxation and preservation. In contrast, pulmonary

nematodes commonly form highly convoluted and tangled balls that make it difficult to dissect them out of the tissue matrix. Cut the nodule away from the rest of the lung and place it in physiological saline. Living nematodes may partially disentangle themselves over time. Prior to preservation they should be heat-killed (see Section 5).

- e) Any organs that appear to harbor parasites should be excised and placed into the Petri dish with host identifier to which the GI tract will be transferred. This should be accomplished before sampling host tissues for archive.
- 3) Two tasks that should be completed before removal of the GI tract include inspection of the mammal's reproductive organs to record reproductive condition, and collection of the spleen (if these are part of the routine mammal processing protocol). Removal of the GI tract can damage reproductive organs or make them difficult to interpret, and the spleen is attached to the greater curvature of the stomach and is normally removed with the gut if it is left in place.
- 4) The GI tract should be removed between the liver and the anus (including the stomach, small intestine, and large intestine) and placed in a Petri dish with a tag indicating the host identifier (e.g., voucher number). To remove the GI tract, hold the animal vertically (head facing up) in one hand over the Petri dish. With the other hand, use a pair of forceps to slide between the liver and stomach to grasp the esophagus where it meets the middle of the lesser curvature of the stomach. Tug downward to break the esophagus and pull the stomach toward the dish. Reposition the forceps to pinch and pull the tough hepatoduodenal ligament, which connects the liver to the anterior end of the small intestine. Reposition the forceps as necessary to pinch and break any remaining ligaments holding the gut in place without pinching the gut tube itself. The entire GI tract should, with limited additional effort, slide out of the peritoneal cavity into the Petri dish. Pinch and break the rectum to complete its removal. Avoid grasping the major organs of the GI tract directly with forceps, as this can damage helminths that lie inside. For larger specimens it may be necessary to use scissors to cut either end of the GI tract.
- 5) The urinary bladder may contain parasites, particularly nematodes. Using forceps, remove the urinary bladder by pinching and breaking the urethra as close to the pelvis as possible. Place the bladder in the Petri dish with the GI tract, ensure that the dish is labeled, and cover it until it is to be dissected.
- 6) If desired, at this point in the necropsy samples can be collected to screen for *Trichinella*, a diverse genus of microscopic nematodes that parasitizes many different mammal taxa, including various rodents, insectivores, and carnivores. Larval *Trichinella* establish in host muscle cells, especially in the diaphragm and tongue, which can be removed and preserved in 80% ethanol or frozen for further histological examination.
- 7) The carcass is now available for further processing (e.g., tissue pulling, skinning), while the GI tract is ready to dissect.
- 8) Separate the stomach, small intestine, and large intestine (including the colon and caecum) into three sections. These will be dissected separately in a clean dish as different species of parasites will be associated with different regions of the digestive tract. Use a sheet of black plastic or vinyl as a work surface for the Petri dish as many parasites are white or clear and can be more visible against a dark background.

4.4.2 Dissecting the Small Intestine.—The small intestine supports a potentially broad diversity of helminths and time should be taken through the following steps. Many rodent parasites will be visible with the naked eye but for shrews, moles, and bats, parasites may be tiny, and an alternate procedure for these groups is provided (section 4.5; Tkach et al, In Press).

- 1) The GI tract is highly convoluted and held in place by an extensive network of mesenteries that must be broken to allow the organs to lie straight. This is most easily accomplished using two sets of narrow forceps. Hold the mesentery where it contacts the gut wall with one set (again, do not pinch the organ itself to avoid crushing helminths that might be inside) and strip mesenteries away with the other set.
 - a) Blood-feeding flukes can occur in the mesenteric blood vessels. These can be detected by stretching the mesenteries and carefully cutting open the arteries and veins. Flukes can often be visualized by back-lighting the stretched tissue.
- 2) Once straightened, open the intestine lengthwise, starting at the posterior end using a pair of artery scissors (with a ball on the tip of the blade that is inserted into the gut lumen) or scissors in which at least one blade is rounded. Dissecting scissors in which both blades are pointed will also work, but may more easily puncture the gut wall. Keep the tip of the blade that is inside the lumen of the intestine close to the lining to minimize the chance of accidentally cutting worms. Use forceps to pull the intestine back against the blades. Use sharp, high quality blades that allow the tissue to be sliced with minimal scissoring motion.
 - a) Use of either a dissecting microscope or magnifying visor while cutting will make it easier to see small parasites to avoid accidentally cutting them.
- 3) As the small intestine is opened, be vigilant for parasites to avoid cutting them. Occasionally it may be helpful to rinse the intestinal contents with saline using a wash bottle.
- 4) Use a microscope slide to scrape the mucosal lining off of the intestinal wall. Do this by pressing the flat edge of the end of the slide against one end of the opened gut with the mucosa facing up. The slide edge should be flat against the floor of the Petri dish. Holding the slide in place at a roughly 60° angle from horizontal, use forceps to pull the intestinal wall through the small gap between the slide edge and the bottom of the dish, which will scrape the mucosal lining off against the sharp slide edge. Be careful to maintain firm pressure on the slide to ensure that the mucosal lining is scraped off. Discard the muscle tissue of the gut wall and vigorously rinse the mucosa with saline and agitate with forceps.
- 5) It is common for there to be abundant murk and debris in gut contents, which obscures the view of parasites. This can be reduced by washing thoroughly with saline, allowing parasites to settle (all helminths are negatively buoyant in saline), and then decanting excess saline and debris off the edge of the Petri dish into a waste container. Washing with saline and decanting can be repeated until the liquid in the dish clears. For GI tracts that have an especially large volume of waste material, the process of clearing gut contents can be hastened by depositing the scraped intestinal contents directly into a large cup, filling it with saline, stirring, and allowing it to rest for at least 30 seconds. Decant the large volume of murky liquid into a waste container until the material that settled to the bottom of the cup is all that remains. Addition of fresh saline and repeating the decanting step may be necessary. Once cleared, the material that settled to the bottom of the cup can be inspected for helminths in a Petri dish.

- 6) Parasites that are likely to be detected in the small intestine include:
 - a) Nematodes – Roundworms are distinguishable by their smooth tapered bodies. They can be large and robust, small and tightly coiled, or thread-like and tangled. They can have no color (clear) or be white or red. In the small intestine they are often found at the extreme anterior end, and can be too small to distinguish with the naked eye.
 - b) Cestodes – Tapeworms are flattened and clearly segmented with a distinct scolex with four suckers usually visible (in the cyclophyllidean cestodes that are commonly associated with mammals). The scolex, which is typically attached to a narrow neck, can be large and broad or so small that it requires magnification to see. It often has important features for taxonomic identification, so care should be taken to check that the scolex has been obtained, along with the strobila. Tapeworms range in size from a few millimeters to several centimeters in small mammals. Some tapeworms of large mammals can grow to several meters in length.
 - c) Trematodes – Flukes may resemble small pink or white beans a few millimeters in length. Others may more closely resemble grains of sand or salt and pepper. Close inspection under magnification may be necessary to confirm their presence. Watch for movement or changing shape. The largest species achieve a few centimeters in length. Their oral and ventral suckers are visible under magnification.
 - d) Acanthocephalans – Spiny-headed worms may superficially appear to be segmented like a tapeworm, but they are not flattened and they lack a distinct scolex with suckers. The spine-covered rostrum is diagnostic, and used as a holdfast that embeds into the gut wall. The rostrum may be retracted. They are generally one to several centimeters in length.
- 7) A dissecting scope or magnifying glass may be necessary for the smallest worms. A bright flashlight or headlamp is particularly useful in the field to illuminate the Petri dish from multiple angles (above, below, and lateral), which can enhance the visibility of parasites.
- 8) Larger parasites should be lifted (never pinched) gently using forceps into a fresh dish with clean saline. Smaller parasites can be efficiently and safely moved using a fresh transfer pipette with the tip cut off to create a pipette mouth of appropriate diameter. Pipettes should either be replaced or thoroughly cleaned between host samples.
- 9) Petri dishes with collected worms should be labeled immediately using the label that will ultimately reside inside the parasite specimen vial. The label should be written on archival cotton rag paper or cardstock using ethanol-fast permanent ink and should minimally include the host animal's unique identifier written on front and back and the parasite's location (e.g., SI for small intestine).
- 10) If possible, record where in the small intestine the helminths were found (anterior, middle, posterior), as different species specialize on different regions of the gut.
- 11) After transferring parasites into clean saline, rinse the remaining gut contents into a waste container and wipe the dish out prior to the next dissection to ensure that no parasites are accidentally transferred between organs or hosts.

4.4.3. Dissecting the Stomach.—

- 1) Using artery scissors, cut through the wall of the stomach from end to end to open it as described above. Though the stomach may contain a large mass of digesting food, parasites generally stay close to the mucosal lining. Carefully peeling the stomach wall away from the food bolus (if present) will allow the majority of worms present to be collected.
- 2) Once all obvious worms are collected, scrape the stomach lining as described above and wash with saline.
- 3) Finally, break up and wash the food bolus to confirm that no parasites are present.
- 4) Transfer parasites to clean saline.
- 5) Discard waste and clean the Petri dish.

4.4.4. Dissecting the Large Intestine (Caecum and Colon).—

- 1) As with the small intestine, mesenteries must be stripped to straighten the large intestine.
- 2) The portion of the colon that is filled with compact fecal pellets generally does not harbor helminths. However, fecal pellets provide a good resource for sampling the intestinal flora and their preservation may be of interest.
 - a) To sample coccidians (single-celled protozoans), roughly one gram of feces can be collected in a 15 to 25 ml vial (screw-top scintillation vials or Falcon tubes work well). The vial should be filled halfway with 2% aqueous potassium dichromate solution. Retaining air in the vial is important to provide oxygen necessary to keep oocysts viable and to allow them to sporulate. Sporulation is critical for species identification. However, specimens must be examined soon after returning from the field to the lab, so there is little purpose in collecting samples for coccidia unless the investigator is in a position to work on them soon after collection.
 - b) Another approach to sampling cysts formed by gut protozoans (e.g., *Giardia* spp., *Entamoeba* spp., coccidians) is to preserve several fecal pellets by either drying in sterile silica gel or by freezing. These specimens can be screened for protozoan diversity using fecal flotation, though species-level identification of cysts is not always possible. Metagenomic tools can also be applied to these samples to investigate both protozoan and bacterial diversity.
- 3) The remainder of the colon and caecum should be opened lengthwise and scraped.
- 4) There is typically quite a bit of digesting material in the caecum, in which case it is necessary to wash with saline, settle, and decant, often multiple times. Use forceps to break up lumps of material with each wash prior to decanting. Once the liquid is clear, inspect settled debris for helminths.
- 5) In the large intestine it is common to find small (few mm) to large (few cm) yellow or white nematodes, occasionally trematodes, and rarely small cestodes. Place these in fresh saline.

4.4.5. Finishing Steps.—

- 1) Open, scrape, and wash the urinary bladder. Nematodes are often detected here.
- 2) Waste liquid from necropsies can be disposed of in the field by burying it in a deep hole or dumping in a latrine.
- 3) Tools should be thoroughly cleaned and wiped off between necropsies. Avoid using bleach solution to clean tools. Residual bleach from cleaned tools can be transferred to specimens and can steadily degrade DNA during long-term storage. Instead, use a weak soap solution with fresh water rinse. An effective strategy is to use a series of three containers (e.g., 0.5L plastic cups) to provide 1) an initial water rinse to remove blood and pieces of tissue, 2) a soap wash, and 3) a clean water rinse, but it is critical to visually inspect tools after cleaning to ensure that all tissue is completely removed before working on another specimen. Wiping tools with a clean piece of Kimwipe® or similar (toilet paper is a cheap and effective alternative) helps to guarantee that they are clean. Containers should be dumped and refreshed periodically during a day of processing.
- 4) Once all detected parasites have been collected and rinsed in saline, proceed to helminth preservation methods (see Section 5).

4.5. *Necropsy protocol for shrews.*—Shrews harbor a diverse array of helminths in their GI tracts. In the smallest shrews (e.g., *Sorex* sp.) these parasites can be very abundant, yet also very small. Due to their small size, these parasites are easily damaged by forceps, and many will be missed in the absence of a dissecting scope. Thus, they can be difficult and tedious to isolate using the standard small mammal necropsy protocol. Further, they degrade rapidly following their host's death, so swift preservation is essential. Though large shrews (e.g. *Blarina* sp.) may be processed using the standard protocol, a different protocol for use with smaller shrew species has proven to be effective in efficiently acquiring high quality parasite material from freshly caught specimens (Tkach et al. In Press). The following is a brief overview of this method:

- 1) After the shrew has been opened via a mid-line incision down the belly, reproductive data recorded, and spleen collected, remove the digestive tract between the liver and the anus (this includes the stomach, small intestine, and large intestine) and place it in a Petri dish with a tag indicating the mammal's unique identifier and wetted with a small amount of saline.
- 2) Straighten the entire digestive tract by gently stretching with two sets of forceps, and then open it from end to end with artery or blunt-tip scissors. Use a microscope slide and forceps to scrape the mucosal lining to ensure that all worms are removed. Discard the gut wall.
- 3) To kill and relax any worms that are present, pour a few milliliters of near-boiling water over the gut matrix. Alternatively, near-boiling saline can be used. It is possible to boil a large volume of water or saline in advance and keep it in a small vacuum-sealed thermos for use throughout the prepping period, saving time and fuel (see Section 5).
- 4) Add room temperature saline immediately to cool worms, and then use a transfer pipette with the narrow tip cut off to move all gut contents to a 7-20 ml vial (2-5 dram). If there

is more liquid to transfer than the vial will accept, let the matrix settle in the vial and then use the pipette to remove excess fluid. After transferring everything into the vial, let the matrix settle and then remove excess liquid until the vial is roughly 20% full.

- 5) Fill the vial to the top with 95% ethanol, cap, and invert to mix. This will produce an ethanol concentration of approximately 75-80%.
- 6) Label the vial with an internal tag written in archival ink.

4.6. *Parasite collection during mammal skinning.*—After tissues and the GI tract have been removed and the body cavity inspected for parasites, the mammal carcass is ready to be skinned prior to making skin and skeleton preparations. As the skin is removed, preparators should watch for parasites that occupy subcutaneous tissues. For example, larvae of certain nematode species (e.g., *Porrocaecum encapsulatum*) may encyst in smooth capsules beneath the skin. Adult nematodes of the family Dracunculidae (e.g., *Dracunculus insignis*) may be detectable as visible tracks in the subcutaneous tissues. Nematodes should be heat-killed as described in Section 5 and preserved in 80% ethanol. Larval botflies developing within subcutaneous pouches are usually easy to detect given their large size and the presence of a spiracle through the skin. These can be preserved in 95% ethanol. Coccidians of the family Sarcocystidae form elongated white sarcocysts resembling rice grains within muscle tissue. Sections of muscle containing sarcocysts can be excised and preserved in 80% ethanol.

4.7. *Sampling tissue-dwelling nematodes of ungulates.*—Ungulates harbor a diverse array of nematodes that dwell in various tissues of the body, including the lungs, meninges, and muscle. In North America, potential hosts include cervids (e.g., *Odocoileus virginianus*, *Rangifer tarandus*, *Alces alces*) and bovids (e.g., *Ovis dalli*, *Ovibos moschatus*, *Oreamnos americanus*). Recent studies on these nematodes, which fall within the family Protostrongylidae, indicate that climate change is influencing their abundance, geographic distributions, and potential to cause disease (Jenkins et al. 2006; Kutz et al. 2013). Though opportunities to complete full necropsies on ungulates are generally limited relative to smaller more abundant mammals, the life cycle of protostrongylid parasites allows representative specimens to be acquired efficiently in the form of first-stage larvae collected from fresh feces. Larval protostrongylids cannot be identified to species using morphological criteria, but DNA can be extracted from individual larvae and diagnostic genetic markers can be sequenced to confirm species identity (e.g., Jenkins et al. 2005; Kutz et al. 2007; Verocai et al. 2014). Larval protostrongylids can be obtained from feces using the following modified beaker-Baermann protocol (Fig. 5; Forrester and Lankester 1997).

- 1) Collect fecal pellets that are as fresh as possible, ideally less than one day old. Fresh pellets will generally have a shiny mucus coat. If possible, observe animals from a distance and make note of when/where they defecate so that fresh samples can be collected. Winter represents an excellent time to collect fecal samples, as hosts can be easily tracked in snow, pellets stand out against the snow, and freezing temperatures keep samples fresh without harming the parasites. Keep fecal pellets from individual animals in separate plastic bags that are labeled internally with at least sample ID, date, location, and host identity.

- 2) Process fresh fecal samples immediately, or keep them frozen at -20°C until they can be processed. First-stage larvae of many species of protostrongylids can survive freezing temperatures for at least several months, and potentially years.
- 3) When ready to isolate larvae, begin by laying down a clean single-ply square (~15 cm on a side) of either cheese cloth or paper towel on a flat work surface.
- 4) Place ~20 fecal pellets in the center of the square and pull the corners of the square up to meet at the top. If there are too many pellets to allow the corners to come together, remove some pellets. This will form a “tea bag” of fecal pellets. If you have string available, tie off the top of the bag; otherwise twist the bag closed.
 - a) Some suggest crushing fecal pellets before placing them in the “tea bag” in order to make it easier for larvae to be released. While not a critical step if infection intensities and prevalence are high, it may be worth experimenting with this approach if few larvae are recovered when pellets are not crushed.
- 5) Place the pouch of feces into a clean quart Ziploc[®]-style plastic bag (labeled with sample ID) with just enough clean water to cover the pellets. Seal the plastic bag and arrange a place for it to rest undisturbed for 12 to 24 hours. A good strategy is to use binder clips to suspend the plastic bag from a sturdy cord strung between tree branches or inside a lab tent. With care, the fecal pouch can also be held off the bottom of the plastic bag by the same clip, allowing larvae to fall away from the pouch to the bottom of the plastic bag.
 - a) Live protostrongylid larvae become active in water and will leave the fecal pellets and work their way through the fibers of the pouch.
- 6) After 12 to 24 hours, carefully remove the pouch and discard it. Leave the water in the plastic bag (this has the larvae) and clip it back up, this time at an angle so that debris in the water settles into a single corner. Leave the sample undisturbed for at least one hour.
- 7) After the sample settles, use a plastic transfer pipette to carefully transfer sediment from the lowest corner of the plastic bag to a Petri dish. Remember to squeeze the bulb to eject air from the pipette before you insert the tip into the water. Squeezing the bulb after the tip is in the water will create a stream of air bubbles that will agitate the sample, which will then need to settle again.
- 8) Inspect the collected sample under high magnification against a dark background (e.g., black sheet of plastic). Larval protostrongylids are very small (~400 μm) and easy to miss if not magnified. Look for small, clear, laterally thrashing nematodes.
- 9) Larvae should be transferred to a labeled cryotube for preservation (freezing) using a transfer pipette. Do not be concerned with trying to collect individual larvae except in cases of low infection intensity. Simply use the transfer pipette to wash as many larvae as possible to one edge of the Petri dish (lift one edge of the dish and rinse to the opposite side), then transfer as much of the collected sample as possible to a cryotube.
 - a) Though not ideal, an alternative to freezing larval samples is ethanol preservation. Transfer larvae to a vial as described above and then let the vial settle for at least 20 minutes. After complete settling, carefully pipette off water from the top (do not disturb the sediment) until the vial is only 20% filled. Fill the vial to the top with 95% ethanol to

approximate a final ethanol concentration of 75%. If possible, store the vial at -20°C or colder after returning from the field.

4.8. *Sampling for viruses, bacteria, or protozoans.*—Investigators who are interested in screening mammal specimens for parasites that cannot be easily detected by gross morphological examination can make use of various sampling techniques to target specific organisms.

- *Blood smears* – Slide preparations of freshly collected blood allows screening for intraerythrocytic parasites (e.g., *Babesia microti*, *Plasmodium* spp., and *Theileria* spp.) and exoerythrocytic parasites (e.g., filaroid nematodes, including heartworm and other vector-borne nematodes). Thin blood smears are prepared by collecting a sample of blood from a freshly euthanized mammal using a capillary tube or Pasteur pipette. Blood from the peripheral circulatory system should be used whenever possible, but blood taken from the thoracic aorta or the ventral descending aorta will also work. The tip of the tube or pipette should be gently tapped onto one end of a microscope slide held stationary and horizontal on the work surface. This will transfer a droplet of blood (ideally ~5 µL) to the slide. Immediately, the end of a second slide should be set flat against the horizontal slide, angled over the blood droplet at roughly 30° from vertical. This second slide should be slid into momentary contact with the droplet before being slid, in a swift and smooth motion, in the opposite direction along the length of the first slide. The moving upright slide will draw a thin smear of blood along the horizontal slide. If done properly, the blood will be pulled along the horizontal slide via surface tension, not pushed along it via the upright slide. The mammal voucher number should be etched into the slide using an engraving tool, and the slide should be air-dried and then fixed by dipping in 100% methanol for one minute and then air-drying. It is good practice to prepare two blood smears per specimen (e.g., one slide serves as the spreader for the other, and vice versa). Store the slides in a slide box and keep the box in a cool and dry place. Condensation can destroy blood smears, so take particular care when moving slides from cool to warm and humid conditions.
- *Nobuto blood filter strips* – Blood serum absorbed into paper strips provides a convenient means for preserving antibodies associated with exposure to numerous viral, bacterial and protozoan pathogens (Nobuto 1963; Dusek et al. 2011). Pathogen detection is completed in the laboratory using ELISA methods. Nobuto strips typically have a broad end for labeling and a narrow end for sampling. To sample blood in the field from a specimen that is being necropsied, it is typically easiest to dip the narrow end of the strip into the thoracic cavity, where blood commonly pools. Allow the full length of the sampling portion of the strip to saturate with blood serum and then prop the strip up to dry or string it onto a wire in such a way that it does not come into contact with other samples. Once completely dry, it should be placed into a small labeled vial for transport.
- *FTA® paper* – FTA® paper offers another method of collecting blood samples that can be stored at room temperature for extended periods of time and used to screen for blood-borne pathogens. Blood is simply blotted onto a piece of FTA® paper, fully dried, and stored in an envelope.
- *RNAlater®* – To facilitate detection of many viral pathogens it is necessary to preserve RNA, which can be challenging in the field if a means of flash-freezing samples immediately (e.g., liquid nitrogen) is unavailable. RNAlater® solution stabilizes RNA in tissues, allowing it to

be maintained for longer periods at warmer temperatures than is the case for tissues preserved using other methods. Tissues to be preserved using RNAlater[®] should be taken only from freshly euthanized mammals and cut into small pieces (<5mm) to facilitate penetration by the solution. The ratio of mammal tissue to RNAlater[®] solution should be at minimum 1:5 by volume, and samples should be left cool, but unfrozen, overnight before freezing for long-term storage. The choice of tissues to preserve in this manner will depend upon the virus that is of interest. For example, some hantaviruses commonly are detected in lung tissue, whereas liver or spleen tissue provide good targets for other viruses.

- *Gut microbiome sampling* – Increasing interest in the microbial communities that live inside the GI tract of animals offers a unique opportunity for field biologists to enhance the impact of their sampling by preserving gut contents (Hird 2017). Freshly captured mammals that are processed immediately following euthanasia are the ideal target for this sampling, as microbial communities can change rapidly after the death of the host organism. Using sterile tools, gut contents can be squeezed or scraped directly into a labeled vial, ideally from a consistently sampled selection of gut regions (e.g., stomach, middle of small intestine, middle of caecum, middle of large intestine, appendix). Samples should be frozen or held in $\geq 95\%$ ethanol. To ensure comparability of samples, do not switch between preservation methods during field collecting. Alternatively, whole guts, or unopened sections of gut may be frozen or preserved in ethanol to maintain isolation and prevent contamination of the gut contents. Small shrew GI tracts may be preserved in this manner within a 15ml tube. For rodents, a couple fecal pellets within the posterior inch of the GI tract may be easily and consistently preserved in vials of 95% ethanol.
- *Longmire's solution* – Though not explicitly associated with preservation of parasites, this inexpensive solution is worthy of mention because it allows room temperature preservation of DNA for long periods of time (months; Longmire et al. 1997). Unlike other methods of preserving field-collected tissues (e.g., ethanol, liquid nitrogen) it is not considered to represent a risk by airlines and freight companies, offering a means of transporting specimens when other options are not available. A small tissue sample ($\sim 5 \text{ mm}^3$) should be placed in 1 to 2 ml of solution in a tightly sealed vial. This solution destroys proteins, so it is not effective for preserving specimens destined for morphological examination.

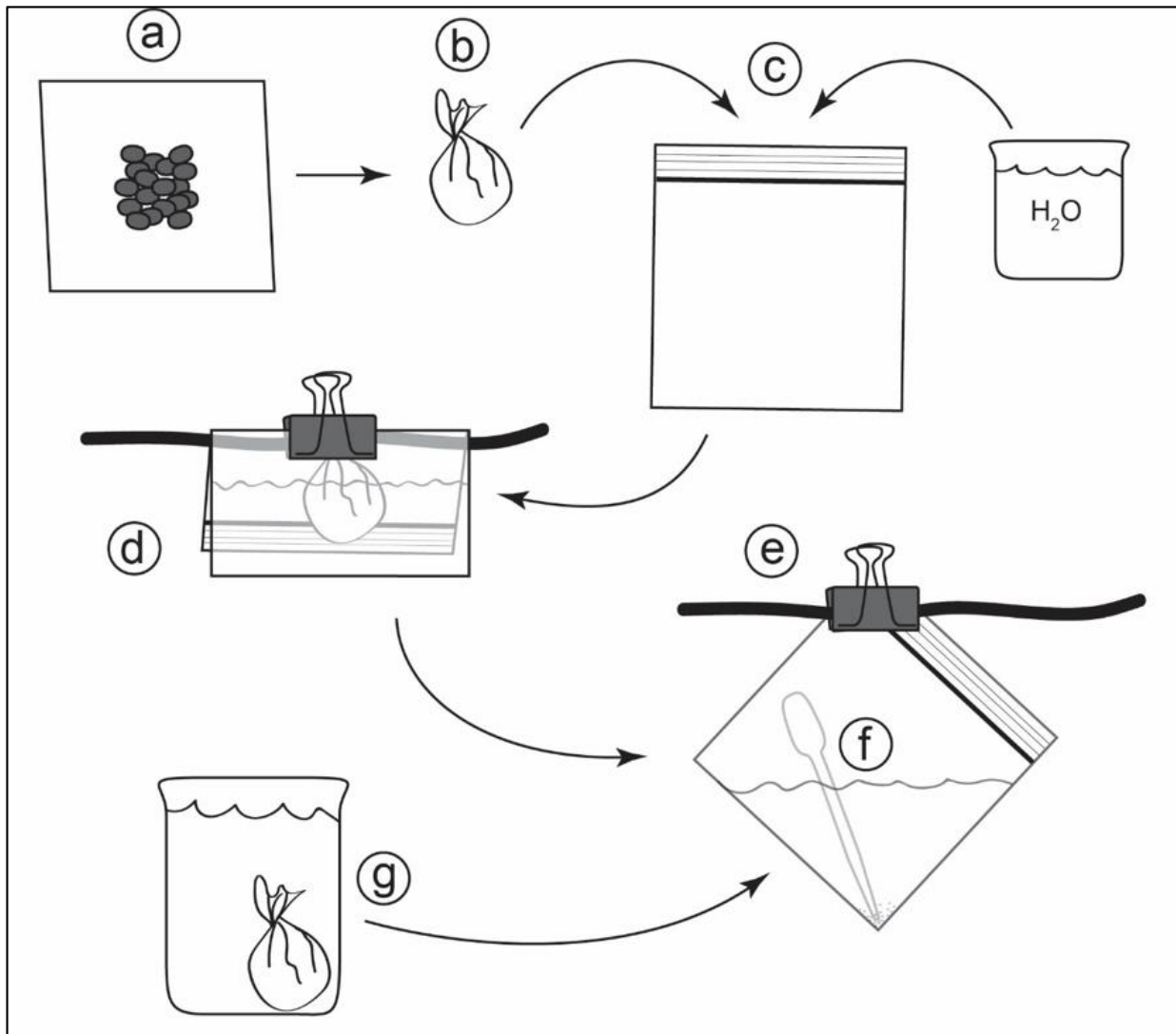


Fig. 5.— Procedure for isolating larval protostrongylids from feces. Fecal pellets placed on a sheet of single-ply paper towel or cheese cloth (a); corners are lifted and tied/twisted together to form a pouch (b); the pouch is placed in a plastic bag with sufficient water to cover the feces (c); the plastic bag is folded over a sturdy cord and clipped in place with a binder clip (ideally the fecal pouch is also held off the floor of the plastic bag using the clip) (d); after 12 to 24 hours the fecal pouch is discarded and the bag is again clipped to the cord at an angle to allow debris and worms to settle into a corner (e); after at least one hour of settling time, a transfer pipette is used to transfer settled material to a Petri dish for examination under high magnification (f); An alternative to step (d) is to place the pouch in water in a beaker or cup (g), then remove pouch after 12 to 24 hours and discard, transfer water from cup to plastic bag and perform steps (e, f).

5. HELMINTH PRESERVATION

5.1. *Nematodes*.—Unlike the acoelomate flatworms (cestodes and trematodes), roundworms should not be relaxed in water as the high solute concentration inside the worm's pseudocoelom will cause water to be drawn in via osmosis, ultimately causing the cuticle to rupture. Nematodes should always be held in physiological saline until they are preserved. Placing living nematodes directly in ethanol will induce muscle contractions that may coil or contort the body in ways that make it difficult to examine morphologically.

- 1) Heat-killing using one of the following methods provides an efficient means to address this:
 - a) Place nematodes in a small Petri dish and remove excess saline. Add near-boiling water to a larger (100 mm) Petri dish, then place the small dish nested within the larger dish. Nematodes will be killed by heat transfer.
 - b) Alternatively, heat saline to near boiling and pour this directly over living nematodes. A small butane camp stove and metal cup can be convenient for heating saline on demand in the field.
- 2) Once they are heat-killed and clean, nematodes should be lifted into tubes filled with 80% ethanol. Especially large nematodes can be laid out into Petri dishes with ethanol for an hour or more before putting them into tubes to help prevent them from stiffening in a contorted position in the vial. If it is not an option to heat water or saline, live nematodes can be placed directly into ethanol, but note that this will usually cause them to curl tightly before death, reducing their utility for morphological identification. This will, at minimum, preserve their DNA for molecular applications.

5.2. *Cestodes*.—Tapeworms must die in a relaxed state if they are to be useful for morphological investigation. Placing live cestodes directly in ethanol will cause their muscles to contract, which obscures key morphological features. If the host was frozen or otherwise preserved before necropsy then the parasites will be dead and nothing can be done to change the condition of the helminths, but the quality of a field-collected tapeworm that has been properly relaxed is far superior to such material.

- 1) To relax live cestodes, use one of the following methods:
 - a) For small or thin tapeworms, simultaneously relax and kill tapeworms by pouring very hot (steaming, but not boiling) water directly over them. Swirling them in the dish with forceps (being careful not to pinch) immediately after the hot water is applied can encourage complete relaxation.
 - b) If tapeworms are very large, leaving them in a dish with clean water for several hours will result in gradual relaxation and eventual death via osmotic shock. This method should not be used for small tapeworms, however, as smaller worms are likely to degrade rapidly. Occasional swirling of the worms with forceps can help to wash off debris.
- 2) Once the tapeworms are relaxed they can be transferred to a labeled vial of appropriate size. Worms should not occupy more than 25% of the volume of a vial. The remaining volume should be completely filled with 80% ethanol. Multiple individuals can be placed in a single vial, but parasites from different organs should not be mixed and it may be desirable to

separate major taxonomic groups or morphotypes. For large worms it is recommended to pour off and replace the ethanol after 24 hours.

- 3) If time in the field permits, a good practice is to lay tapeworms straight and flat in a Petri dish with 80% ethanol for several hours prior to transferring them to a vial. This stiffens the worms in a flattened position, which is conducive to later slide-mounting.
- 4) When lifting tapeworms, do not grip with forceps, which risks breaking the worm. Slide the forceps beneath the worm and lift up. For tapeworms with especially long and thin necks, the scolex can be caught in the surface tension of the liquid in the dish and broken off. To prevent this, ensure that the neck and scolex lie alongside a more robust segment of strobila before it is lifted through the surface of the liquid.

5.3. Trematodes.—Like tapeworms, flukes should be heat-killed in water before preserving them in 80% ethanol. Very large trematodes, like very large cestodes, can be held in water until dead.

5.4. Acanthocephalans.— Key diagnostic features of spiny-headed worms are found in the spine-covered proboscis and neck, which may be retracted into the body when these worms are initially removed from the small intestine. Soaking in freshwater for several hours will increase the internal pressure of the body cavity until the proboscis protrudes. Once the proboscis is fully everted, which can be checked by eye using a hand lens if necessary, the worm should be preserved in 80% ethanol. Note that high internal pressures in acanthocephalans can increase the potential for the body wall to rupture, so care should be taken when handling specimens.

6. LONG-TERM STORAGE OF SPECIMENS

Both host and parasite specimens should be archived in appropriate museum collections to ensure their availability for future investigations of parasite diversity and parasite-host ecology, coevolution, community assembly, and other topics. In North America, the three largest and taxonomically broad parasite collections are housed in the Division of Invertebrate Zoology at the National Museum of Natural History, the Manter Laboratory of Parasitology at the University of Nebraska-Lincoln, and the Division of Parasites at the Museum of Southwestern Biology (University of New Mexico).

To facilitate archiving, specimens should be stored from the moment of collection in vials that are stable over long periods of time and that seal tightly to avoid loss of ethanol. Prior to purchasing vials for the field, it is a good idea to seek recommendations from collection personnel at the institution at which you intend to archive specimens. Borosilicate vials are widely used and effective, and can be purchased in a range of volumes (4 ml and 20 ml are recommended), though they are heavy and can be expensive. Caps should be made of good quality thermosetting plastic to resist expansion and contraction with temperature fluctuations, and they should be lined with PTFE rather than pulp or foil. Care must be taken to avoid breakage of these vials. Increased internal pressures caused by elevated temperatures (e.g., direct sunlight warming ethanol-filled vials) or significant changes in atmospheric pressure (e.g., during air travel) can lead to vials shattering. Cryo-Store[®] low temperature vials and caps

(perfector.com) provide an affordable vial without gaskets that effectively hold ethanol without leaking and are safe for cryo-preservation. Durable alternatives include polypropylene screw-top plastic vials (2 ml) with silicon O-rings mounted in the caps, or larger volume (20 ml) polyethylene scintillation vials with tightly sealing urea or polypropylene caps with plastic liners, though these materials offer poorer clarity for viewing specimens and their labels.

Given that DNA sequencing offers a critical tool for confirming parasite species identities, it is important to store specimens so as to preserve DNA for as long as possible. Over time, DNA quality in ethanol-preserved helminths held at room temperature degrades. Though a comprehensive assessment of the rate of DNA degradation has not been performed, our experience indicates that holding ethanol-preserved specimens at -20°C or colder extends the utility of ethanol-preserved helminths for molecular applications by several years, at least. To maintain value for morphological analysis, specimens should be held at temperatures above the freezing point of the ethanol in which they are held. Given that 80% ethanol has a freezing point of roughly -60°C, storage of helminths at colder temperatures could damage morphological features of helminths. Though helminth DNA can survive brief periods of time at room temperature (e.g., during field collections and bouts of specimen processing), specimens should be permanently housed in freezers as soon as they are returned from the field. If freezer space is unavailable, refrigeration offers a next-best alternative.

Given the uncertain shelf-life of DNA in ethanol-preserved helminths, a good practice is to subsample parasite tissues for cryopreservation after returning from the field. However, this requires considerable time and resources (e.g., extra vials), which must be weighed against other considerations. Completing this step should be considered a lower priority than collecting and ethanol-preserved high quality parasite material as described in the above procedures. Any individual worm that is subsampled must be tracked individually in separate vials (both fluid-preserved and frozen portions) so that genomic data can later be linked to the morphology of the specimen from which it was derived. Taxon-specific strategies for subsampling parasite tissues for cryopreservation include the following:

- *Large nematodes* (>1 cm) – use a sharp scalpel to remove the anterior and posterior ends of the worm and preserve them in ethanol; freeze the middle portion of the body; clean utensils thoroughly between specimens
- *Small nematodes* (<1 cm) – if a large infection, collect a sample of worms to preserve in 80% ethanol and another sample to freeze in 95% ethanol (in this case the ethanol helps individual worms to be separated after freezing); note that this can be problematic in cases of mixed infections of cryptic diversity
- *Cestodes* – remove and freeze the posterior 10-50 (depending on size) gravid proglottids from the strobila; preserve the scolex, neck, and mature proglottids in ethanol
- *Trematodes* – if a large infection, collect a sample of worms to preserve in 80% ethanol and another sample to freeze in 95% ethanol; before preservation, do your best to ensure that distinct morphotypes are separated and archived in separate vials
- *Acanthocephalans* - if a large infection, collect a sample of worms to preserve in 80% ethanol and another sample to freeze in 95% ethanol; before preservation, do your best to ensure that distinct morphotypes are separated and archived in separate vials

7. PERSONNEL SAFETY

A concern when necropsying wild animals is the potential for investigators to come into contact with zoonotic pathogens carried by study organisms (Kunz et al. 1996), though there is often a disconnect between the actual vs. perceived risk associated with these dangers (Hafner 2007). Arthropod-vectored pathogens (e.g., *Yersinia pestis*, *Borrelia burgdorferi*, *Rickettsia rickettsii*, *Babesia microti*) are a risk, as handling small mammals may increase potential to encounter infected ectoparasites, but treating specimens with chloroform or isoflurane to immobilize ectoparasites prior to necropsy should reduce this risk. Dissection of specimens also has potential to place field workers in contact with blood-borne zoonotics such as *Trypanosoma cruzi*, which is increasingly prevalent across southern North America. Rabies virus, among others, is a potential concern as well, particularly when working with small carnivores and bats.

Zoonotic helminths are relatively uncommon in North America, but field biologists should be aware of potential sources of infection. Tapeworms of the genus *Echinococcus*, which parasitize canids, can cause significant disease in humans if eggs shed in feces are ingested (Kern et al. 2003). Metacestodes, which typically are found in rodents, can become established in human liver, lungs, or other tissues and can reproduce asexually. Over several years, the cysts of the larval cestodes grow to the point of eventually destroying organ function. *Baylisascaris procyonis* is an intestinal roundworm of raccoons that is acquired when a human ingests eggs that are shed in feces (Murray 2002). The larval stage migrates through host tissues and can cause severe brain inflammation. Though eggs encountered from the raccoon's gut during necropsy should not at that point be infective, care should be taken to avoid ingesting eggs that have had time to mature in the environment (e.g., attached to the fur), and work surfaces and utensils should be thoroughly cleaned to minimize future risk of infection from eggs released during the necropsy. Major zoonotic parasites such as *Trichinella* spp. and *Taenia solium* are primarily acquired by eating uncooked, infected meat. Helminths that occur in rodents, lagomorphs, shrews, and other small mammals are not known to directly infect humans.

In general, adherence to basic common-sense precautions (e.g., separation of mammal prepping and sleeping/cooking areas; wearing nitrile gloves during specimen necropsies; regular hand washing, wearing DEET based repellent and/or permethrin treated clothes while trapping mammals) should be sufficient to reduce the risk of infection from potential zoonoses. That said, before embarking on any field activities investigators should review potential zoonotic parasites/pathogens associated with their study organisms.

While in the field, there exists inherent risks of bodily injury that warrant caution. Although this may seem common sense, we recommend reminding field crew members at onset of any field work that even small injuries have the potential to severely handicap an expedition and increase the chance of potentially life-threatening situations. This is particularly true when working in remote field sites. In addition to acute injuries, long-term bodily damage can be suffered from prolonged discomfort within a field setting. Taking time to adjust lab seating and field vehicle arrangements to maintain good posture can help to prevent back or joint injuries. Care should be taken when using any sharp implement (e.g., knives, scissors, and even forceps) as lacerations and puncture wounds can quickly lead to infection. Razor-blades/scalpels should be avoided. Finally, before each field trip, prepare a comprehensive first-aid kit, including basic first-aid instruction booklet. For expeditionary work, include a backcountry survival kit, satellite phone and/or SPOT transponder, and GPS or GPS-enabled smart device with relevant maps downloaded. Invest in first-aid training for field personnel. Be safe, and happy trapping!

8. LITERATURE CITED

- AVMA. 2013. AVMA Guidelines for the Euthanasia of Animals: 2013 Edition.
- DUSEK, R. J., J. S. HALL, S. W. NASHOLD, J. L. TESLAA, AND H. S. IP. 2011. Evaluation of Nobuto filter paper strips for the detection of avian influenza virus antibody in waterfowl. *Avian Diseases* 55:674-676.
- FORRESTER, S. AND M. LANKESTER. 1997. Extracting protostrongylid nematode larvae from ungulate feces. *Journal of Wildlife Diseases* 33:511-516.
- GARDNER, S. L. 1996. Field parasitology techniques for use with mammals. Pp. 291-298 in *Measuring and Monitoring Biological Diversity: Standard Methods for Mammals* (Wilson DE, Cole FR, Nichols JD, Rudran R, and Foster MS eds.), Smithsonian Institution Press, Washington, DC.
- GREIMAN, S.E., ET AL. 2018. Museum metabarcoding: a novel method revealing gut helminth communities of small mammals across space and time. *International Journal for Parasitology*, 48:1061-1070.
- HAFNER, M. S. 2007. Field research in mammalogy: an enterprise in peril. *Journal of Mammalogy* 88:1119-1128.
- HIRD, S. M. 2017. Evolutionary biology needs wild microbiomes. *Frontiers in Microbiology* 8.
- JENKINS, E. J., ET AL. 2005. Geographic distribution of the muscle-dwelling nematode *Parelaphostrongylus odocoilei* in North America, using molecular identification of first-stage larvae. *Journal of Parasitology* 91:574-584.
- JENKINS, E. J., A. M. VEITCH, S. J. KUTZ, E. P. HOBERG, AND L. POLLEY. 2006. Climate change and the epidemiology of protostrongylid nematodes in northern ecosystems: *Parelaphostrongylus odocoilei* and *Protostrongylus stilesi* in Dall's sheep (*Ovis d. dalli*). *Parasitology* 132:387-401.
- JONES, C., W. J. MCSHEA, M. J. CONROY, AND T. H. KUNZ. 1996. Capturing mammals. Pp. 115-155 in *Measuring and Monitoring Biological Diversity: Standard Methods for Mammals* (Wilson DE, Cole FR, Nichols JD, Rudran R, and Foster MS eds.), Smithsonian Institution Press, Washington, D.C.
- KERN, P., K. BARDONNET, E. RENNER, H. AUER, Z. PAWLOWSKI, R. W. AMMANN, D. A. VUITTON, P. KERN, AND EUROPEAN ECHINOCOCCOSIS REGISTRY. 2003. *European echinococcosis* registry: human alveolar echinococcosis, Europe, 1982-2000. *Emerging Infectious Diseases* 9:343-349.
- KUNZ, T. H., R. RUDRAN, AND G. GURRI-GLASS. 1996. Human health concerns. Pp. 255-264 in *Measuring and Monitoring Biological Diversity: Standard Methods for Mammals* (Wilson DE, Cole FR, Nichols JD, Rudran R, and Foster MS eds.), Smithsonian Institution Press, Washington, DC.
- KUTZ, S. J., ET AL. 2007. Serendipitous discovery of a novel protostrongylid (Nematoda: Metastrongyloidea) in caribou, muskoxen, and moose from high latitudes of North America based on DNA sequence comparisons. *Canadian Journal of Zoology* 85:1143-1156.
- KUTZ, S. J., ET AL. 2013. Invasion, establishment, and range expansion of two parasitic nematodes in the Canadian Arctic. *Global Change Biology* 19:3254-3262.
- LONGMIRE, J. L., M. MALTBIE, AND R. J. BAKER. 1997. Use of "Lysis Buffer" in DNA isolation and its implication for museum collections. *Occasional Papers Museum of Texas Tech University* 163.

- LUTZ, H. L., V. V. TKACH, AND J. D. WECKSTEIN. 2017. Methods for Specimen-based Studies of Avian Symbionts. Pp. 157-183 in *The Extended Specimen: Emerging Frontiers in Collections-Based Ornithological Research* (Webster MS ed.), CRC Press, Boca Raton, FL.
- MURRAY, W. J. 2002. Human infections caused by the Raccoon roundworm, *Baylisascaris procyonis*. *Clinical Microbiology Newsletter* 24:1-7.
- NOBUTO, K. 1963. Toxoplasmosis in animal and laboratory diagnosis. *Proceedings of the Society of Plant Protection of North Japan* 14:45-46.
- PRITCHARD, M. H. AND G. O. KRUSE. 1982. *The Collection and Preservation of Animal Parasites*. University of Nebraska Press, Lincoln, NE.
- RAUSCH, R. L. 1952. Studies on the helminth fauna of Alaska XI. Helminth parasites of microtine rodents: taxonomic considerations. *Journal Parasitology* 38:415-444.
- RAUSCH, R. L. 1957. Distribution and specificity of helminths in microtine rodents: evolutionary implications. *Evolution* 11:361-368.
- RAUSCH, R. L. 1963. A review of the distribution of Holarctic recent mammals. Pp. 29-43 in *Pacific Basin Biogeography* (Gressitt JL ed.), Bishop Museum Press, Honolulu, Hawaii.
- RAUSCH, R. L. 1994. Transberingian dispersal of cestodes in mammals. *International Journal for Parasitology* 24:1203-1212.
- SIKES, R. S. AND ANIMAL CARE AND USE COMMITTEE OF THE AMERICAN SOCIETY OF MAMMALOGISTS, 2016. 2016. Guidelines of the American Society of Mammalogists for the use of wild mammals in research and education. *Journal of Mammalogy* 97:663-688.
- TKACH, V. V., A. G. HOPE, S. E. GREIMAN. In Press. Method for the rapid fixation of gastrointestinal helminths in small mammals. *Acta Parasitologica*.
- VEROCAI, G. G., S. J. KUTZ, M. SIMARD, AND E. P. HOBERG. 2014. *Varestrongylus eleguneniensis* sp. n. (Nematoda: Protostrongylidae): a widespread, multi-host lungworm of wild North American ungulates, with an emended diagnosis for the genus and explorations of biogeography. *Parasites & Vectors* 7:556.

9. FIELD PROCESSING EQUIPMENT LIST

This section lists materials required for collecting and processing mammals and parasites in the field. We have included quantities of supplies that are appropriate for a crew of 4 individuals, sufficient for two nights of rigorous sampling and processing, such as a week-end trip, or for 100 mammal specimens. The same equipment list could also accommodate much more ambitious expeditions of several weeks or more with only consumable supplies needing to be adjusted based on expected numbers of captures. Not all items are essential for every trip, and this list is adjustable given the needs or focus of particular field crews/goals. There also exists some redundancy between materials and equipment for mammal vs. parasite processing.

9.1. Trapping supplies.—Assuming collection of small to medium sized mammals and bats. Supplies listed consider general collecting that would require IACUC permissions, as well as appropriate state and federal collection permits - As such specialized supplies for targeted sampling (e.g., advanced mist-net arrays) of particular species/groups are not listed. This list includes both live-traps and kill-traps, as well as nets for collection of bats. It is researchers' responsibility to set traps in numbers that accommodate limits on permitted specimen numbers per locality.

- 1- GPS unit per trap-setting team (so that every trap capture is marked with a waypoint)
- 200 - Museum style snap traps
- 200 - Sherman®, Fitch style, or other type of live trap.
- 100 - small pitfall traps (e.g., 44 oz - tall plastic stadium cup)
- 12 - Havahart®/Tomahawk® cage traps
- 12 - gopher traps
- 4 - mist nets
- 8 - 10ft conduit poles (or longer for double or triple-high net arrays) with 4ft rebar, hammer, and roll of parachute cord.
- 8 - trap bags (canvas shoulder carrier bag)
- 2 - rolls blaze-orange or hot pink surveyors tape
- 2 lbs - rolled oats (not quick-cook; fits into gallon Ziploc® for safer storage)
- 2 lbs - smooth peanut butter
- 2 - cans cat food/tuna
- 2 - clamming shovels (or other small shovel)
- 1 - pitfall auger (Seymour® Adjustable Iwan Post Hole Auger with 4" capacity)
- 100 - sandwich and/or snack size Ziploc®-style bags (one bag per mammal specimen)
- 50 - quart size Ziploc®-style bags
- 24 - gallon Ziploc®-style bags
- 4 - thick Sharpie® markers

9.2 - Small mammal processing supplies.—We do not include supplies for cleaning or disinfecting traps/nets, which may be required in certain instances.

9.2.1 - Field Laboratory.—

- 100 - numbered data sheets in a ring-binder (e.g., institutional museum specimen pages)
- 100 - skull tags
- 10 - cardstock for additional specimen number tags (for parasites, embryos, etc.)

- 1 - roll assignable barcode labels for tubes/vials/tags
- 1 - notebook for spare note paper (for keeping notes on repro - condition and parasites)
- 1 - prep tent (essential for areas with biting flies)
- 1 - prep table (foldable but sturdy, stable, and flat)
- 4 - chairs (foldable)
- 1 - filled 10 L liquid nitrogen dewar
- 1 - gallon of 200 proof ethanol
- 1 L - Longmire's solution (tissue buffer for storing subsamples at room temperature)
- 0.5 L - RNAlater® (for storing subsamples for viral testing or transcriptomics)
- 1 - bottle of isoflurane (for euthanasia and for sedating ectoparasites)
- 1 - bag cotton balls (to wet with isoflurane)
- 1 - bottle anti-bacterial dish soap (to make wash bath for tools)
- 1 - pack of bleach wipes (for cleaning surfaces)
- 1 - roll paper towels
- 2 - boxes Kimwipes®
- 300-500 - 2 ml - external thread cryotubes (for tissue storage); racked in freezer boxes
- 100 - 2 ml - screw-top tubes (for fluid-preserved tissue sub-samples); racked in boxes
- 25 - 50 ml - falcon tubes (for fluid-preserving larger samples; e.g., whole guts, embryos)
- 25 - 15 ml - falcon tubes (for fluid-preserving larger samples; e.g., whole guts)
- 1 - roll electrical tape
- 2 - racks/boxes for holding and organizing cryotubes/vials
- 2 - boxes assorted size nitrile gloves
- 3 - plastic pint/quart beakers/containers for tool wash (dirty rinse, soap, clean rinse)
- 1 - magnifying glass (for viewing small diagnostic features, e.g., of dentition)
- 4 - Uni-ball® pens (fade-proof, waterproof archival ink)
- 4 - thin Sharpie® markers (for writing on plastic)
- 4 - pencils
- 1 - paper scissors
- 6 - small dissection scissors
- 2 - large dissection scissors
- 6 - small forceps
- 6 - large forceps
- 3 - 30 cm rulers
- 4 - Pesola® scales (10g, 100g, 300g, 1000g) or 1 - battery-operated electronic scale
- 2 doz - disposable plastic pipettes

9.2.2 - Study Skins.—

9.2.2.1 - Full skins.

- 4 - trays
- 50 - skin tags (institutional museum tags)
- 1 - roll surgical cotton (or bulk cotton from hobby store)
- 2 - sheets of acid-free cardboard (for semi-flat skins)
- 1 - bag corn meal or ground corn cob
- 1 - pvc pipe (18-inches) with various gauges of straightened stainless wire
- 1 - pair of wire cutters
- 4 - thin dowel rods (for larger specimens, e.g., rabbits)

- 1 - pocket knife for sharpening dowel rods
- 1 - skinning knife or scalpel (for larger specimens; use with caution!)
- 1 - pack sewing needles
- 1 - spool white cotton sewing thread
- 1 - spool thick-gauge cotton thread (for tying up skeletons)
- 1 - pack cheesecloth (for wrapping crushed skulls)
- 1 - pinning box with pin boards, and minimally 8 pins per specimen
- 1 - toothbrush

9.2.2.2 - Partial skins – may be dried and stored in coin envelopes by fastening a 2 inch square of skin/fur (using a tagging gun) to a piece of thick blot paper labeled with the unique host identifier. Partial skins may still be useful for multiple applications (e.g., contaminants analysis, stable isotopes, DNA).

- 100 - coin envelopes or similar
- 10 - 10"x10" sheets thick blot paper or acid free card stock (cut into 2" squares)
- 1 - Avery Dennison Microtach® tagging gun (or similar brand) with 4.4mm white microfasteners

9.3 - Parasite processing supplies.—Quantities of consumable materials for parasite collection are estimates, as not all mammal specimens are likely to produce parasites or be of appropriate quality for blood smears, coccidian sampling, etc.

9.3.1 - Ecto- and Endoparasite Sampling.—

- 4 - Fine-point permanent markers (black)
- 4 - Pens with archival, ethanol/water-resistant ink
- 20 - 20 ml vials with screw caps
- 200 - 2 to 4 ml vials with screw caps
- 3 - Vial boxes
- 250 - Tags to internally label specimen vials
- 250 - Barcode labels
- 20 sheets - White paper (plasticized is best) and/or white enamel pan
- 1 - stiff bristle brush or flea/lice comb
- 4 boxes - Kimwipes®
- 3 - plastic pint/quart beakers/containers for tool wash (dirty rinse, soap, clean rinse)
- 2-4 - Dissecting scissors – high quality artery or rounded tip; small and medium
- 2 - Scissors - large paper
- 2 - 10x Jewelers loupe or magnifying glass
- 1 - Dissecting microscope (if available)
- 4 - 6"x6" square sheet black plastic/vinyl
- 4 - Headlamp or flashlight
- 4 - Syringes/needles for isoflurane/chloroform
- 100 ml - isoflurane or chloroform
- 1 - plastic beaker (500 ml)
- 4 - large plastic cups (~1 L) for gut waste disposal
- 8 - forceps with assorted tip sizes (narrow and blunt)
- 100 - Disposable plastic transfer pipettes (~3 ml)

- 6 - microscope slides
- 1 - small vacuum-sealed insulated water bottle (e.g., Thermos®)
- 3 - 500ml squeeze containers for 80% ethanol
- 3 - 500ml or 1000ml squeeze containers for physiological saline
- 1 - 500ml squeeze container for 95% ethanol
- 100 g - NaCl (physiological saline is 0.9%, made by dissolving 9g NaCl in 1L dH₂O)
- 1 - bottle for mixing saline
- 3 each - glass Petri dishes - both mid-size (~100mm) and small (~60 mm)
- 1 sleeve - 60mm plastic Petri dishes
- 2 sleeves.100mm plastic Petri dishes
- 1 sleeve - 150mm plastic Petri dishes
- 4 L - 95% ethanol
- 50 L - Water
- 1 - Stove or hotplate
- 1 - Pot or kettle

9.3.2 Coccidia Sampling (in addition to standard parasite equipment).—

- 1 L - 2% Potassium dichromate (K₂Cr₂O₇)
- 1 - 500 ml bottle
- 20 - Disposable plastic transfer pipettes (~3 ml)
- 100 - plastic 15 to 30 ml vials

9.3.3 Fecal Pellet Sampling (in addition to standard parasite equipment).—

- 100 ml - silica gel
- 100 - 2 ml plastic screw-top vials

9.3.4 Blood Sampling (in addition to standard parasite equipment).—

- 100 - capillary tubes or glass Pasteur pipettes
- 200 - glass microscope slides
- 1 L - 100% methanol
- 1 - container for dipping slides
- 1 - etching tool
- 1 - slide box
- 100 - Nobuto strips

9.3.5 Protostrongylid Larvae Collection (in addition to standard parasite equipment).—

- 1 roll - thin paper towels or large Kimwipes® or cheesecloth
- 50 - quart Ziploc®-style bags
- 20 - binder clips of assorted sizes
- 50 - plastic transfer pipettes
- 1 - roll parachute cord or ¼” rope (for hanging samples during sedimentation)
- 10 - 250/500 ml beakers or cups

Citation: GALBREATH, K. E., E. P. HOBERG, J. A. COOK, B. ARMIEN, K. C. BELL, M. L. CAMPBELL, J. L. DUNNUM, A. T. DURSAHINHAN, R. P. ECKERLIN, S. L. GARDNER, S. E. GREIMAN, H. HENTTONEN, F. A. JIMÉNEZ, A. V. A. KOEHLER, V. V. TKACH, B. NYAMSUREN, F. TORRES-PÉREZ, A. TSVETKOVA, AND A. G. HOPE. 2019. Building an integrated infrastructure for exploring biodiversity: field collections and archives of mammals and parasites. *Journal of Mammalogy*. DOI:10.1093/jmammal/gyz048