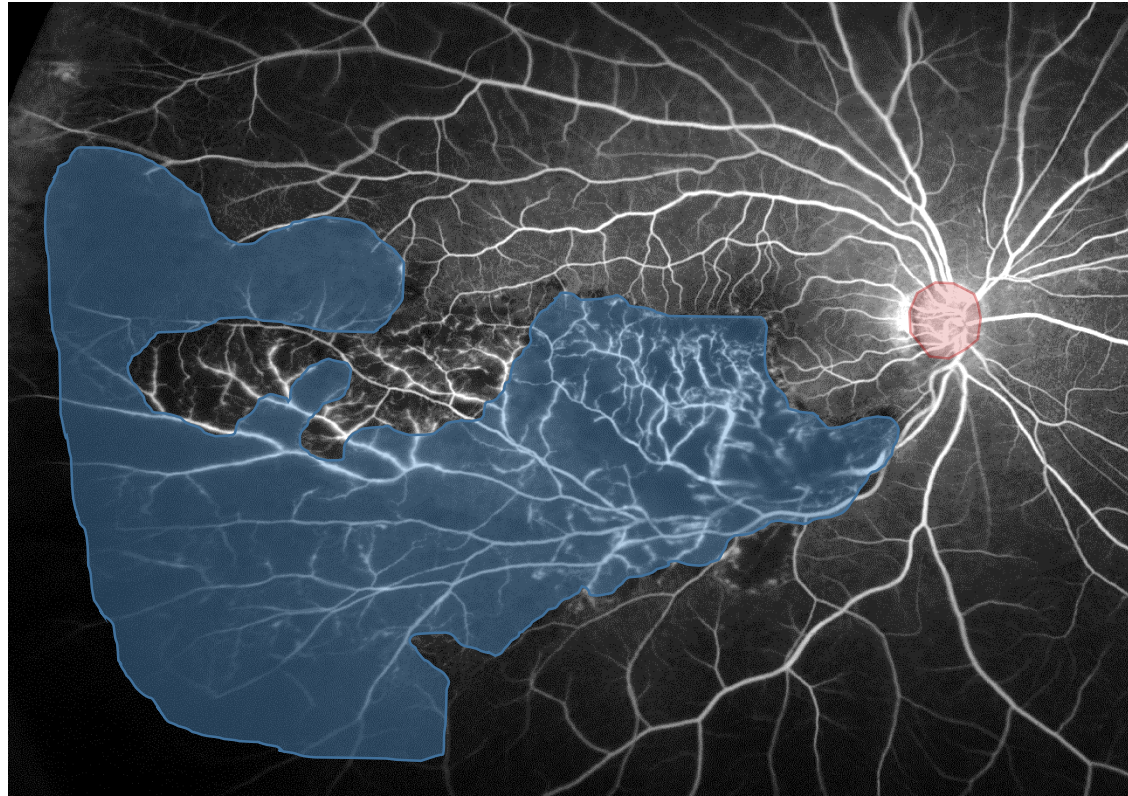


Branch Retinal Vein Occlusion:
Treatment Outcomes
According to the Retinal Nonperfusion Area,
Clinical Subtype, and Crossing Pattern

Yuko Iida-Miwa, Yuki Muraoka, Yuto Iida,
Sotaro Ooto, Tomoaki Murakami, Kiyoshi Suzuma,
Akitaka Tsujikawa

Supplemental figure 1 S1

How to measure the total NPA on a fluorescein angiography image.



This is a representative case of acute BRVO.

On an image of ultra-widefield angiography obtained 1 minute after dye injection, we detected and measured total NPA (blue area) and disc area (DA) (red area) in pixels using a software plugin in the ImageJ program.