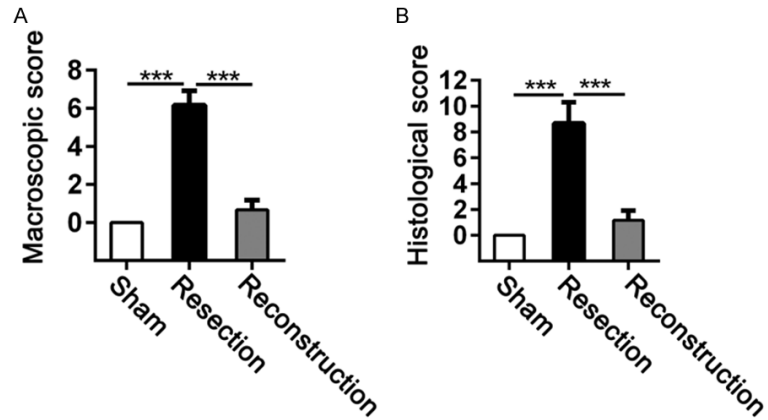
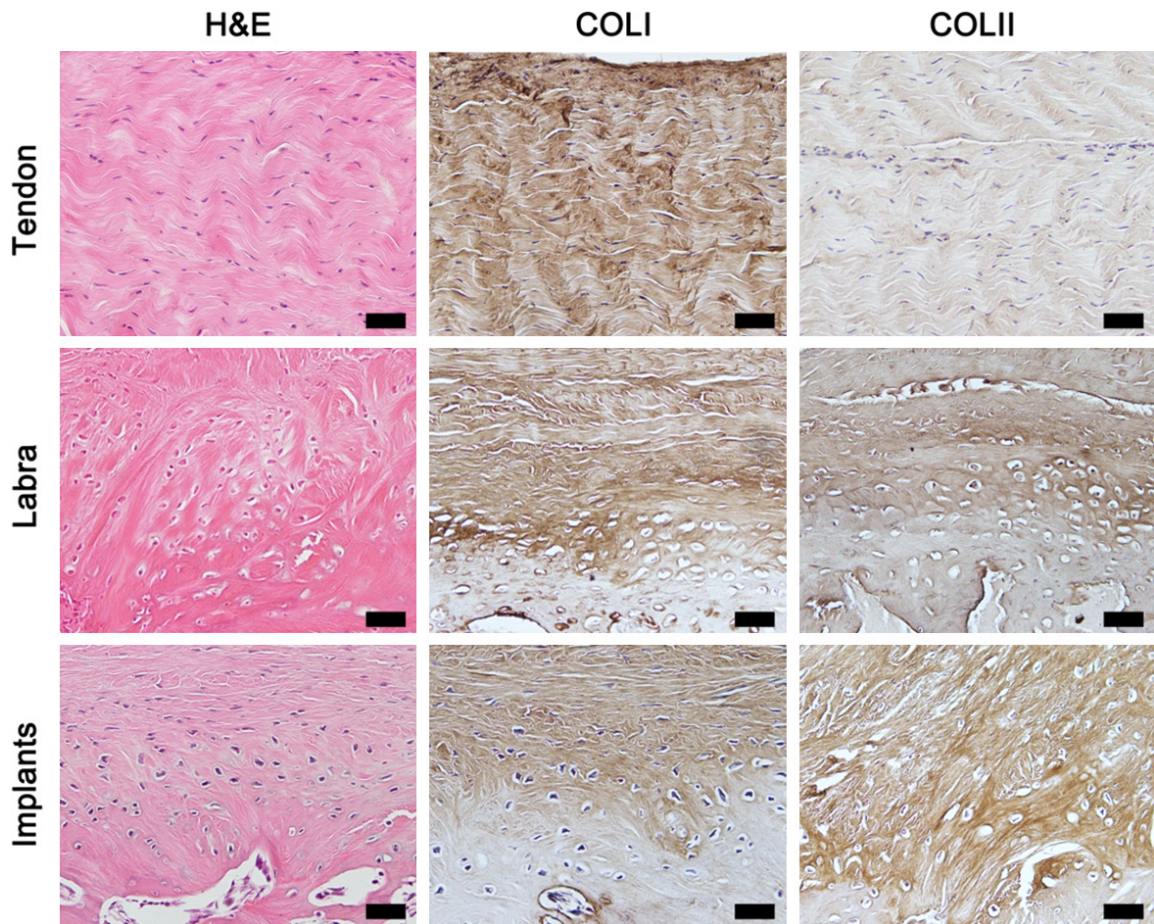


## Labral reconstruction attenuates osteoarthritis



**Figure S1.** Assessment of OA severity in sham-operated, labral resected, and labral reconstructed hip joints by macroscopic and histological scores at 24 weeks postoperatively. A, B. Macroscopic and histological scores (sham, n = 3; resection and reconstruction, n = 6; ANOVA). Data are shown as the mean  $\pm$  SD. \*\*\*P < 0.001.



**Figure S2.** Histological assessment of native tendon, labra, and implants in the labral reconstructed groups at 24 weeks postoperatively, including H&E staining and immunohistochemical staining for type I and II collagen (n = 6 for each group). Scale bar, 50  $\mu$ m.