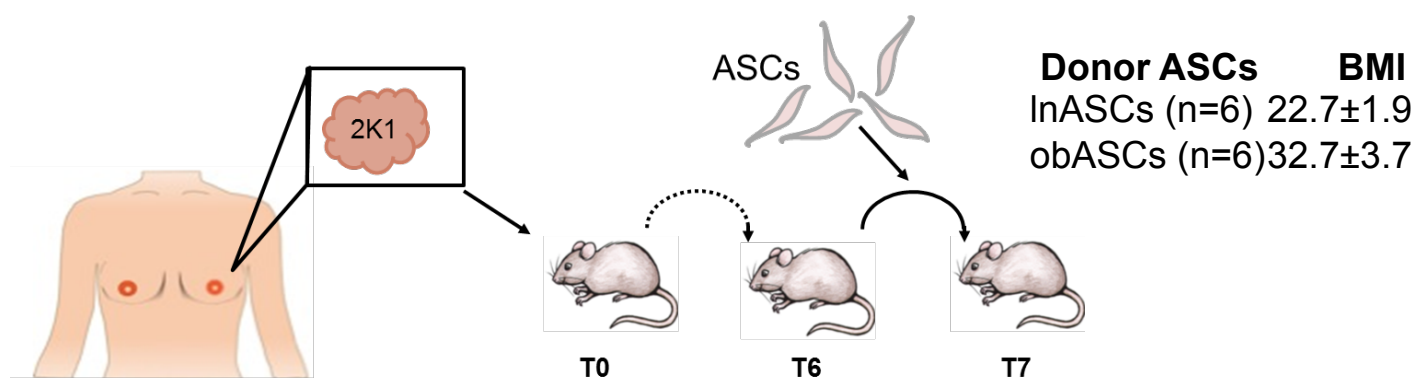
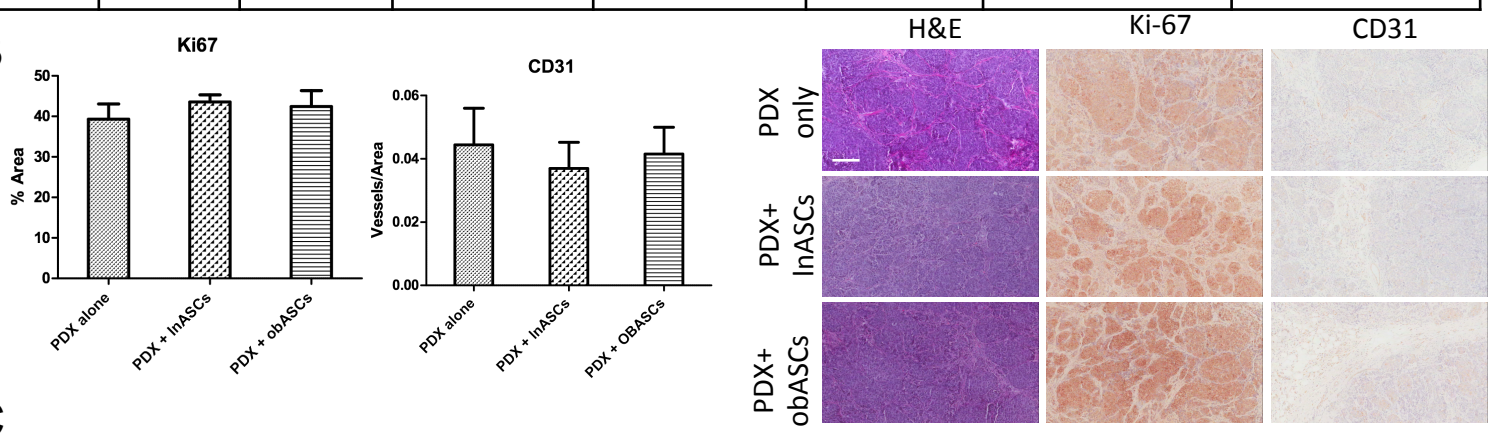
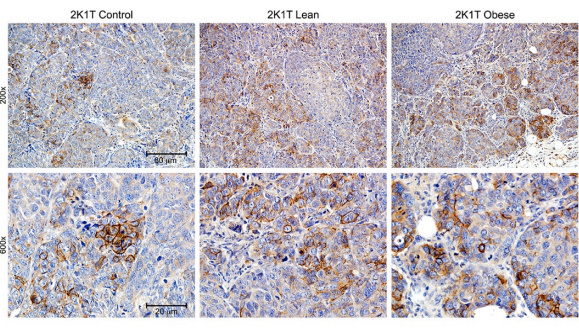
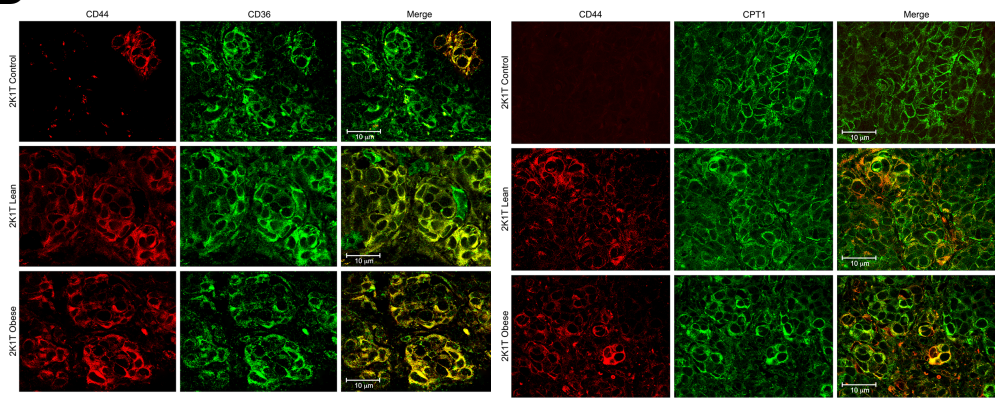


A

PDX no.	Age	Race	PAM50 molecular subtype	Histologic type	Ki67	Lymph node involvement	Distant metastases
2K1	59	AA	TNBC	Invasive ductal carcinoma	>99%	N	N

B**C****D****Supplemental Figure 3**