



Frons corners

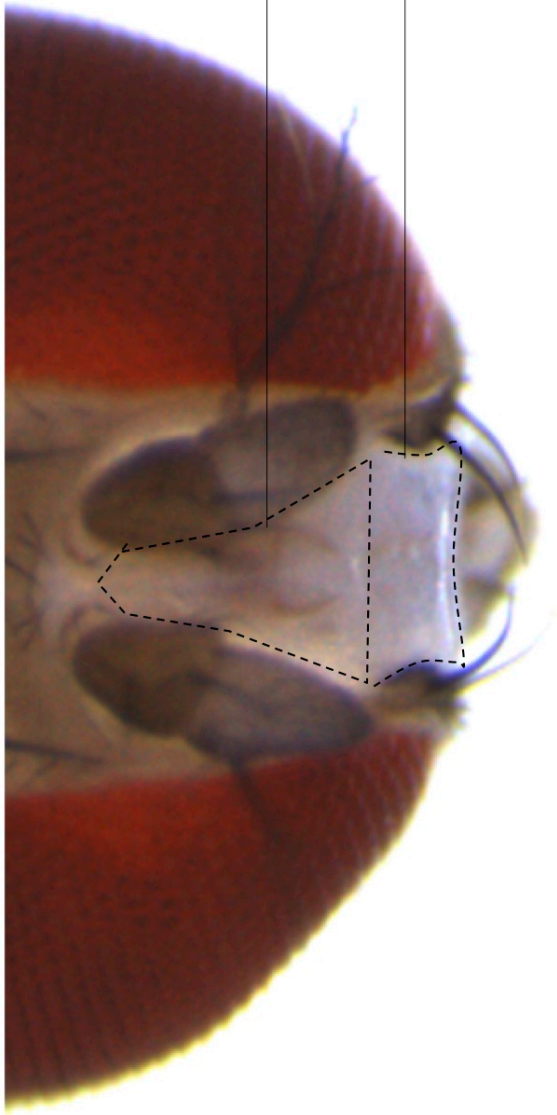
Orbital plates

Ocellar triangle

Frontal triangle

Frons upper color

Frons lower color



Face upper region

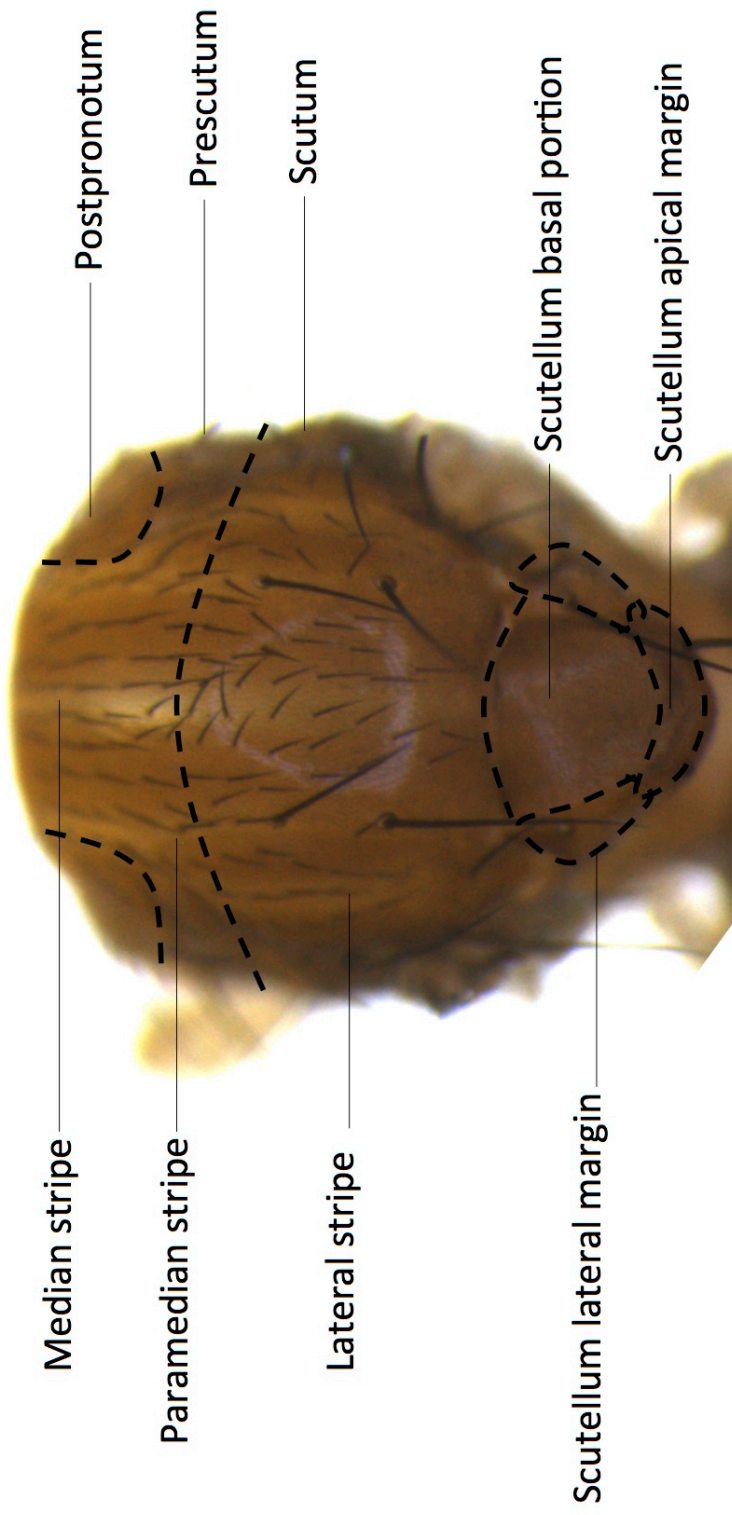
Face lower region



Medial region

Above the foramen region

Marginal region





Mesopleuron (upper half)

Mesopleuron stripe

Mesopleuron (lower half)

