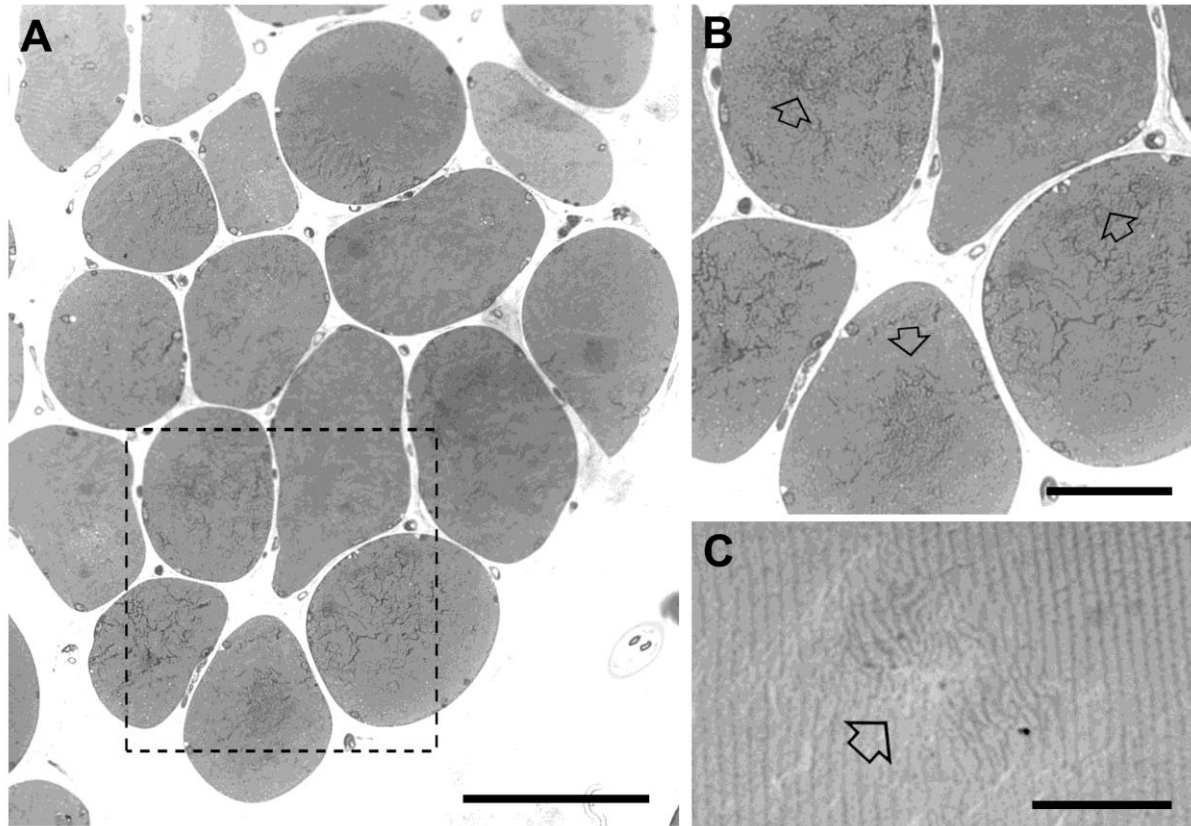


Supplementary Material

Figure S1: *Histological images in cross section of muscle biopsy before (T0) beginning of FES training.*



Arrows in point to internal fiber areas in which disarray of the contractile elements is more evident. Scale bars: A, 100 μm ; B, 40 μm ; C, 20 μm .