

CASE REPORT

Lumbo-sacral spine disease due to bovine tuberculosis in a patient with concurrent pulmonary disease

*Nawaid Ahmad^a, Koottalai Srinivasan^b, Jeannette Panayi^c, Harmesh Moudgil^b^a Specialist Registrar in Respiratory Medicine, City General Hospital, North Staffordshire, Stoke-on-Trent, UK^b Consultant Physician, Princess Royal Hospital, Telford, UK^c TB Specialist Nurse, Princess Royal Hospital, Telford, UK

Originally received 12th December 2010; resubmitted 14th February 2011; revised 4th March 2011; accepted 4th March 2011; online 21st April 2011

Summary

Lumbo-sacral spinal disease due to bovine tuberculosis (TB) in a patient with concurrent pulmonary disease is rare. We report this unpredicted finding in an immunocompetent patient and discuss the natural history in an area of low prevalence.

© 2011 Primary Care Respiratory Society UK. All rights reserved.

N Ahmad *et al.* *Prim Care Respir J* 2011; 20(4): 459-461<http://dx.doi.org/10.4104/pcrj.2011.00037>**Keywords** tuberculosis, bone disease, spine, infectious diseases and infestations, microbiology

Introduction

Mycobacterium bovis (*M. bovis*) is a member of the *M. tuberculosis* complex (MTBC), a very closely related phylogenetic group, which also includes *M. tuberculosis*, *M. microti* and *M. africanum*. It causes pulmonary disease among animals and humans, with extra-pulmonary manifestations usually involving the lymph glands, skin and intestine. Spinal disease with *M. bovis* is reported, but more specific lumbo-sacral involvement in an immunocompetent patient with concurrent pulmonary disease is rare.

Case history

A 63-year-old married woman, previously a company secretary, was referred to the rheumatology clinic with low back pain. She had never smoked, drank alcohol only occasionally, and was physically fit. In the past she had undergone a cholecystectomy and an operation for mechanical alignment of her knee. Her presenting complaint had persisted for two years but more recently had worsened with radiation of pain into her left leg; this was now having a detrimental effect on her quality of life. She had developed anorexia with ill-defined weight loss but no other overt constitutional symptoms.

Initial clinical examination was unremarkable. Investigations showed a normal white cell count ($9.5 \times 10^9/L$) with a slightly low lymphocyte count ($0.9 \times 10^9/L$). Erythrocyte sedimentation rate

(ESR) and C-reactive protein (CRP) were moderately raised at 44 mm/hr and 22 mg/l, respectively. A lumbo-sacral spine X-ray showed degenerative discitis at the L5/S1 level. Magnetic resonance imaging (MRI) scan of the spine was consistent with vertebral osteomyelitis and discitis at the L5/S1 area – see Figure 1.

She was then referred to the orthopedic team. A computed tomography (CT)-guided biopsy from the affected area was consistent with an acute osteomyelitis, although aerobic and anaerobic cultures were sterile. She was commenced on flucloxacillin 1g four times-daily for four weeks, but her CRP remained moderately elevated at 25 mg/l and as such antibiotics were continued for a further four weeks. At eight weeks, her CRP was 41 mg/l and she continued to have back pain with some constitutional symptoms. Microbiological opinion at this point suggested ciprofloxacin 500mg orally twice-daily.

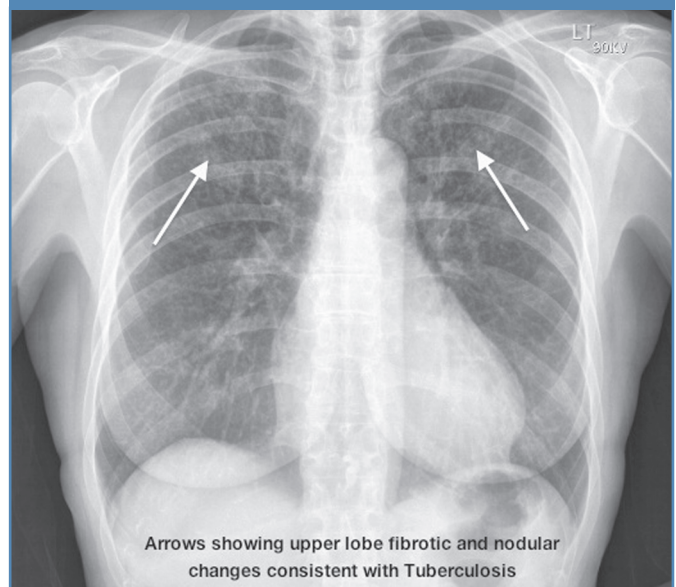
Repeat MRI scan four months post-biopsy identified an L5 abscess with paravertebral and surrounding soft tissue extension. A repeated CT-guided biopsy from the same area on this occasion suggested a tuberculous (TB) osteomyelitis with cultures from bone aspirate positive for *M. bovis*. The patient was referred to the chest physician where a more specific and direct enquiry at this stage revealed that since retirement this woman had been helping her husband on a farm attending their cattle – a mixture of cows, bulls and calves – with some of the

* **Corresponding author:** Dr Nawaid Ahmad, Specialist Registrar in Respiratory Medicine, City General Hospital, University Hospital North Staffordshire, Newcastle Road, Stoke-on-Trent, ST4 6QG, UK. Tel: +44 (0)1782 552329 Fax: +44 (0)1782 552323 E-mail: navydoc@gmail.com

Figure 1. Lumbosacral spine X-ray showing discitis at L5/S1 level

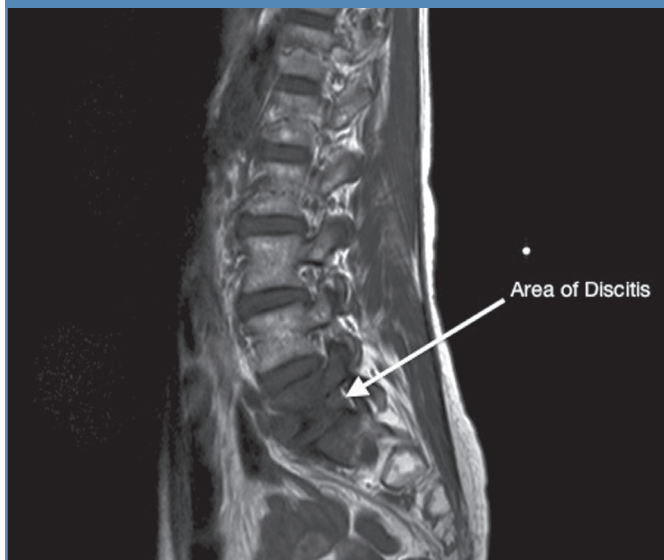

Figure 2. Chest X-ray



herd having been culled due to bovine TB. Importantly, she had never had a BCG vaccination or childhood check-up for TB, but she had consumed unpasteurised milk whilst living on a farm as a teenager. There was no clinical evidence for immunosuppression or any specific risk factor such as medication, malignancy, lymphoma or suggestion of HIV (Human Immunodeficiency Virus) disease. Strain typing of the mycobacterium comparing to the outbreak in the cattle was not possible.

A chest X-ray (CXR) showed changes consistent with TB as shown in Figure 2. A subsequent CT of her chest showed consolidation in the upper lobes with a pattern suggestive of TB and with evidence of calcified adenopathy. She was commenced on a triple regimen of isoniazid (INH), rifampicin (RMP) and ethambutol for the first two months, and a dual regimen of INH+RMP for a further seven months according to current British Thoracic Society guidelines.¹ After initial difficulty with compliance (because of nausea and arthralgia when attempting to take the medication) significant improvements both clinically and radiologically were observed in the chest films whilst she was being treated. This further reinforced compliance. The initial intolerance was in part contributed to by the patient's concerns and expectations about the effectiveness of the medication and its side effect profile; reassured by relatively normal liver blood tests throughout, much of the subsequent management focus was on building patient confidence in the eventual outcome.

Discussion

This case, focusing on bovine TB, is important for a number of reasons. Firstly, this is a rare presentation with lumbo-sacral disease in an immunocompetent patient who was then also

shown to have pulmonary as well as extra-pulmonary disease. Secondly, it reminds us that although TB may be contracted acutely (and particularly occupationally, especially with the age distribution of identified cases in the UK), most cases are considered to be reactivation of prior latent infection and are usually attributed to drinking unpasteurised milk. Thirdly, this form of the disease is less likely after BCG immunisation, which in this case had never been administered during childhood. It is also important to recognise that the average delay in diagnosis of extra-pulmonary disease, excluding visible lymph nodes, is two years. In considering differential diagnoses, it is always worth considering a diagnosis of TB where there is involvement of the disc. Finally, a normal white cell count usually precludes a bacterial infection, whether due to *Staphylococcus aureus* or to an anaerobic gram-negative bacterium usually from the urinary tract.

Movements of infected animals have long been considered a critical factor in the spread of livestock diseases including TB.² During the 1930s, 40% of slaughtered cattle in England and Wales had obvious TB, but rates of disease fell dramatically until the mid 1980s when there was a slight resurgence of bovine TB in cattle especially in South-west England where 1% of cattle herds were affected annually.^{3,4} Confirmed cases now occur in only about 0.4% of UK cattle herds each year, and bovine TB accounts for 0.4% of all human cases of TB in the UK.⁵ Between 1994 and 2007, 79% of the 453 human cases reported to the UK Health Protection Agency (HPA) were aged over 45, suggesting that the majority of the cases seen in the UK are attributable to reactivation of latent infection.⁶ The most frequently reported exposures were due to consumption of unpasteurised dairy products in 41 out of 83 cases (49%) and

Learning Points:

- 1) Bovine TB is an infectious form of TB with pulmonary and extra-pulmonary manifestations needing notification and public health consideration.
- 2) *M. bovis* is resistant to pyrazinamide (part of its definition as a separate species) and therefore the shortest course of treatment is nine months of rifampicin and isoniazid with an initial two months of ethambutol.
- 3) It may present as newly-acquired infection – possibly from occupational exposure in abattoir or farm workers – but may also result from reactivation of latent infection often contracted through drinking unpasteurised milk.
- 4) If the white cell count is normal but clinical evidence suggests a bacterial infection, TB should be considered. Lumbar spine x-rays are no longer the investigation of first choice and an MRI is required in the first instance unless metastatic cancer is expected.

exposure to cattle in 45/123 (37%).⁷ Agricultural workers may acquire the disease by inhaling cough spray from infected cattle, thereby developing typical pulmonary TB. Such patients may infect cattle, but evidence for human-to-human transmission is limited and anecdotal.⁸

Information on human disease due to *M. bovis* in developed and developing countries is scarce. A review of a number of zoonotic TB studies published between 1954 and 1970 and carried out in various countries around the world estimated that the proportion of human cases due to *M. bovis* accounted for 3.1% of all forms of TB; this included 2.1% of pulmonary and 9.4% of extra-pulmonary forms. However, these findings conflict with a study in the Netherlands which showed that the majority of patients with bovine TB had pulmonary rather than extra-pulmonary disease.^{9,10} Similarly, surveys in the United States, Scandinavia, and South England have shown that approximately half of post-primary cases are pulmonary, a quarter involve the genitourinary tract (a rare occurrence in primary disease), and the remainder involve other non-pulmonary sites and notably cervical lymph nodes.¹¹

Bony involvement due to *M. bovis* has been reported rarely. A British study from 1937 showed bone and joint involvement in 20% of cases.¹² Although a skeletal lesion may be the presenting symptom complex, any individual with a skeletal TB lesion must be evaluated for the possibility of other involved sites including the lungs, intestinal tract, and kidneys.¹³ Nevertheless, only about one-third of patients who have TB of a bone or joint have a history of pulmonary disease.¹⁴ Spinal TB involves mainly the thoracic region;¹⁵ involvement of the lumbo-sacral spine as in the case reported here is very uncommon.

Conclusions

Our case demonstrates that, although pasteurisation of milk and control of bovine TB in cattle suggest only a negligible continued health risk in the UK,¹⁶ it can present in the adult Caucasian population either as a consequence of reactivation of prior latent infection (as in our case) or as a new infection arising from more recent exposure to *M. bovis*.

Conflicts of Interest

The authors declare that they have no conflicts of interest in relation to this article.

References

1. Joint Tuberculosis Committee of the British Thoracic Society. BTS Guidelines - Control and prevention of tuberculosis in United Kingdom: Code of Practice 2000. *Thorax* 2000;**55**:887-901. <http://dx.doi.org/10.1136/thorax.55.11.887>
2. Gilbert M, Mitchell A, Bourn D, Mawdsley J, Clifton-Hadley R, Wint W. Cattle movements and bovine tuberculosis in Great Britain. *Nature* 2005;**435**:491-96. doi:10.1038/nature03548
3. Health protection agency website. Mycobacterium bovis. <http://www.hpa.org.uk/HPA/Topics/InfectiousDiseases/InfectionsAZ/1204619502284> (accessed October 2009)
4. Delahay RJ, De Leeuw AN, Barlow AM, Clifton-Hadley RS, Cheeseman CL. The status of Mycobacterium bovis infection in UK wild mammals: a review. *Vet J* 2002;**164**:90-105. <http://dx.doi.org/10.1053/tvjl.2001.0667>
5. De la Rua-Domenech R. Human Mycobacterium bovis infection in the United Kingdom: Incidence, risks, control measures and review of the zoonotic aspects of bovine tuberculosis. *Tuberculosis (Edinb)* 2006;**86**:77-109. <http://dx.doi.org/10.1016/j.tube.2005.05.002>
6. Health protection agency website. M Bovis database 27/10/2008. http://www.hpa.org.uk/web/HPAweb&HPAwebStandard/HPAweb_C/1225700808961.
7. Jalava K, Jones JA, Goodchild T, et al. No increase in human cases of Mycobacterium bovis disease despite resurgence of infections in cattle in the United Kingdom. *Epidemiol Infect* 2007;**135**:40-5. <http://dx.doi.org/10.1017/S0950268806006509>
8. O. Cosivi, J.M. Grange, C.J. Daborn, et al. Zoonotic Tuberculosis due to Mycobacterium bovis in Developing countries. *Emerging Infectious Diseases* 1998;**4**(1):59-70. <http://dx.doi.org/10.3201/eid0401.980108>
9. Gervois M, Vaillant JM, Fontaine JF, Laroche G, Dubois G. Epidemiologie de l'infection humaine par Mycobacterium bovis. *Archivio Monaldi per latsiologia e le malattie dell'apparato respiratorio* 1972;**27**:294-317.
10. Ruys C A. Bovine Tuberculosis. *Mon Bull Min Health* 1946;**5**:67-71.
11. Grange JM, Yates MD. Zoonotic aspects of Mycobacterium bovis infection. *Vet Microbiol* 1994;**40**:137-51. [http://dx.doi.org/10.1016/0378-1135\(94\)90052-3](http://dx.doi.org/10.1016/0378-1135(94)90052-3)
12. Griffiths AS. Bovine Tuberculosis in man. *Vet Rec* 1937;**49**:529-43.
13. Sharrard, W. Infections of bones and joints in Paediatric Orthopaedics and Fractures, edited by W. J. W. Sharrard. Ed. 3, pp. 1247-1284. Oxford, Blackwell Scientific, 1993.
14. Daniel, TM and DeBanne SM. The serodiagnosis of tuberculosis and other mycobacterial diseases by enzyme-linked immunosorbent assay. *Am Rev Respir Dis* 1987;**135**:1137-51.
15. Spinal tuberculosis (Pott's disease): its clinical presentation, surgical management, and outcome. A survey study on 694 patients. *Neurosurgical Review* 2001;**24**(1):8-13.
16. Torgerson P, Torgerson D. Does risk to humans justify high cost of fighting bovine TB? *Nature* 2008;**455**:1029. <http://dx.doi.org/10.1038/4551029a>

Available online at <http://www.thepcrj.org>