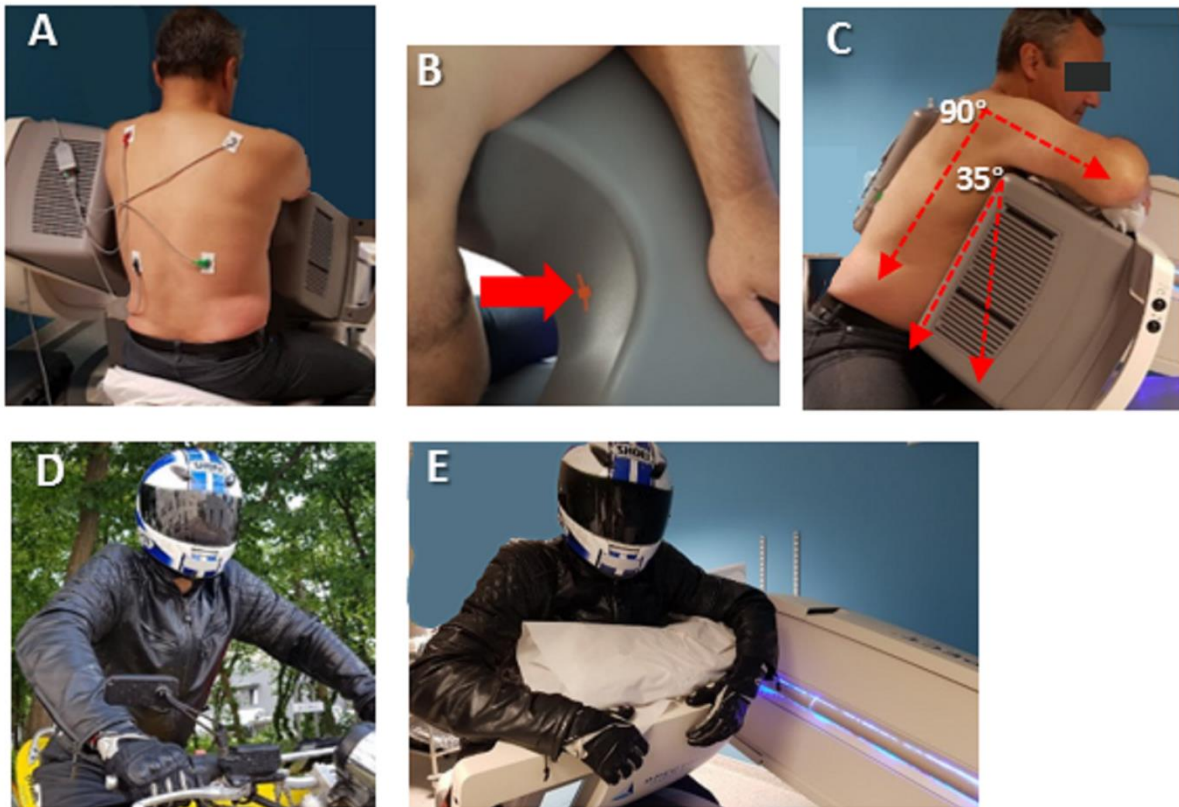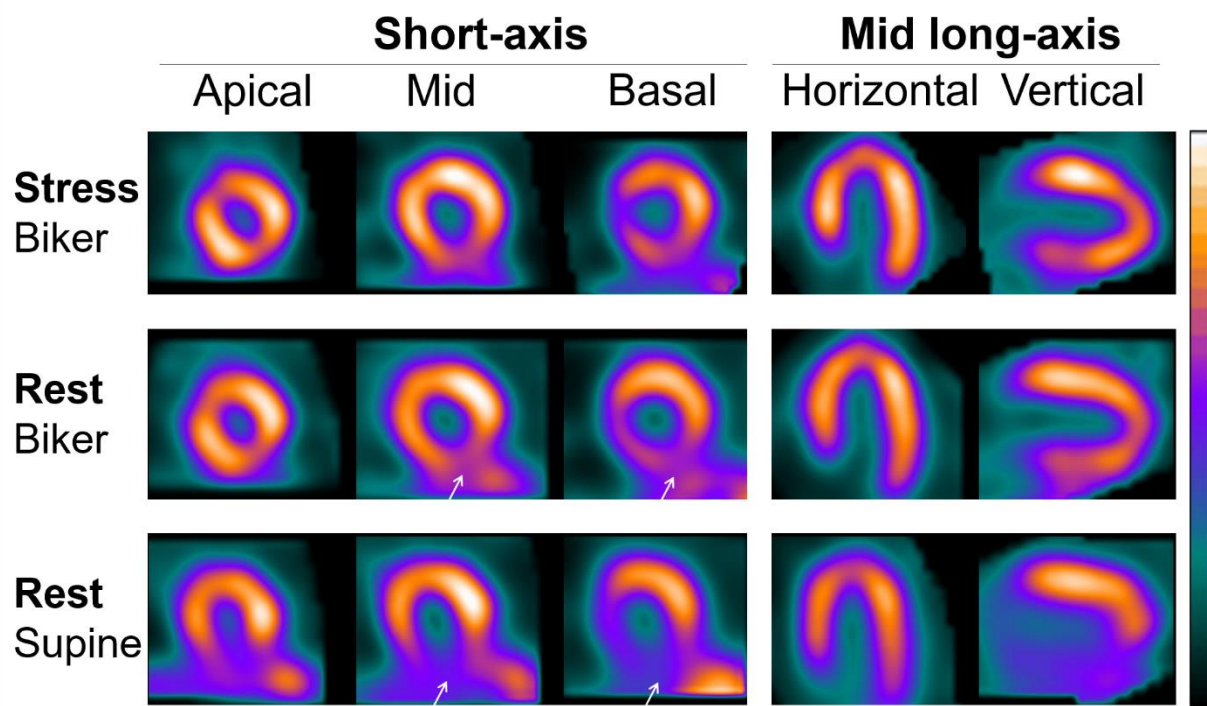


Supplemental Figure 1. Consecutive steps applied for positioning a patient in the biker position with the patient being asked: (A) to sit astride the camera armchair, the camera head being positioned at 35° from vertical (this angle may need to be markedly decreased in certain abdominal obesity patients), (B) to place the chest in close contact with the surface of the camera head and (C) to place the arms orthogonally to the thorax (C), with the result definitely resembling a biker on a motorbike (D, E).



Supplemental Figure 2. Representative SPECT images from the overall recording protocol, in a patient ultimately considered as having attenuation artifacts on the inferior walls of the supine resting-SPECT recording. Note the easier delineation and separation of the inferior wall from subphrenic organs with the biker position than with the supine position (white arrows).