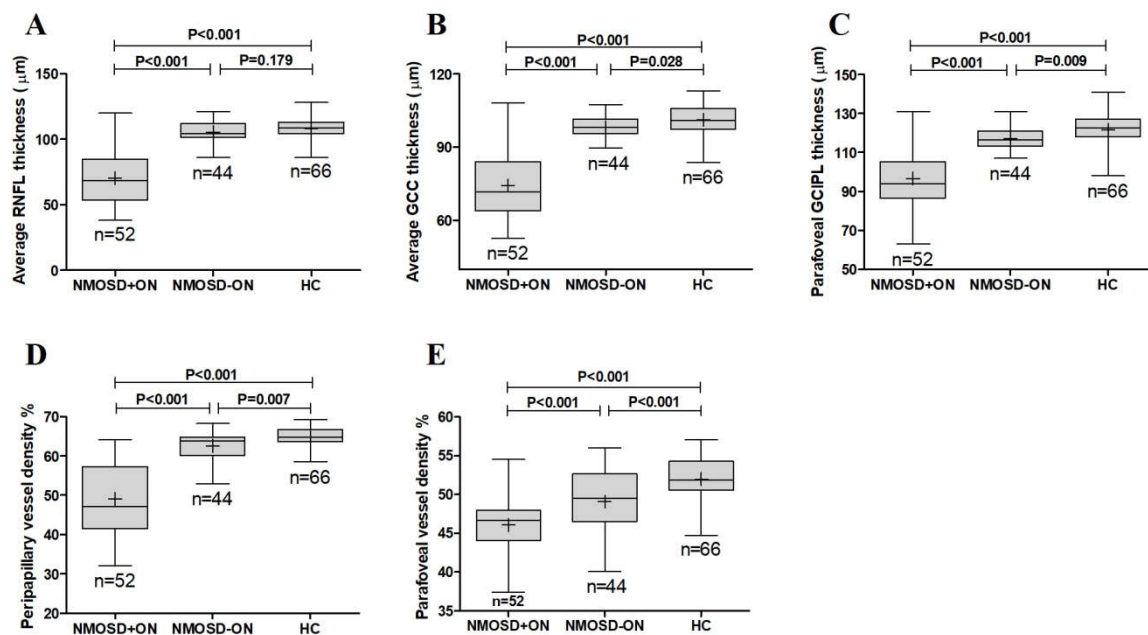


Supplementary material 2. The comparison of average RNFL thickness (A), average GCC thickness (B), parafoveal GCIPL thickness (C), peripapillary vessel density (D), and parafoveal vessel density (E) among the healthy controls, NMOSD eyes with history of ON, and NMOSD eyes without a history of ON (contralateral fellow eyes of 12 patients with only one eye affected were excluded).



RNFL, retinal nerve fiber layer; GCC, ganglion cell complex; GCIPL, ganglion cell and inner plexiform layer; NMOSD, neuromyelitis optica spectrum disorders; ON, optic neuritis; HC, healthy control.