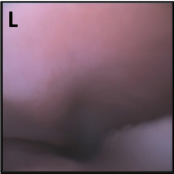


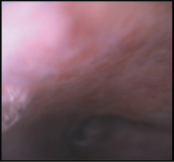
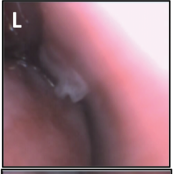
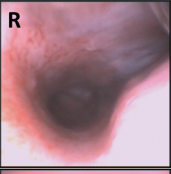
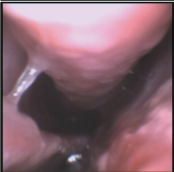
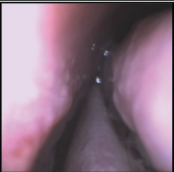


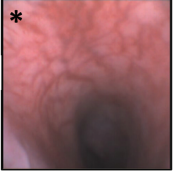



## Supplementary Data

Western Consortium for Cancer Nursing Research (WCCNR) Scale to Assess Nasopharyngeal Mucosal Damage			
Grade 0	Grade 1	Grade 2	Grade 3
No changes	Slight erythema, moist mucosa, no bleeding or infection, mild edema.	Moderate erythema, ulceration, bleeding of mucosa with probing, mild xerostomia, moderate edema.	Severe erythema, more than 1 confluent ulcer, spontaneous bleeding, marked xerostomia, severe edema.

	<div style="display: flex; justify-content: space-around;"> <div style="text-align: center;"> <p><b>L</b></p>  </div> <div style="text-align: center;"> <p><b>R</b></p>  </div> </div>		
Septum (anterior)		Dorsal Turbinate (posterior)	
	<div style="display: flex; justify-content: space-around;">   </div>	<div style="display: flex; justify-content: space-around;"> <div style="text-align: center;"> <p><b>L</b></p>  </div> <div style="text-align: center;"> <p><b>R</b></p>  </div> </div>	
Septum (posterior)		Ventral Turbinate	
	<div style="display: flex; justify-content: space-around;">   </div>	<div style="display: flex; justify-content: space-around;"> <div style="text-align: center;"> <p><b>L</b></p>  </div> <div style="text-align: center;"> <p><b>R</b></p>  </div> </div>	
Dorsal Turbinate (anterior)		Nasopharynx	
		<div style="display: flex; justify-content: space-around;"> <div style="text-align: center;"> <p><b>*</b></p>  </div> <div style="text-align: center;"> <p><b>R</b></p>  </div> </div>	

**SUPPLEMENTARY FIG. S1.** Endoscopic evaluation of nasal mucosa. A mild erythema was identified in one of group B subjects during safety study (\*Grade 1 in Western Consortium for Cancer Nursing Research [WCCNR]). No grade 2 or higher lesion was observed across the groups investigated (B and C).