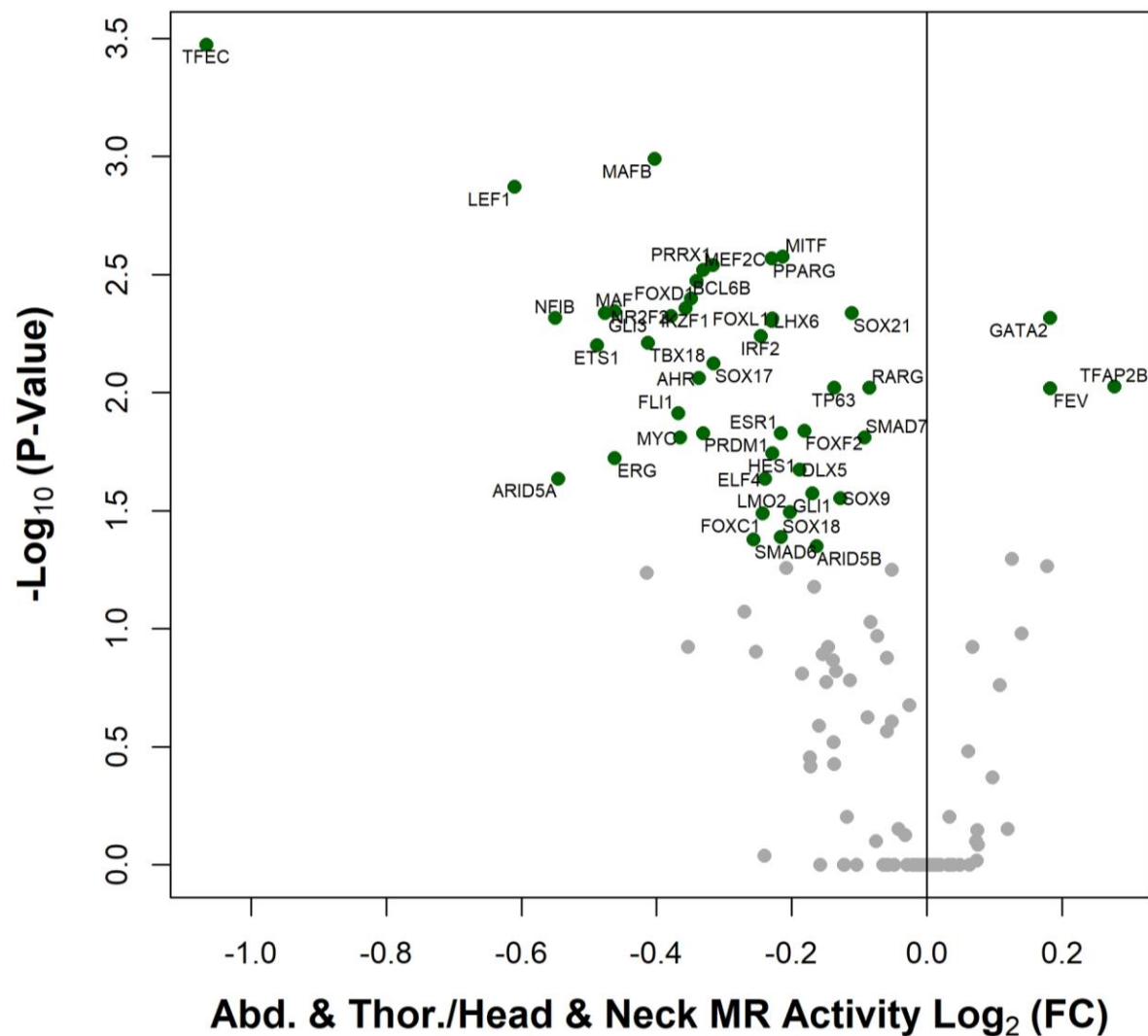
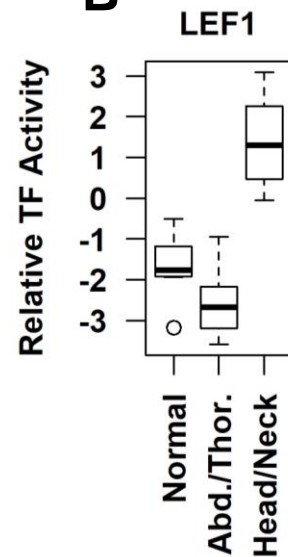
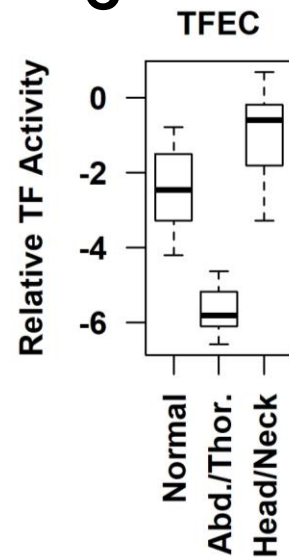
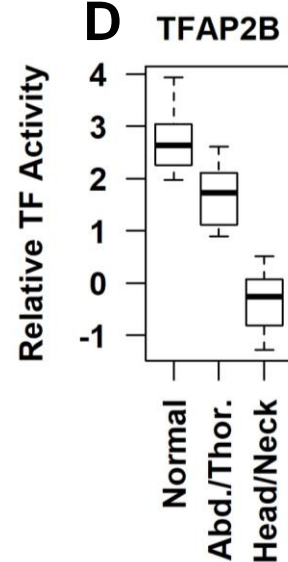
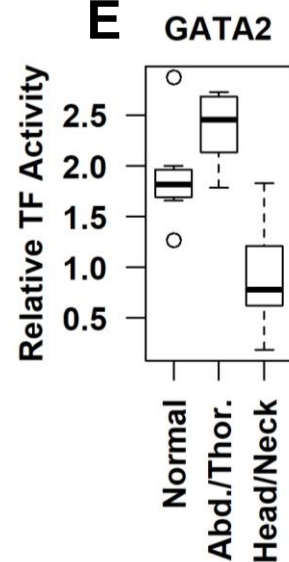


A

Differential SDH-loss PPGL MR activity in SDHD-loss tumors in abdomen & thorax vs. head & neck

**B****C****D****E****Figure S6**