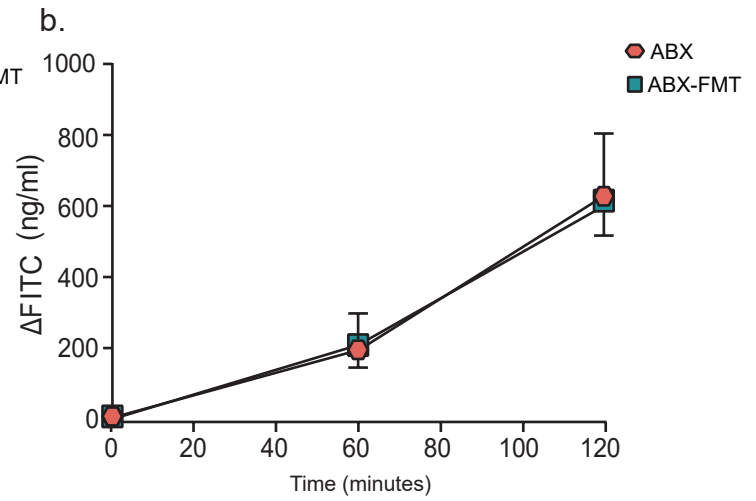
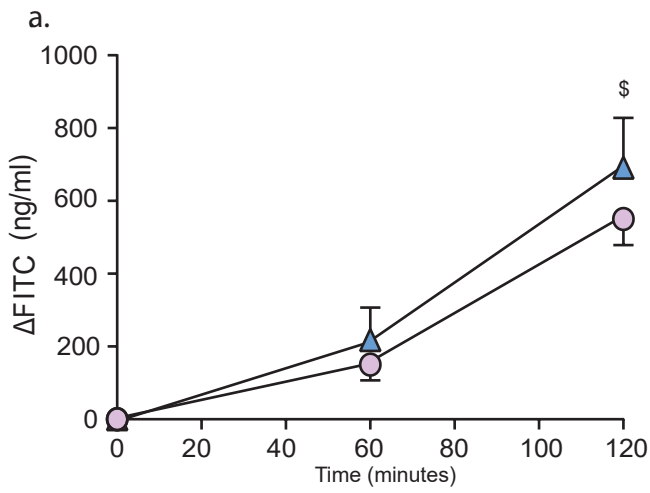


Distal ileum



Proximal colon

