

Figure S1. Immunohistochemistry of the gastroscopy biopsy specimen. The samples were collected on May 26, 2016. Strong expression of CD56 and CgA, weak expression of CK7 and no expression of CK20 and CDX-2 was observed (magnification, x200). CD56, neural cell adhesion molecule 1; CgA1, chromogranin A; CK, cytokeratin; CDX-2, caudal type homeobox 2.

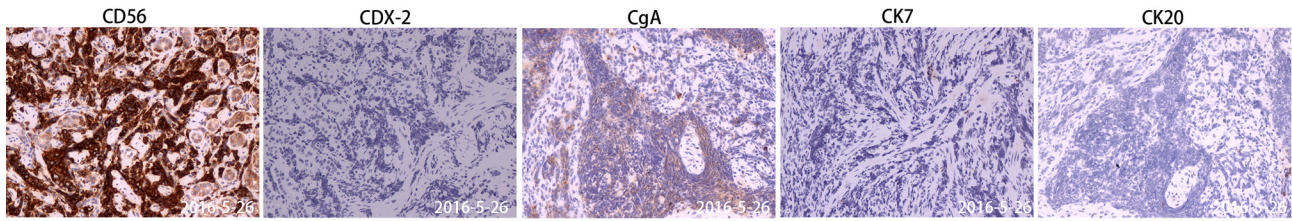


Figure S2. Immunohistochemistry of the cervical lymph node biopsy specimen. The samples were collected on May 30, 2016. Strong expression of CD56, weak expression of CK7 and no expression of CK20 and CDX-2 was observed (magnification, x200). CD56, neural cell adhesion molecule 1; CK, cytokeratin; CDX-2, caudal type homeobox 2.

