

Images in Cardiology: A Rare Coronary Anomaly: Double Right Coronary Artery

OKAN GULEL, M.D., MUSTAFA YAZICI, M.D., KENAN DURNA, M.D., SABRI DEMIRCAN, M.D.

19 Mayıs University, Faculty Of Medicine, Department Of Cardiology, Samsun, Turkey

A 60-year-old man was diagnosed as having an anterior myocardial infarction and was treated with tissue plasminogen activator (tPA). When coronary angiography was performed later to evaluate his coronary anatomy, an interesting finding was found to be present in the right circulation. There were two different right coronary arteries originating from the right sinus of Valsalva with the same ostia (Fig. 1 and 2). In addition,

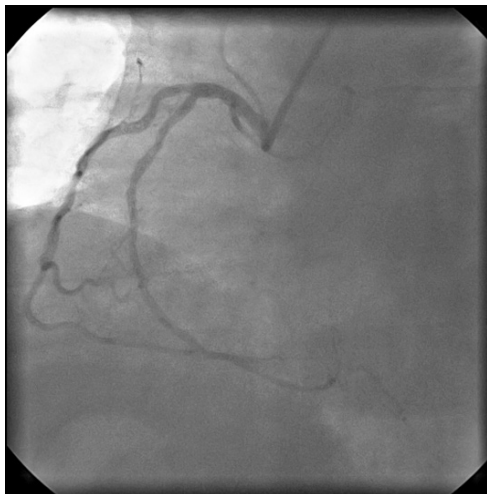

FIG. 1 Two right coronary arteries in left anterior oblique projection during coronary angiography.

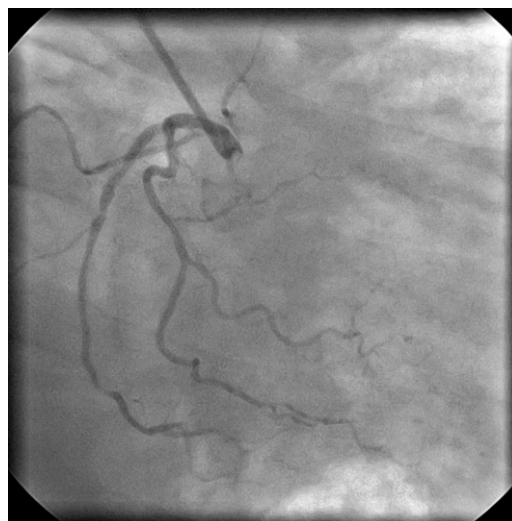


FIG. 2 Two right coronary arteries in right anterior oblique projection during coronary angiography.

one of them was normal, but the other one had atherosclerotic plaques. Right Coronary Artery (RCA) anomalies are rare. RCA arising from left anterior descending coronary artery or from pulmonary artery is sometimes seen.^{1,2} However, double RCA (one normal, one atherosclerotic) with the same ostia is rarely detected.

Address for reprints:
Okan Gulel, M.D.
Universite Lojmanlari
A-Blok No: 7, 55139 Kurupelit
Samsun, Turkey
e-mail: okangulel@hotmail.com

Received: April 25, 2006
Accepted: July 18, 2006

Published online in Wiley InterScience
(www.interscience.wiley.com).
DOI:10.1002/clc.20009
© 2007 Wiley Periodicals, Inc.

References

1. Kobayashi T: Anomalous origin of the right coronary artery from the pulmonary artery. *Ryoikibetsu Shokogun Shirizu* 1996;12:790–792
2. Hughes MM: Anomalous origin of the right coronary artery from the left anterior descending coronary artery. *Cathet Cardiovasc Diagn* 1997;42(3):308–309