

# Single-Photon Emission Computed Tomography Myocardial Perfusion Imaging in the Diagnosis of Left Main Disease

**Address for correspondence:**  
Luis Afonso,  
MD, FACC  
Associate Professor,  
Cardiology Fellowship Program  
Division of Cardiology,  
Wayne State University  
Harper University Hospital,  
Detroit Medical Center,  
8 Brush, 3990 John R  
Detroit, Michigan, 48201  
lafonso@med.wayne.edu

Luis Afonso, MD; Nitin Mahajan, MD

Division of Cardiology (Afonso) and Department of Internal Medicine (Afonso, Mahajan), Detroit Medical Center, Wayne State University School of Medicine, Detroit, Michigan

## ABSTRACT

**Background:** Left main disease (LMD), defined as  $\geq 50\%$  lesion stenosis, occurs in 3% to 5% of patients undergoing catheterization. Limited data on the value of single-photon emission computed tomography (SPECT) imaging for diagnosis of LMD exists.

**Hypothesis:** This study sought to evaluate the diagnostic accuracy of SPECT imaging in the diagnosis of LMD.

**Methods:** A total of 74 consecutive patients with LMD, identified from our catheterization lab database (January 2003–December 2007) with gated exercise (15 patients) or adenosine (59 patients), thallium 201, or Tc-99m SPECT imaging within 6 months of index angiography were included. Group 1 (Gp 1) included 33 patients with isolated LMD. Group 2 (Gp 2) consisted of 41 patients with LMD and 1-vessel disease (6); LMD and 2-vessel disease (24); and LMD and 3-vessel disease (11).

**Results:** Reversible perfusion defects (PD) were absent in 6 (18%) of Gp 1 and 8 (20%) of Gp 2 patients. Among Gp 1 patients, PD in 1-vessel, 2-vessel, 3-vessel distribution were seen in 20 (61%), 5 (15%), and 2 (6%) patients respectively. In comparison, PD in 1-vessel, 2-vessel, 3-vessel distribution were observed in 20 (49%), 12 (29%), and 1 (2%) of Gp 2 patients respectively. Left main (LM) pattern was noted in 6 patients (Gp 1: 2, Gp 2: 4). Transient ischemic dilatation (TID) was encountered in 34 patients (Gp 1: 17, Gp 2: 17) and in 4 patients with normal perfusion scans.

**Conclusions:** These data represent the largest analysis of patients with “isolated” LMD. Approximately 19% of patients with LMD have no reversible PD on SPECT. While LM pattern is rare, 1-vessel distribution PD and TID represent the most frequent SPECT abnormalities.

## Introduction

Left main coronary artery stenosis was first described by James Herrick in a patient with acute myocardial infarction in 1912.<sup>1</sup> Left main disease (LMD) defined as a  $\geq 50\%$  stenosis of this vessel is encountered in 3% to 5% of patients undergoing cardiac catheterization.<sup>2</sup> The inherently high mortality associated with this entity makes the accurate diagnosis of LMD imperative, particularly as timely revascularization confers a definite survival benefit.<sup>3–7</sup>

Single-photon emission computed tomography myocardial perfusion imaging (SPECT-MPI) is a cost-effective method of screening patients with suspected coronary artery disease (CAD).<sup>8</sup> A negative result is associated with a low risk (<1%) of death or nonfatal myocardial infarction and the negative predictive value ranges between 96% to 100%.<sup>9,10</sup> However, data on the diagnostic accuracy of SPECT-MPI in the detection of LMD are sparse.<sup>11,12</sup> We sought to characterize SPECT abnormalities to ascertain the diagnostic sensitivity of SPECT-MPI in patients with LMD.

## Methods

A retrospective review of the cardiac catheterization database at a tertiary academic medical center (January 2003–December 2007) identified 1075 patients with LMD out of a total of 24 998 catheterizations (4.3%). Patients with left bundle branch block, pacemaker, and stress testing to angiography interval of more than 6 months were excluded. From amongst this cohort, only 74 patients who had undergone SPECT-MPI in 6 months preceding the index coronary angiography were selected for further analysis. Using these criteria, 33 patients with isolated LMD (group 1) and 41 patients with LMD in combination with obstructive disease involving the left anterior descending (LAD), left circumflex (LCX), or right coronary artery (RCA) territories (group 2) qualified for final analysis.

Demographics and risk factor profile (age, gender, diabetes mellitus as per American Diabetic Association criteria, hypercholesterolemia per National Cholesterol Education Program screening criteria, hypertension per Joint National Committee 7 criteria, cigarette smoking, and prior history of myocardial infarction) were abstracted.

Catheterization data included severity of LMD ( $\geq 50\%$ ), severity of stenosis ( $\geq 70\%$  stenosis) distal to left main (LM). Lesion severity was ascertained by the attending cardiologist performing angiography. Patients with LMD and obstructive CAD distal to LM were stratified as 1-vessel, 2-vessel, or 3-vessel disease based on the number of coronaries involved.

All patients had gated exercise or adenosine, thallium 201, or Tc-99m-sestamibi SPECT-MPI performed in the 6 months preceding angiography. Per institutional protocol, nitrates,  $\beta$ -blockers, and caffeine-containing beverages or products (including chocolates) were withheld 24 hours prior to adenosine and exercise stress testing. No attenuation or scatter correction software was employed. For localization of anatomic disease and inducible reversible perfusion defects (PD), the distribution of LAD was considered to be the anterolateral wall, anteroseptal wall, and interventricular septum. The distributions of the right coronary (RCA) and left circumflex (LCX) were considered to be represented by the inferior, inferoseptal, and inferolateral or lateral walls respectively. The location (coronary distribution) of reversible PD was used to categorize as 1-vessel, 2-vessel, or 3-vessel PD. The presence of LM pattern (inducible decrease in tracer activity in LAD and LCX distribution) was also recorded.

Ancillary non-perfusion abnormalities included severity of ST deviation during peak stress or recovery ( $\geq 2$  mm ST depression for exercise and  $\geq 1$  mm for adenosine stress),<sup>13</sup> qualitative increased whole lung uptake, transient ischemic dilatation (TID) of left ventricle ( $>1.22$  for exercise or  $>1.36$  for adenosine stress),<sup>14,15</sup> and post stress ejection fraction from gated images. Peak systolic blood pressure of  $<90$  mm Hg during adenosine stress or systolic pressure drop of 20 mm Hg or greater from baseline, during exercise was interpreted as stress induced hypotension.<sup>16</sup>

**Statistical Analysis**

Unless otherwise indicated, data are expressed as the mean value  $\pm$  SD. Statistical analyses were conducted with SPSS ver. 11.5 for windows (SPS Inc., Chicago, IL). Differences among groups were assessed by  $\chi^2$  test for categorical variable and 1-way analysis of variance (ANOVA) for continuous variable. A *P* value  $<.05$  was considered significant.

**Results**

**Study Population**

A total of 74 patients with significant LMD, identified from our catheterization lab database with gated exercise (15) or adenosine (59), thallium-201 or Tc-99m SPECT-MPI were included. All the patients undergoing exercise achieved target endpoints. The predominance of pharmacologic stress tests in this study is more a reflection of accompanying co-morbidities precluding use of exercise as a stress

modality rather than selection bias. Group 1 (Gp 1) included 33 patients with isolated LMD. Group 2 (Gp 2) consisted of 41 patients with LMD and 1-vessel disease (6), LMD and 2-vessel disease (24), and LMD and 3-vessel disease (11). Baseline characteristics are detailed in Table 1. No patient presented with ST-elevation myocardial infarction. One-third of patients were diabetic and reported a history of smoking, while the large majority ( $>65\%$ ) were both hypertensive and dyslipidemic. ST depression of 1–2 mm was more prevalent in group 2. No differences in the presence of TID, lung uptake, or hypotension were observed between groups. Similarly, no difference in the distribution of fixed deficits from prior myocardial infarction was seen among 7 patients in Gp 1 (RCA: 4; LAD territory: 3) and 11 patients in Gp 2 (RCA: 5; LAD territory: 6).

**Spectrum of Gated SPECT-MPI abnormalities in LMD**

The distributions of reversible PD are shown in Figure 1. With the exception of patients with LMD and 3-vessel disease, normal or mildly abnormal reversible PD were present in half of the patients. LM pattern was seen in 6 patients (Gp 1: 2, Gp 2: 4). Absence of reversible PD was observed in 6 (18%) of Gp 1 and 8 (20%) of Gp 2 patients.

Among Gp 1 patients, PD in 1-vessel, 2-vessel, and 3-vessel distribution were seen in 20 (61%), 5 (15%), and 2 (6%) patients respectively. In comparison, reversible PD in 1-vessel, 2-vessel, and 3-vessel distribution were observed in 20 (49%), 12 (29%), and 1 (2%) of Gp 2 patients respectively. The frequency of TID was relatively high, but reduced ejection fraction, lung uptake, and stress induced hypotension were uncommon. TID was encountered in

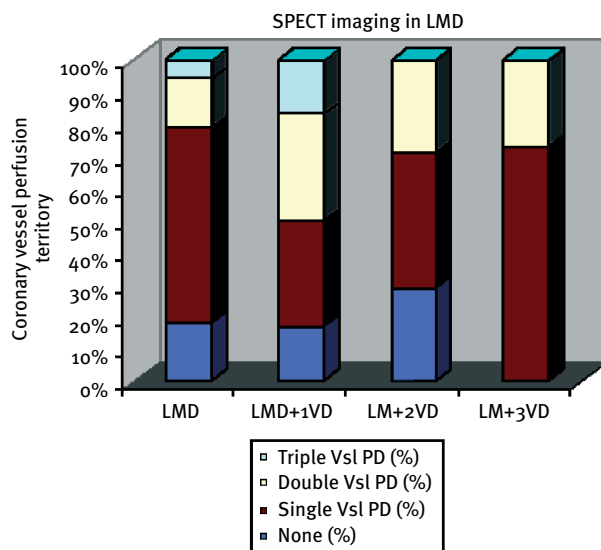


Figure 1. Bar graphs depicting presence and extent of perfusion deficits in various subgroups of left main disease. Abbreviations: LMD, left main disease; VD, vessel disease; Vsl PD, vessel perfusion defect.

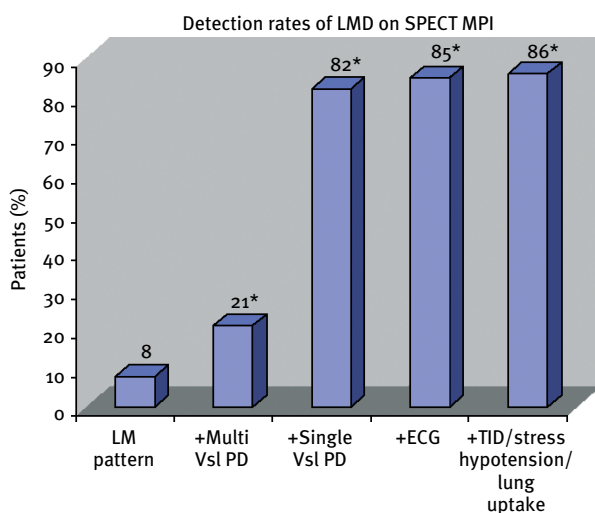
**Table 1. Demographic and Clinical Profile of Study Patients**

	Variable	All Patients (n = 74)	Group 1 (n = 33)	Group 2 (n = 41)	P Value
1	Age (in years)	64 ± 12	63 ± 10	64 ± 12	NS
2	Males (%)	38 (51%)	14 (42%)	24(58%)	NS
3	Risk factors				
	Diabetes mellitus (%)	27 (36%)	12 (35%)	15(37%)	NS
	Hypertension (%)	57 (77%)	23 (71%)	34(84%)	NS
	Hypercholesterolemia (%)	52 (70%)	25 (77%)	27(65%)	NS
	Family history (%)	30 (41%)	13 (39%)	17(42%)	NS
	Smoking	25 (34%)	9 (29%)	16(37%)	NS
4	Ejection fraction (%) <sup>a</sup>	50 ± 12	49 ± 10	52 ± 12	NS
5	Prior MI	18 (24%)	7 (20%)	11(27%)	NS
6	Angina	28 (38%)	14 (43%)	14(34%)	NS
7	Others (syncope, dyspnea)	7 (9%)	3 (9%)	4 (10%)	NS

**Abbreviations:** MI = myocardial infarction; NS = not significant; SPECT = single-photon emission computed tomography.

Medications (prior to stress test): nitrates, 20 (27%); aspirin, 28 (38%); β-blockers, 33 (45%); angiotensin-converting enzyme inhibitors, 31 (42%); statins, 33 (45%).

<sup>a</sup> gated SPECT derived ejection fraction.



**Figure 2.** Detection rates of LMD in study patients by perfusion and nonperfusion variables on SPECT-MPI. **Abbreviations:** LMD, left main disease; TID, transient ischemic deficit; VD, vessel disease; Vsl PD, vessel perfusion defect. <sup>a</sup>*P* < .05.

34 patients (Gp 1: 17; Gp 2: 17) and in only 4 (29%) patients with normal perfusion scans. The combination of perfusion and nonperfusion variables improved the detection of LMD patients compared with perfusion alone (see Figure 2). These results are consistent with those

of a prior study showing incremental value of adding nonperfusion variables.<sup>11</sup>

The presence of fixed defects did not add any incremental value to the identification of patients. There was no significant difference in the pattern of PD when perfusion data was analyzed according to severity of LM stenosis (50%-70% vs >70% stenosis), cohorts with and without RCA involvement, or type of stressor used (exercise vs adenosine).

### Discussion

Our findings may be summarized as follows: first, approximately 19% of patients with significant LMD have no discernible reversible PD on SPECT-MPI. Second, the only perfusion abnormality encountered in roughly half of the study patients with LMD (~55%) was reversible ischemia in a single coronary territory distribution. Third, the intuitively expected LM pattern is apparent in a minority of patients with LMD. Finally, the spectrum of SPECT-MPI abnormalities described in patients with “isolated” LMD represents the only data of its kind in the literature.

### Comparative Data on SPECT-MPI and LMD

Although LMD is relatively uncommon, accurate diagnosis is crucial due to the survival benefit conferred by timely revascularization.<sup>17</sup> A few small studies have suggested that SPECT-MPI alone has a low sensitivity in detecting

LMD.<sup>11,12,18</sup> In early reports, Nygaard et al indicated that only 14% of 43 patients with LMD showed LM pattern, while 67% demonstrated multivessel perfusion deficits.<sup>19</sup> In contrast, Rehn et al reported abnormal scintigrams in 92% of 24 patients with LMD, while LM pattern was apparent in only 13% of patients.<sup>20</sup> Subsequently, Duvernoy et al reported a noteworthy improvement in sensitivity of LM pattern (64% vs 7%) with an in-house developed technique of attenuation correction.<sup>12</sup> More recently, Berman et al<sup>11</sup> reported visual perfusion abnormalities in 56% (qualitatively) and 59% (quantitatively) of 101 patients with LMD who underwent gated exercise or adenosine SPECT-MPI. Absence of any reversible PD, qualitatively or quantitatively was observed in 13% and 15% of patients respectively. Addition of non-perfusion variables, particularly TID, enabled the detection of 83% of LMD as being at high-risk. Isolated LMD was infrequent in the above study (11%).<sup>11</sup> Our findings are novel and indicate that the limitations of SPECT-MPI extend to those with isolated LMD as well.

#### Underestimation of LMD with SPECT-MPI: Proposed Mechanisms and Clinical Implications

In contrast to the widely acknowledged underestimation of the extent of CAD in patients with 3-vessel disease, the limitations of SPECT-MPI in the diagnosis of LMD are not well recognized. Indeed the published literature suggests that the classic LM pattern is observed in only 5% to 13% of patients with LMD.<sup>19–21</sup> While a host of factors including ingestion of caffeine-containing products or aminophylline, antianginal therapy, and attenuation from motion, soft tissue, or diaphragmatic attenuation have been implicated in the underestimation of high risk CAD by SPECT-MPI, the precise mechanism leading to the under detection of LMD remains obscure.<sup>22</sup> Plateauing of tracer uptake at high flow rates, leading to masking of disparities in coronary flow reserve, particularly if vasodilator stress is employed and the phenomenon of balanced ischemia and the inability to quantify absolute coronary flow remain the Achilles' heel of this technique.<sup>18,23</sup> Another hypothetical mechanism proposed suggests that the inferior wall, being subject to a greater degree of soft-tissue attenuation, particularly in men could lead to an apparent balanced reduction pattern. Nevertheless, in the best case scenario, despite the use of a variety of nonperfusion parameters up to 17% of patients with LMD go undetected.<sup>12,21,22,24,25</sup> It is unclear from the existing literature if the type of stressor (exercise or pharmacologic) influences the diagnostic sensitivity of SPECT-MPI for LMD.

Regardless, it is important that clinicians are aware of limitations of SPECT-MPI in the detection of high risk CAD.<sup>26</sup> Specifically, the absence of reversible PD or the presence of only single abnormal coronary territory PD does not always imply a benign prognosis, but ought to prompt further testing such as angiography, particularly

when SPECT results are incongruent with the clinical suspicion of the extent of CAD.

#### Study Limitations

Despite suffering from drawbacks of a retrospective analysis, our study likely reflects the nonclinical trial, real-world nuclear cardiology practice experience across the United States. First, the inherent drawback of a comparison between a noninvasive test that addresses physiologic relevance of a stenosis to one that defines anatomic lesion severity (such as reference coronary angiography) needs to be recognized.<sup>27</sup> Despite this concern, invasive coronary angiography remains the gold standard for the clinical diagnosis and assessment of the extent and severity of CAD. Perhaps, the more pressing limitation of studies of this nature are their inherent vulnerability to referral bias. In fact, it is quite likely that referral bias overestimates the sensitivity of SPECT-MPI in the detection of LMD. Specifically, it is unclear how many patients with apparently normal scans or minor abnormalities have LMD, but tend to remain unrecognized, because the severity of stress abnormality fails to pass the clinical threshold that typically drives the decision for cardiac catheterization. Most of the aforementioned biases could be overcome through the design of a large, prospective, case-controlled trial where patients with a high degree of suspicion of CAD underwent cardiac catheterization (along with comprehensive anatomic and physiologic assessment of lesion severity in all participants) regardless of the results of SPECT-MPI.

Because our data was collected from a tertiary medical center where quantitative coronary angiography is not routinely performed, it is possible that observer variability may have led to an overestimation of LM lesion severity. Even though all patients studied had stress testing done within 6 months preceding the index catheterization, it is conceivable that a small percentage could have had an interim progression of atherosclerosis activity or severity, thus jeopardizing correlation of stress results with index cardiac catheterization. In the near future, development of better flow tracers and quantitation techniques, advances in camera technology, adoption of attenuation correction techniques, and the evolution of hybrid techniques (such as PET-CT) that concurrently delineate anatomic extent and physiologic significance of stenotic lesions, may circumvent the limitations of SPECT-MPI in the diagnosis of high risk CAD.<sup>28,29</sup>

#### Conclusion

SPECT-MPI frequently underestimates the magnitude of CAD in the setting of LMD.

#### References

1. Herrick JB. Landmark article (*JAMA*, 1912). Clinical features of sudden obstruction of the coronary arteries. By James B. Herrick. *JAMA*. 1983;250:1757–1765.



- Black A, Cortina R, Bossi I, et al. Unprotected left main coronary artery stenting: correlates of midterm survival and impact of patient selection. *J Am Coll Cardiol.* 2001;37:832–838.
3. Cohen MV, Gorlin R. Main left coronary artery disease. Clinical experience from 1964–1974. *Circulation.* 1975;52:275–285.
  4. Yusuf S, Zucker D, Peduzzi P, et al. Effect of coronary artery bypass graft surgery on survival: overview of 10-year results from randomised trials by the Coronary Artery Bypass Graft Surgery Trialists Collaboration. *Lancet.* 1994;344:563–570.
  5. McConahay DR, Killen DA, McCallister BD, et al. Coronary artery bypass surgery for left main coronary artery disease. *Am J Cardiol.* 1976;37:885–889.
  6. Campeau L, Corbara F, Crochet D, Petitclerc R. Left main coronary artery stenosis: the influence of aortocoronary bypass surgery on survival. *Circulation.* 1978;57:1111–1115.
  7. Killen DA, Reed WA, Kindred L, McConahay DR, Arnold M. Surgical therapy for left main coronary artery disease. *J Thorac Cardiovasc Surg.* 1980;80:255–261.
  8. Hachamovitch R, Hayes SW, Friedman JD, Cohen I, Berman DS. Stress myocardial perfusion single-photon emission computed tomography is clinically effective and cost effective in risk stratification of patients with a high likelihood of coronary artery disease (CAD) but no known CAD. *J Am Coll Cardiol.* 2004;43:200–208.
  9. Gibbons RJ, Abrams J, Chatterjee K, et al. ACC/AHA 2002 guideline update for the management of patients with chronic stable angina—summary article: a report of the American College of Cardiology/American Heart Association Task Force on practice guidelines (Committee on the Management of Patients With Chronic Stable Angina). *J Am Coll Cardiol.* 2003;41:159–168.
  10. Iskander S, Iskandrian AE. Risk assessment using single-photon emission computed tomographic technetium-99m sestamibi imaging. *J Am Coll Cardiol.* 1998;32:57–62.
  11. Berman DS, Kang X, Slomka PJ, et al. Underestimation of extent of ischemia by gated SPECT myocardial perfusion imaging in patients with left main coronary artery disease. *J Nucl Cardiol.* 2007;14:521–528.
  12. Duvernoy CS, Ficaro EP, Karabajakian MZ, Rose PA, Corbett JR. Improved detection of left main coronary artery disease with attenuation corrected SPECT. *J Nucl Cardiol.* 2000;7:639–648.
  13. Yap LB, Arshad W, Jain A, Kurbaan AS, Garvie NW. Significance of ST depression during exercise treadmill stress and adenosine infusion myocardial perfusion imaging. *Int J Cardiovasc Imaging.* 2005;21:253–258.
  14. Mazzanti M, Germano G, Kiat H, et al. Identification of severe and extensive coronary artery disease by automatic measurement of transient ischemic dilatation of the left ventricle in dual-isotope myocardial perfusion SPECT. *J Am Coll Cardiol.* 1996;27:1612–1620.
  15. Abidov A, Bax JJ, Hayes SW, et al. Integration of automatically measured transient ischemic dilatation ratio into interpretation of adenosine stress myocardial perfusion SPECT for detection of severe and extensive CAD. *J Nucl Med.* 2004;45:1999–2007.
  16. Abidov A, Hachamovitch R, Hayes SW, et al. Prognostic impact of hemodynamic response to adenosine in patients older than age 55 years undergoing vasodilator stress myocardial perfusion study. *Circulation.* 2003;107:2894–2899.
  17. Caracciolo EA, Davis KB, Sopko G, et al. Comparison of surgical and medical group survival in patients with left main coronary artery disease. Long-term CASS experience. *Circulation.* 1995;91:2325–2334.
  18. Lima RS, Watson DD, Goode AR, et al. Incremental value of combined perfusion and function over perfusion alone by gated SPECT myocardial perfusion imaging for detection of severe three-vessel coronary artery disease. *J Am Coll Cardiol.* 2003;42:64–70.
  19. Nygaard TW, Gibson RS, Ryan JM, et al. Prevalence of high-risk thallium-201 scintigraphic findings in left main coronary artery stenosis: comparison with patients with multiple- and single-vessel coronary artery disease. *Am J Cardiol.* 1984;53:462–469.
  20. Rehn T, Griffith LS, Achuff SC, et al. Exercise thallium-201 myocardial imaging in left main coronary artery disease: sensitive but not specific. *Am J Cardiol.* 1981;48:217–223.
  21. Wakasugi S, Shibata N, Kobayashi T, et al. Specific perfusion pattern in stress 201Tl myocardial scintigraphy of left main coronary artery disease. *Eur J Nucl Med.* 1986;12:369–374.
  22. Travin M. Is it possible for myocardial perfusion imaging to avoid missing any patients with high-risk coronary disease? *J Nucl Cardiol.* 2007;14:492–496.
  23. Aarnoudse WH, Botman KJ, Pijls NH. False-negative myocardial scintigraphy in balanced three-vessel disease, revealed by coronary pressure measurement. *Int J Cardiovasc Intervent.* 2003;5:67–71.
  24. Kurata C, Tawarahara K, Taguchi T, et al. Lung thallium-201 uptake during exercise emission computed tomography. *J Nucl Med.* 1991;32:417–423.
  25. Maddahi J, Abdulla A, Garcia EV, Swan HJ, Berman DS. Non invasive identification of left main and triple vessel coronary artery disease: improved accuracy using quantitative analysis of regional myocardial stress distribution and washout of thallium-201. *J Am Coll Cardiol.* 1986;7:53–60.
  26. Kwok JM, Christian TF, Miller TD, Hodge DO, Gibbons RJ. Identification of severe coronary artery disease in patients with a single abnormal coronary territory on exercise thallium-201 imaging: the importance of clinical and exercise variables. *J Am Coll Cardiol.* 2000;35:335–344.
  27. White CW, Wright CB, Doty DB, et al. Does visual interpretation of the coronary arteriogram predict the physiologic importance of a coronary stenosis? *N Engl J Med.* 1984;310:819–824.
  28. Sampson UK, Dorbala S, Limaye A, Kwong R, Di Carli MF. Diagnostic accuracy of rubidium-82 myocardial perfusion imaging with hybrid positron emission tomography/computed tomography in the detection of coronary artery disease. *J Am Coll Cardiol.* 2007;49:1052–1058.
  29. Di Carli MF, Dorbala S, Meserve J, et al. Clinical myocardial perfusion PET/CT. *J Nucl Med.* 2007;48:783–793.