

Figure

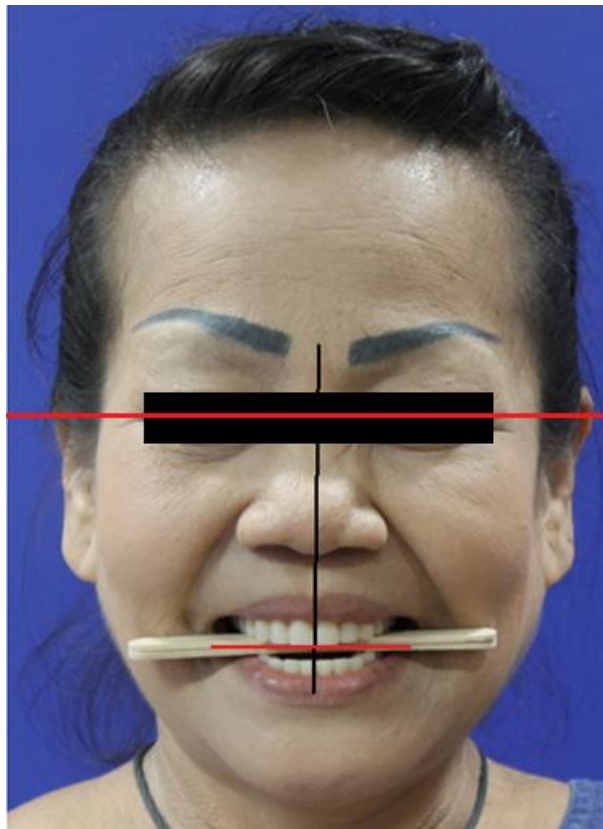


Figure 1: Parallelism between the interpupillary line and incisal edge of the maxillary central incisors (red lines); Coincidence between the facial and dental midlines (black line).