

SUPPLEMENTAL MATERIAL

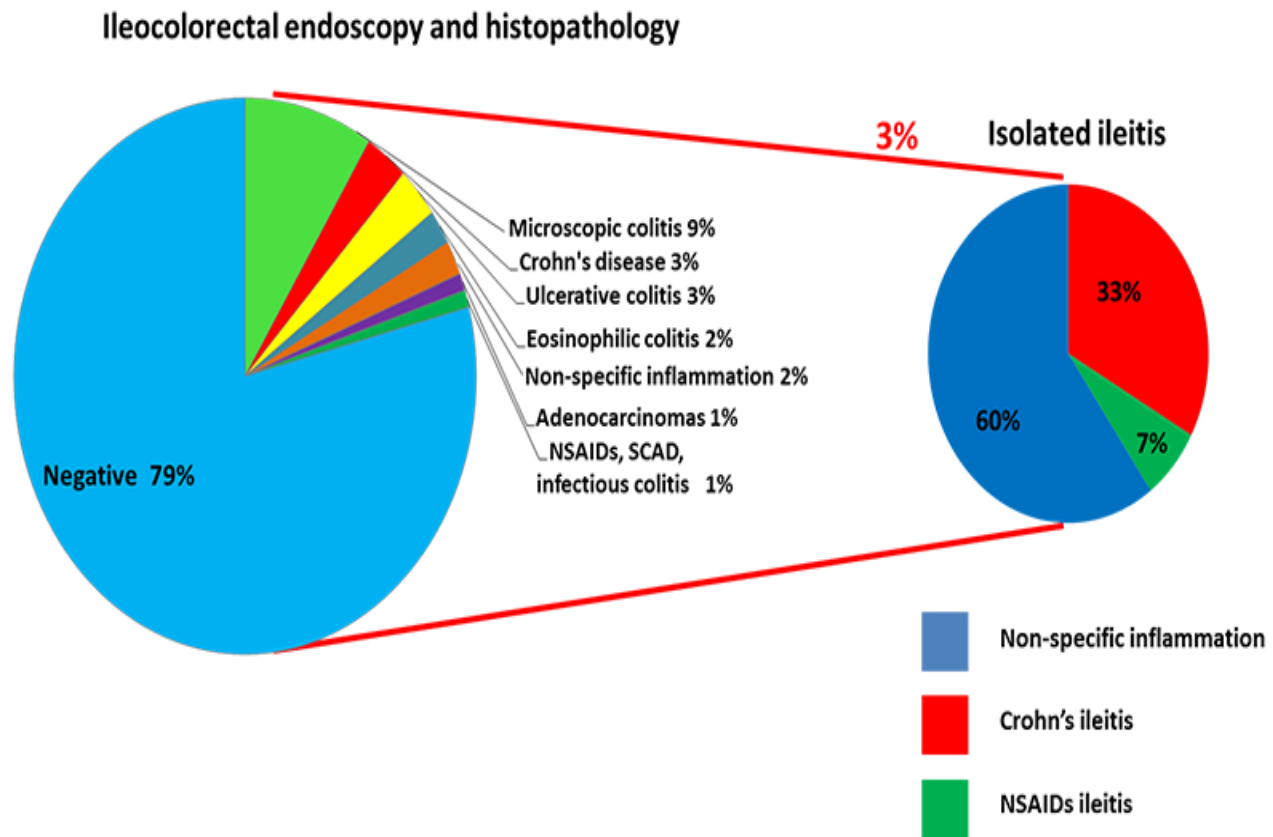


Figure 1: Diagnostic definition based on ileocolorectal endoscopy and histo-pathology in patients with chronic non-bloody diarrhea of unknown origin. LNH, lymphoid nodular hyperplasia; NSAIDs, Non-Steroidal Anti-Inflammatory Drugs.

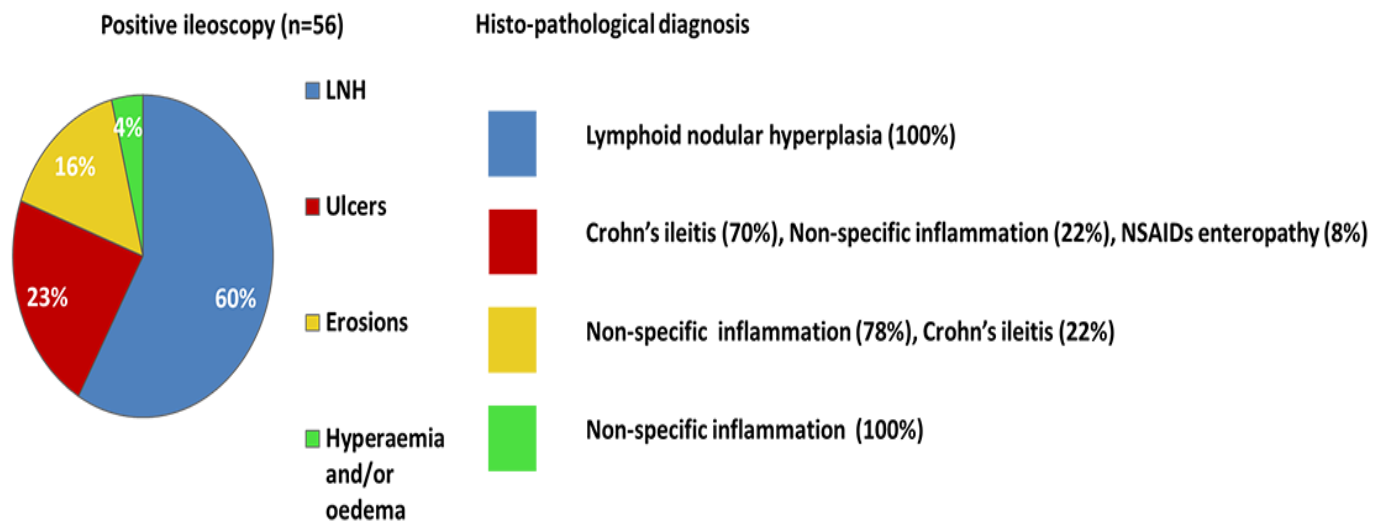


Figure 2. Terminal ileum endoscopic and histo-pathological assessment in patients with chronic non-bloody diarrhea of unknown origin. LNH, lymphoid nodular hyperplasia; NSAIDs, Non-Steroidal Anti-Inflammatory Drugs.