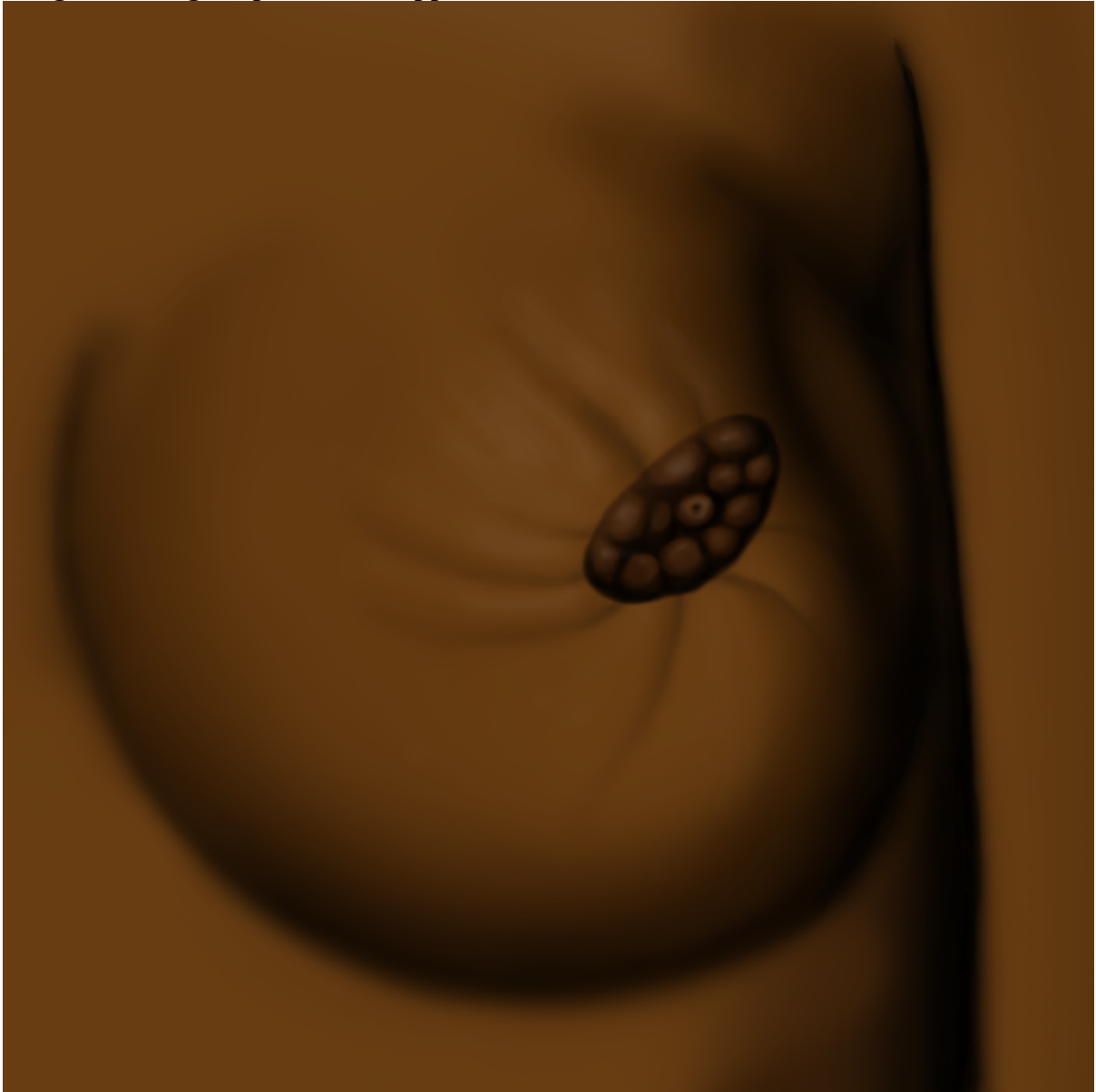
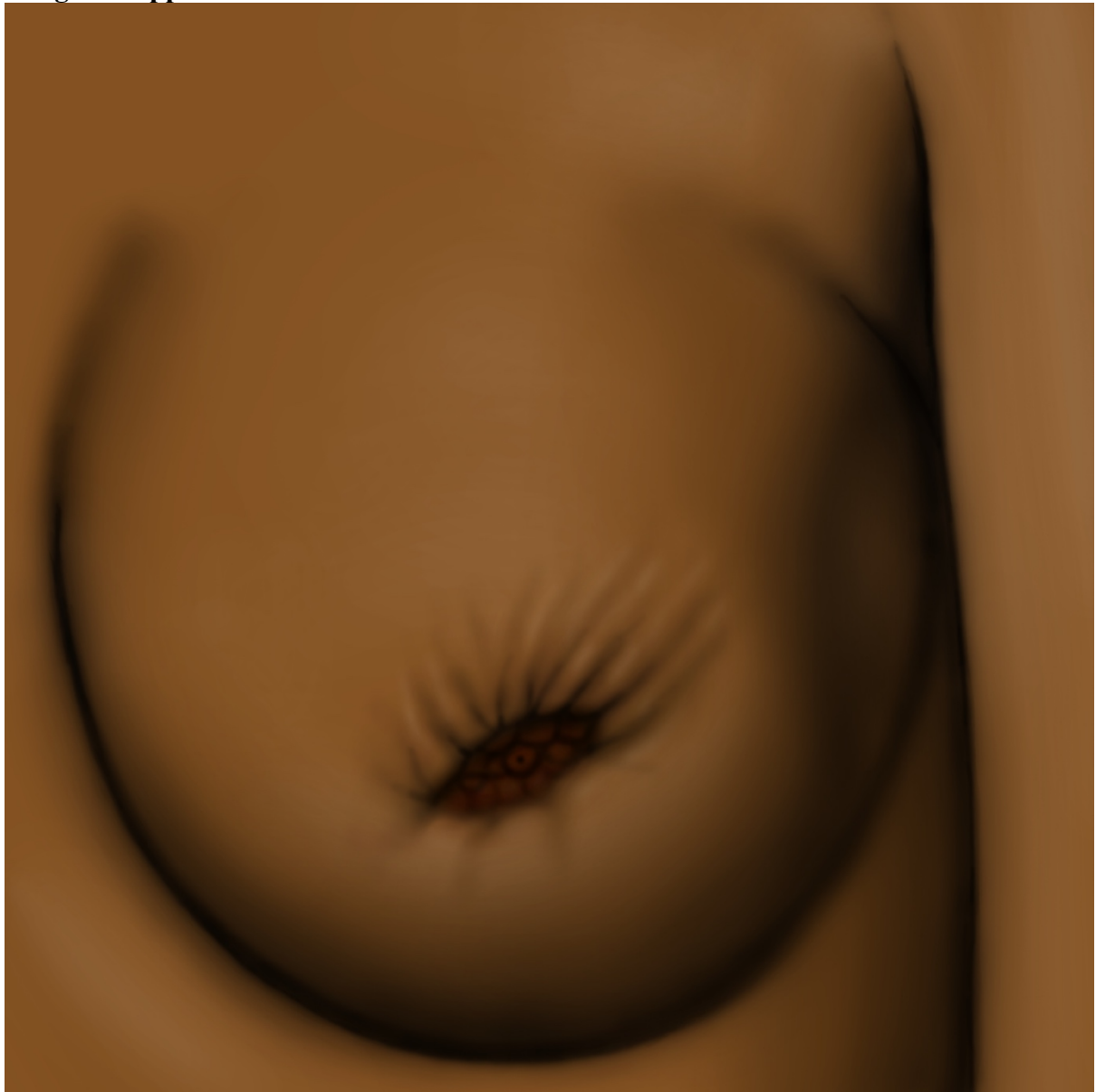

**Image 1: Change in position of nipple**



**Images by Donovan Ward as commissioned by Dr Lydia Cairncross, Grootte Schuur Hospital Breast Clinic, Cape Town, South Africa**

**Image 2: Nipple retraction**



**Images by Donovan Ward as commissioned by Dr Lydia Cairncross, Grootte Schuur Hospital Breast Clinic, Cape Town, South Africa**

**Image 3: Orange peel appearance of skin**



**Images by Donovan Ward as commissioned by Dr Lydia Cairncross, Grootte Schuur Hospital Breast Clinic, Cape Town, South Africa**