

Supplemental material

Efficacy of TIMOLOL nasal spray as a treatment for epistaxis in hereditary hemorrhagic telangiectasia.

A double-blind, randomized, placebo-controlled trial

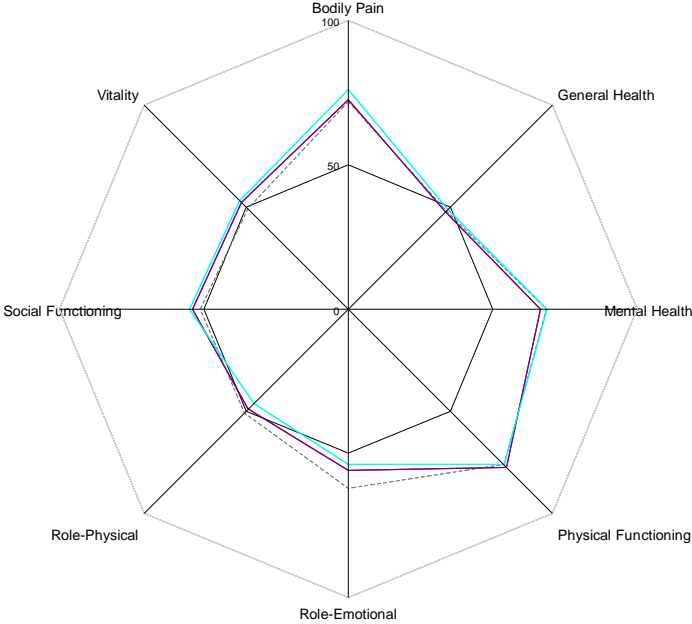
Sophie Dupuis-Girod¹, MD, PhD, Vincent PITIOT², MD, Cyrille BERGEROT⁴, MD, Anne-Emmanuelle Fargeton¹, MsC, Marjolaine Beaudoin¹, MsC, Evelyne Decullier^{5,6}, PhD, Valentine Bréant⁷, Pharm D, Bettina Colombet⁷, Pharm D, Pierre Philouze³, MD, Frédéric Faure², MD, PhD and Jean-Charles Letievant², MD.

1. Hospices Civils de Lyon, Hôpital Femme-Mère-Enfants, Service de Génétique et centre de référence de la maladie de Rendu-Osler, Bron F-69677,
2. Hospices Civils de Lyon, Hôpital E. Herriot, Service d'ORL, Lyon, F-69437
3. Hospices Civils de Lyon, Hôpital de la Croix Rousse, Service d'ORL, Lyon F-69317
4. Hospices Civils de Lyon, Hôpital Louis Pradel, Service de cardiologie, Lyon F-69677
5. Hospices Civils de Lyon, pôle Santé Publique, Lyon, F-69003
6. Université Lyon 1, F-69008
7. Hospices Civils de Lyon, Pharmacie, Hôpital Louis Pradel, Bron, F-69677

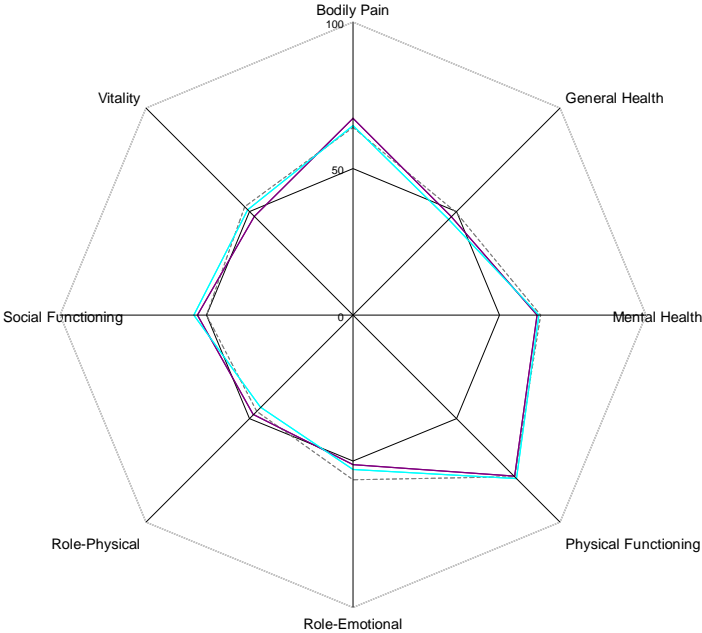
Supplemental material

Figure 3: SF36 score before and after treatment in the placebo (A) and timolol (B) groups.

A



B



- Legends:**
- SF36 at inclusion
 - SF36 at 4 months after inclusion
 - SF36 at 7 months after inclusion

Supplemental material

Figure 4: Epistaxis duration and cardiac frequency in the 2 patients who experienced bradycardia during treatment

