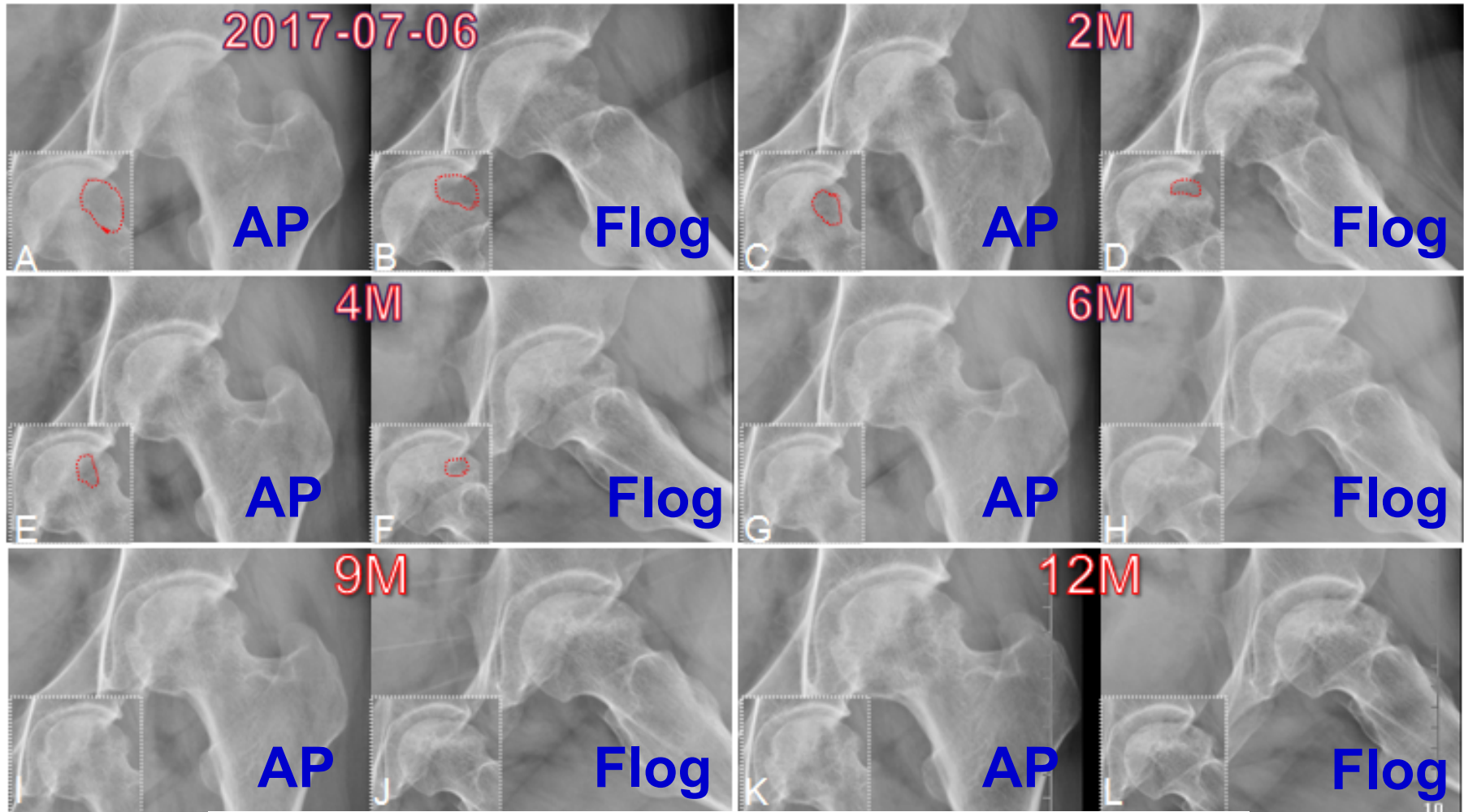


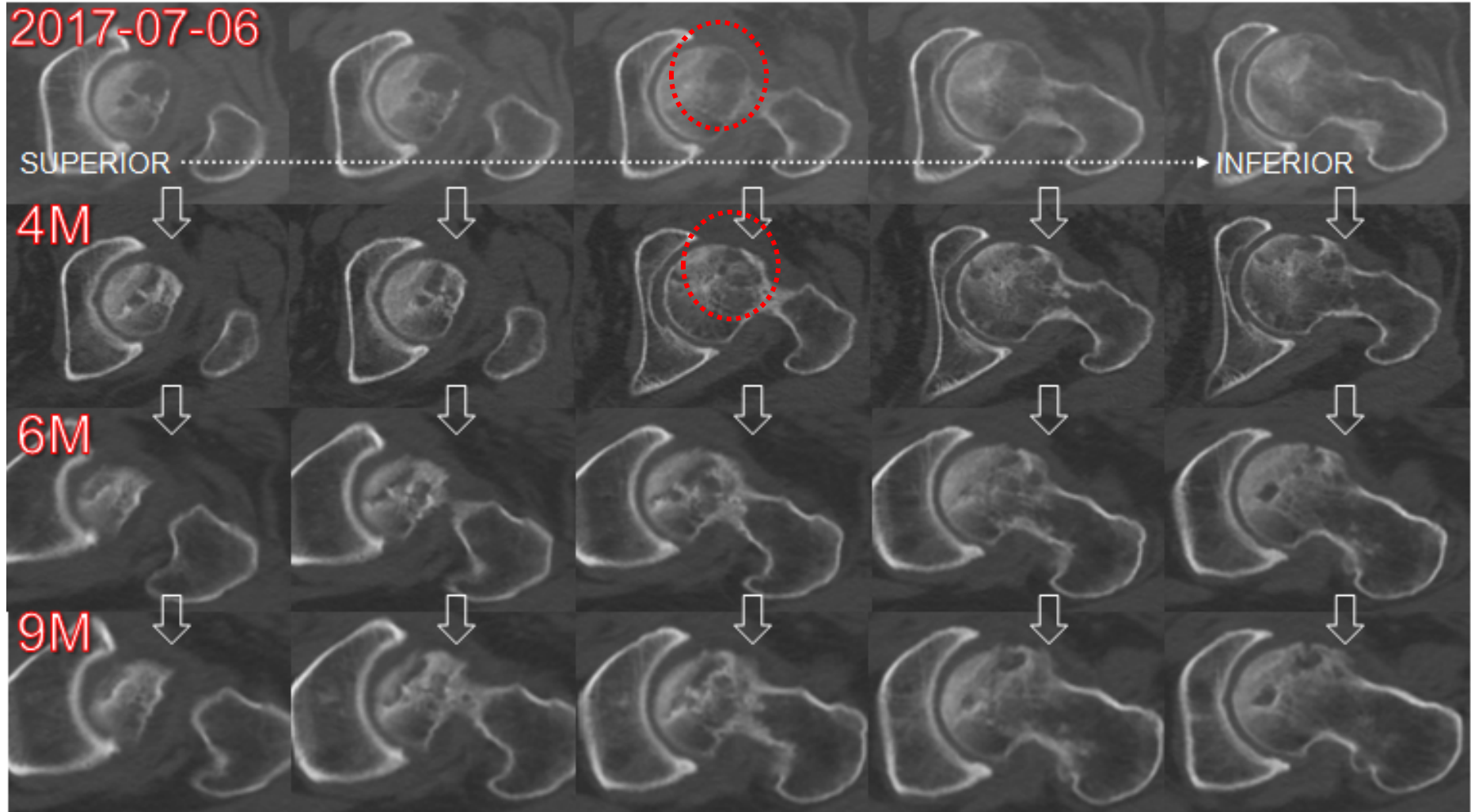
# Case 1

Li, female, 36Y, steroid-ONFH, bone cyst

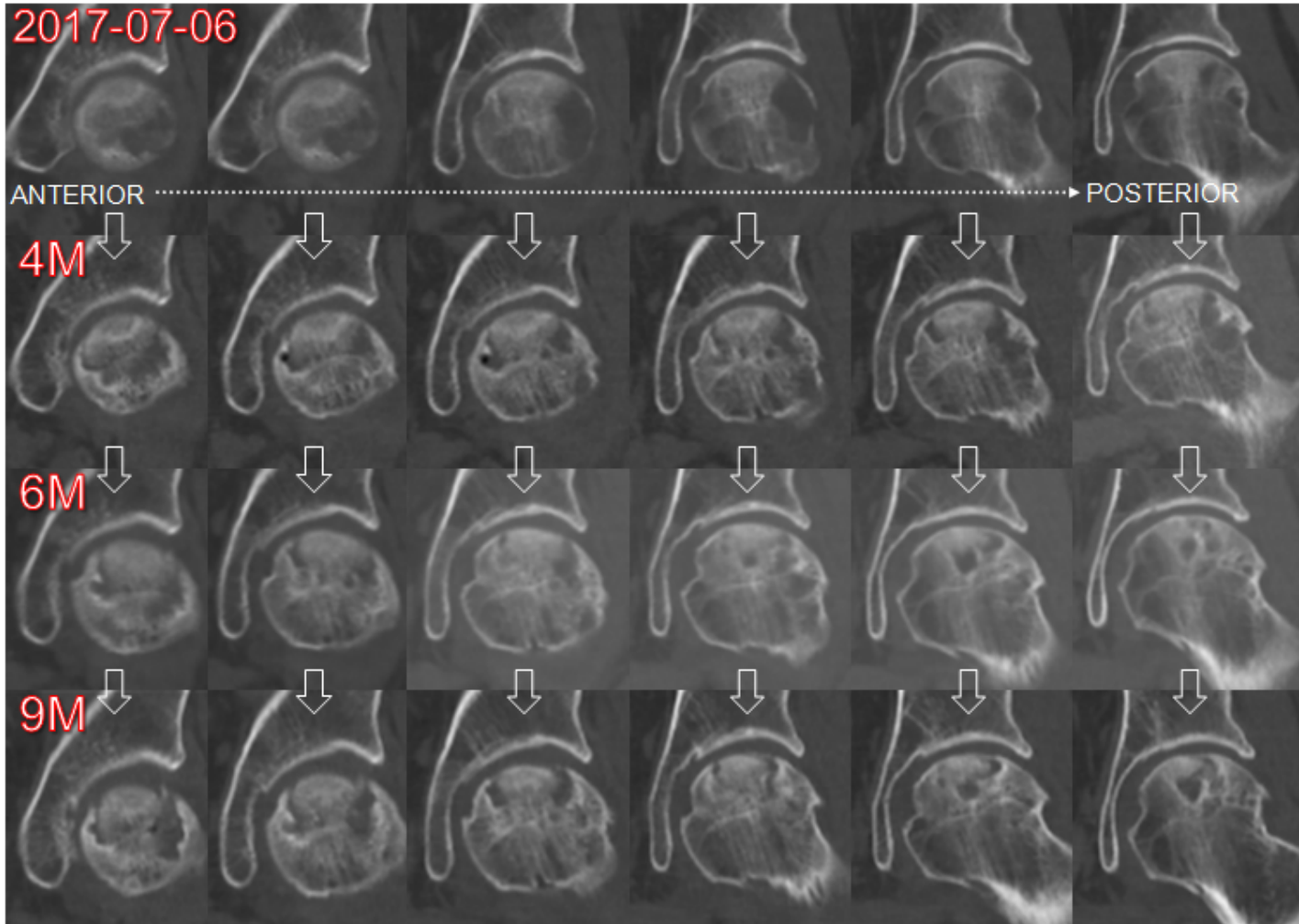


Hip pain for 3M; walking with stick;  
pain release in 2M; weight-bearing walking in 3M

# Li, female, 36Y, steroid-ONFH, bone cyst

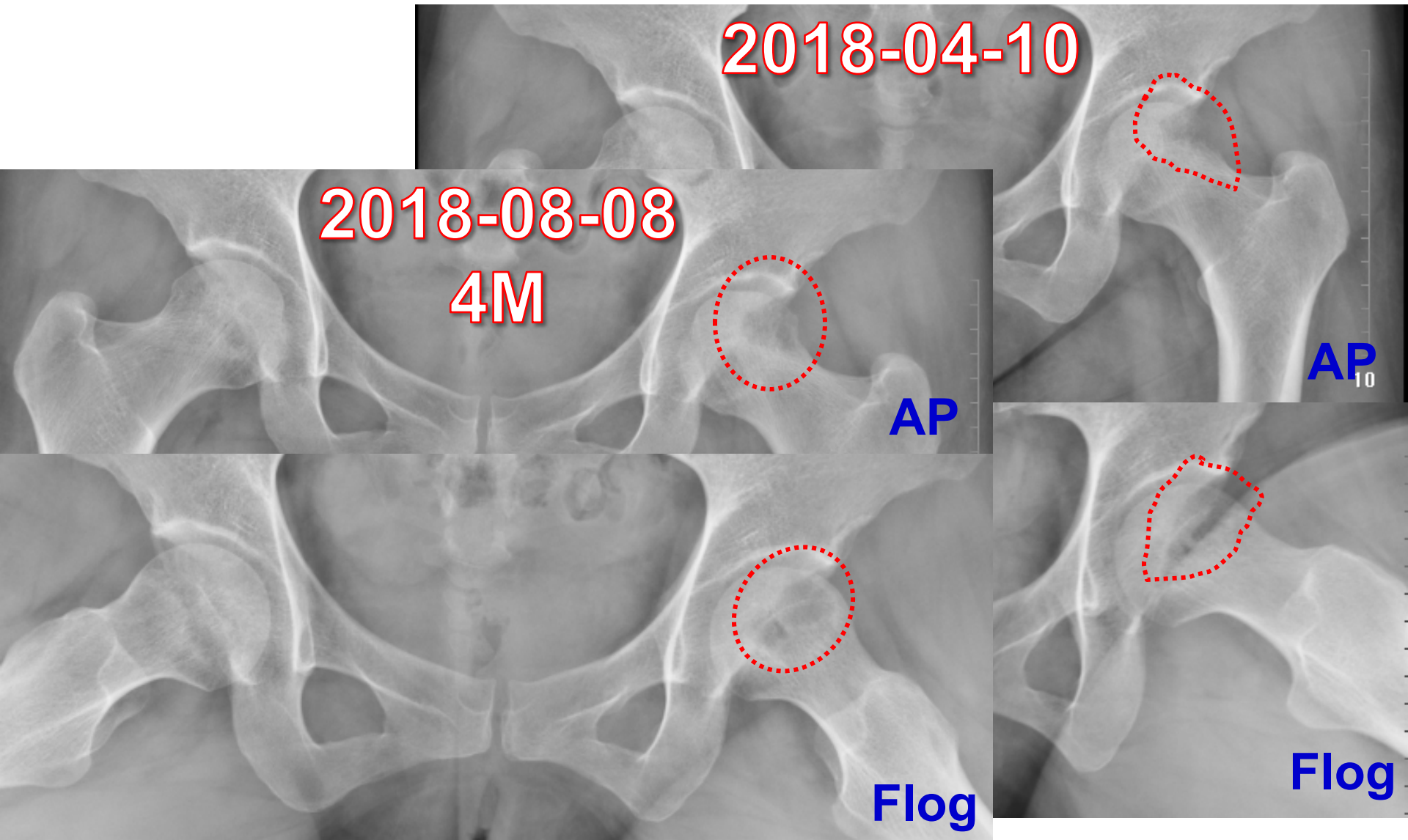


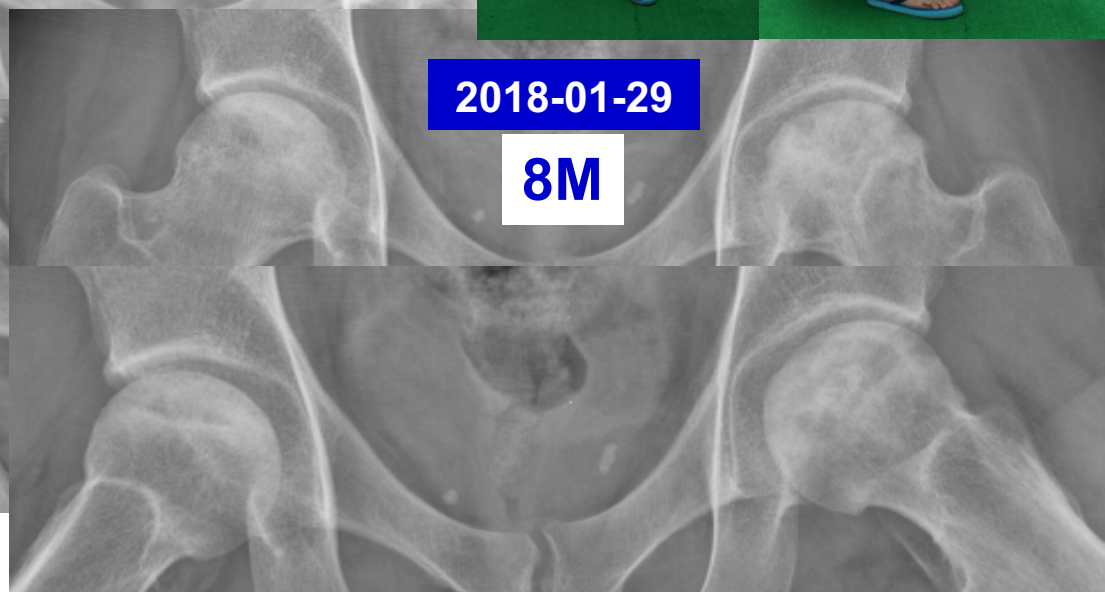
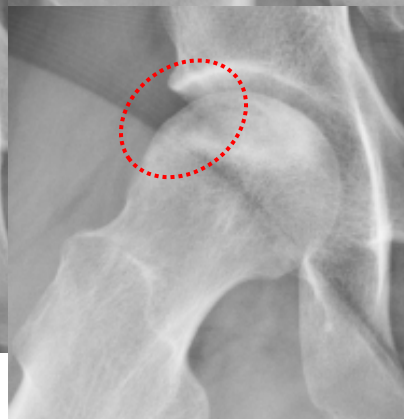
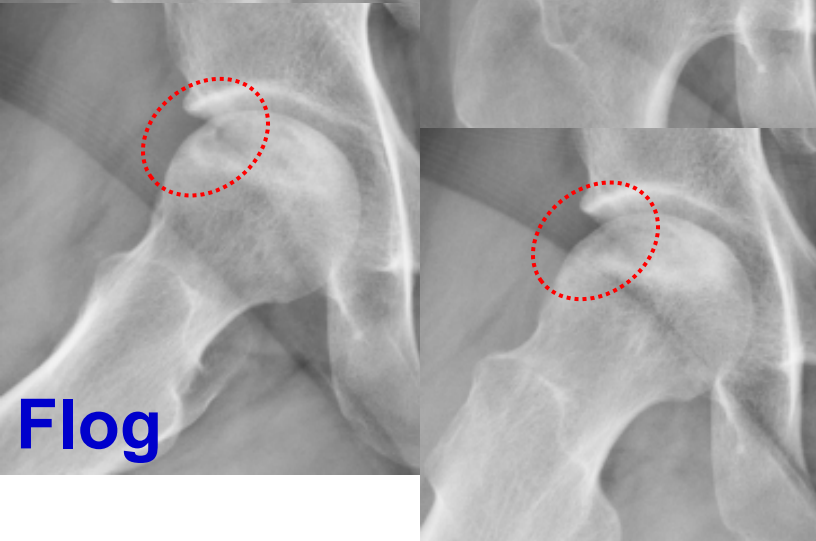
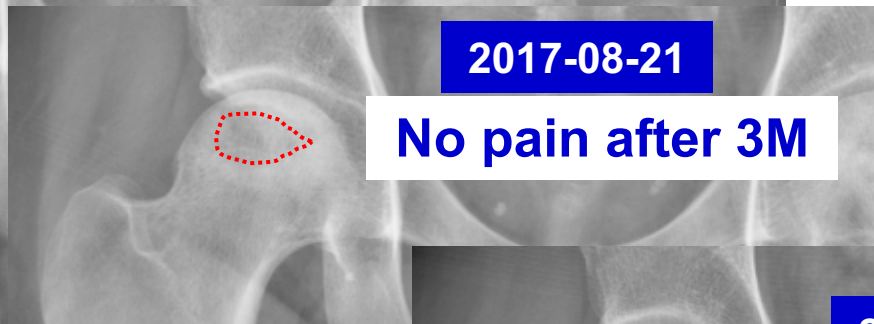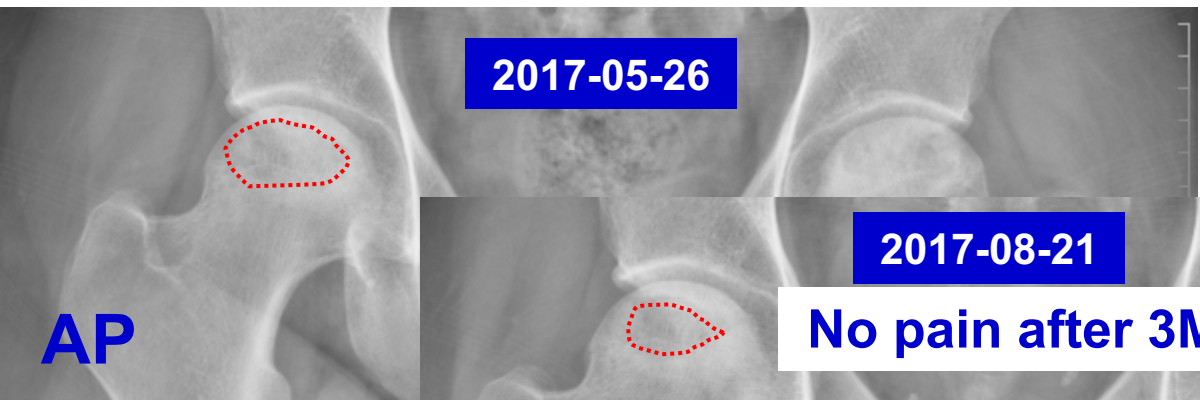
# Li, female, 36Y, steroid-ONFH, bone cyst



# Case 2

Zhou, female, 40Y, steroid-ONFH, bone cyst

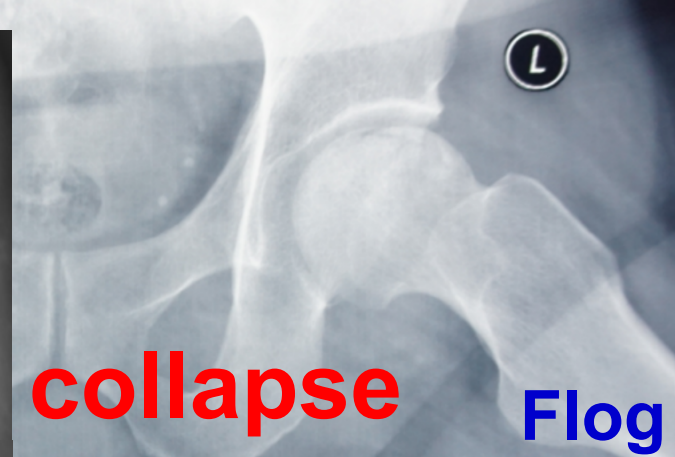
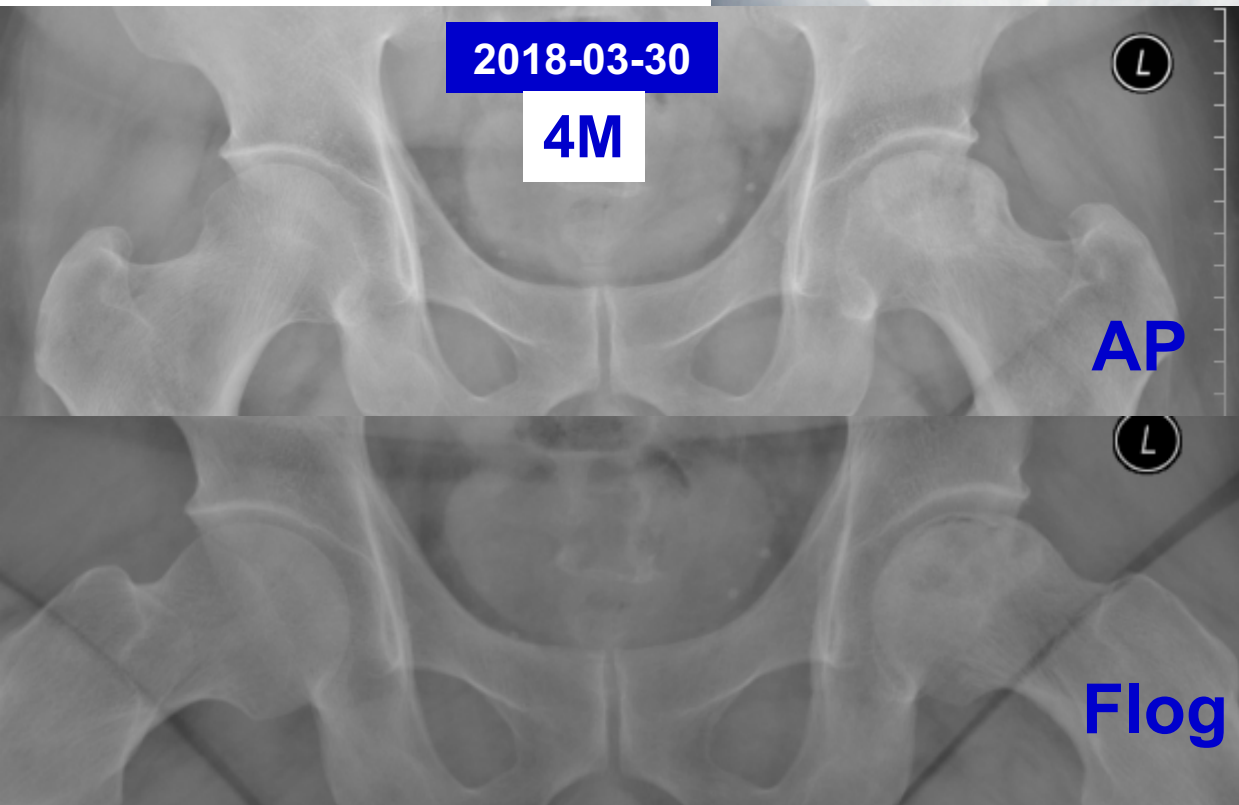
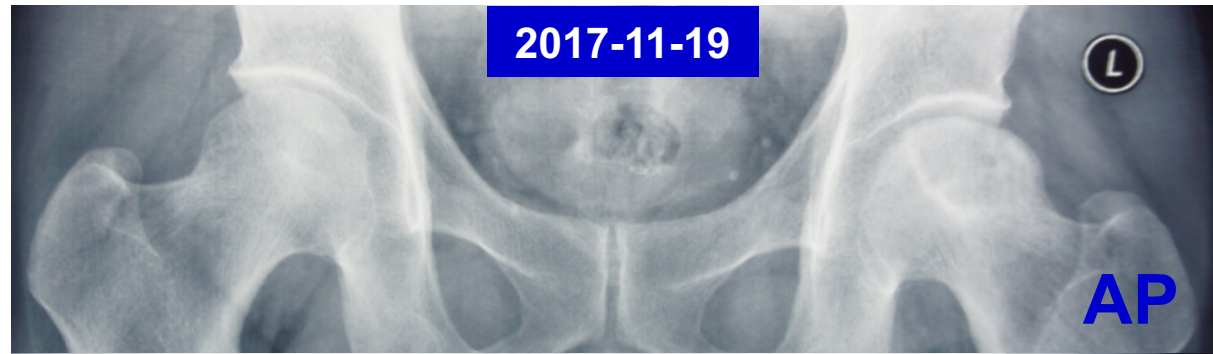



**Right hip pain for half of year, left hip pain for 1 month**

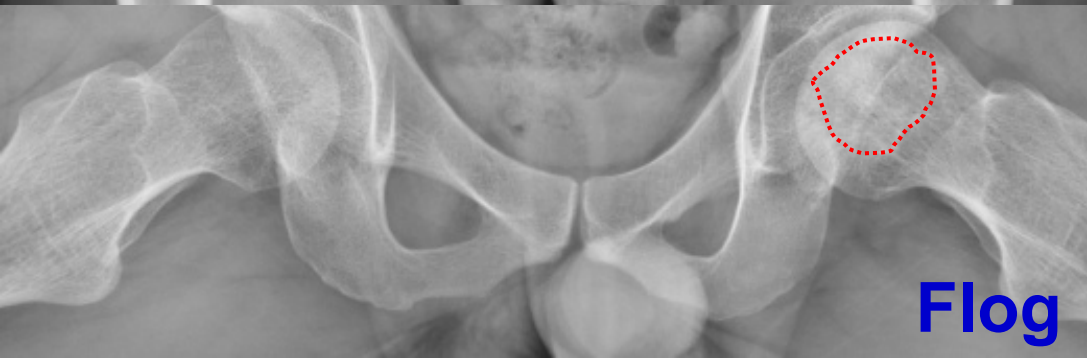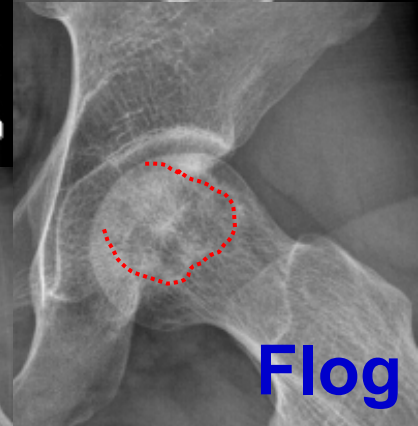
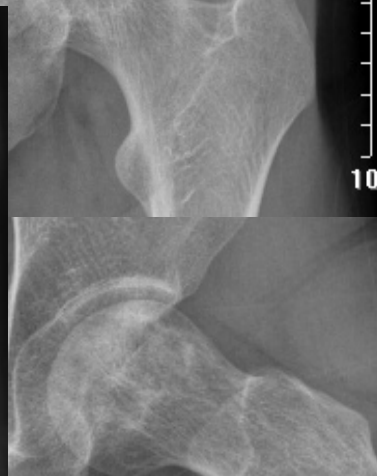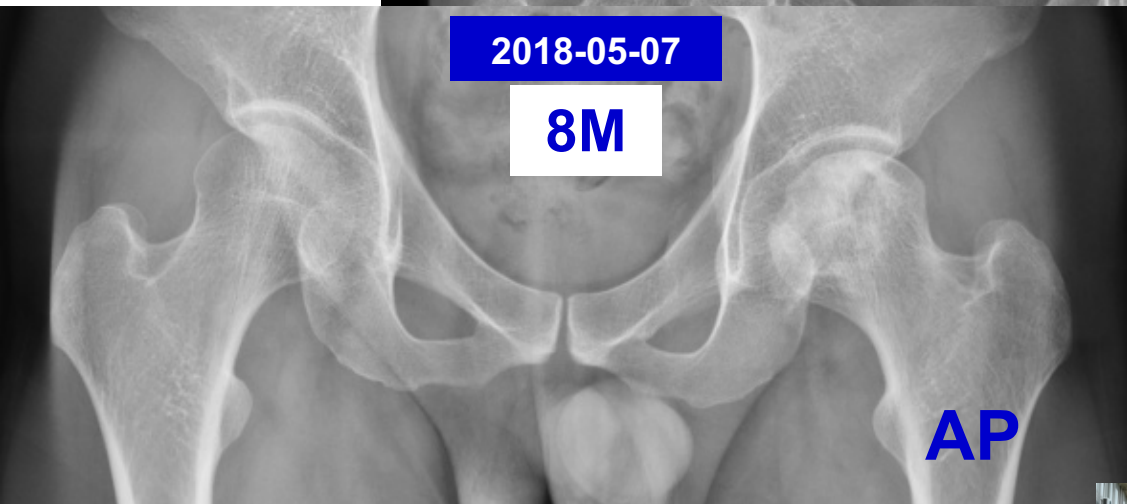
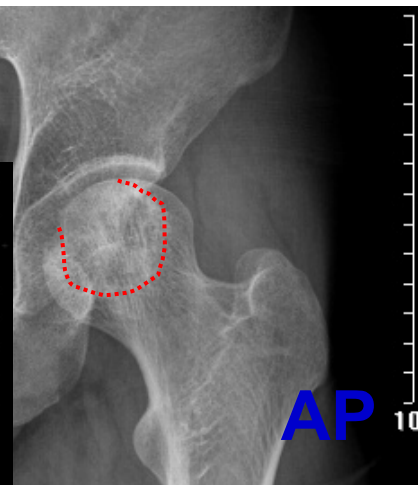
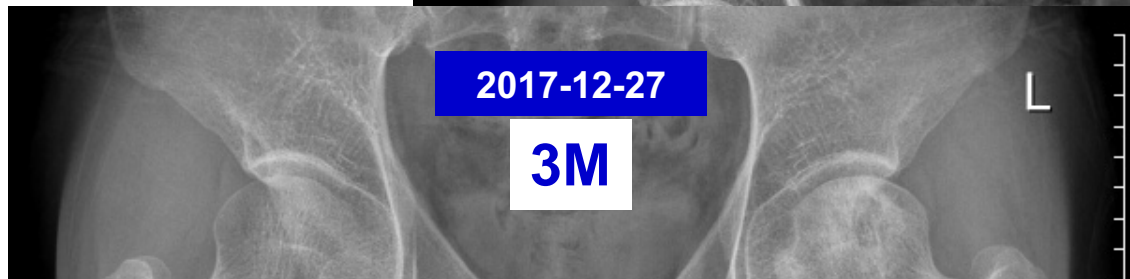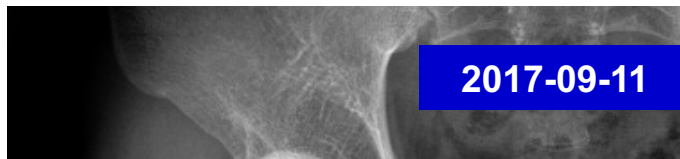
**Femoral head collapse, but is healing. Weight-bearing walking**

Left hip pain  
for 1M

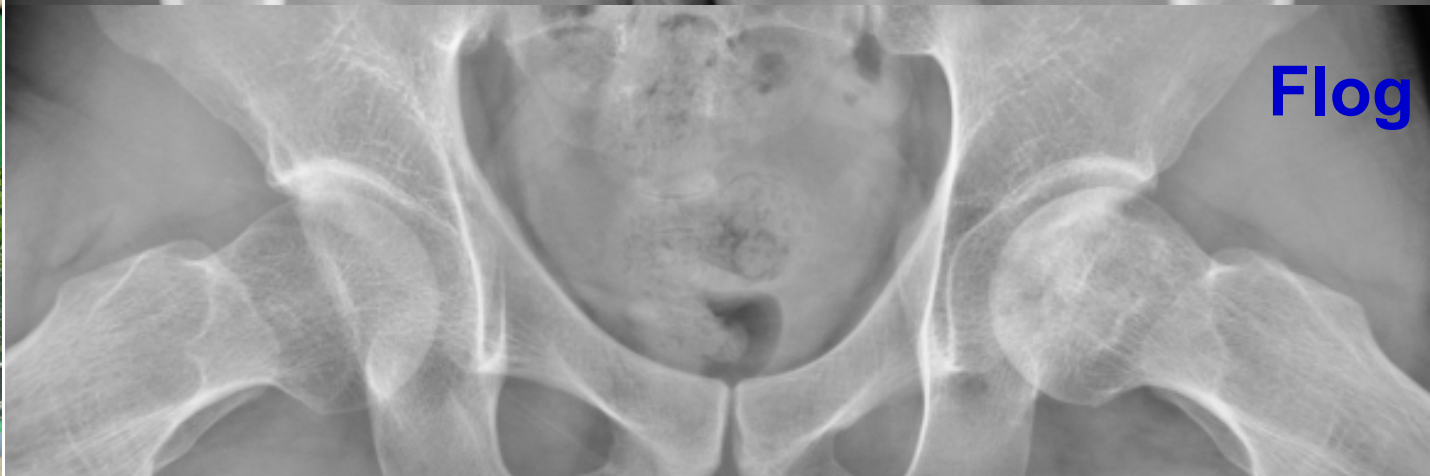
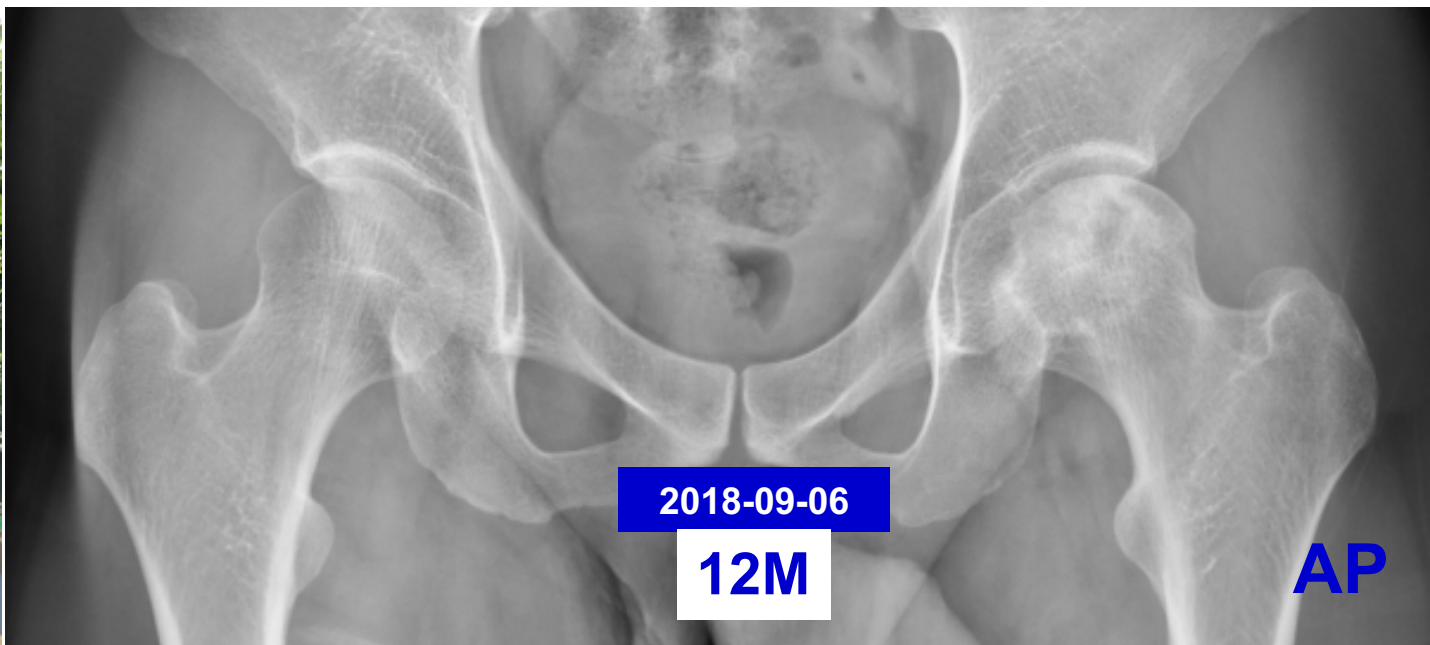


pain release; no progress in collapse of femoral head, but being healing

asymptomatic  
left hip

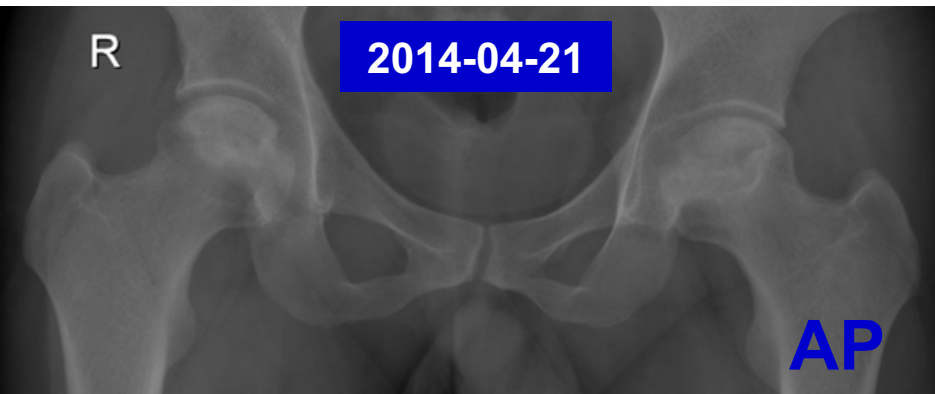


# Chen, Male, 35Y, steroid-ONFH

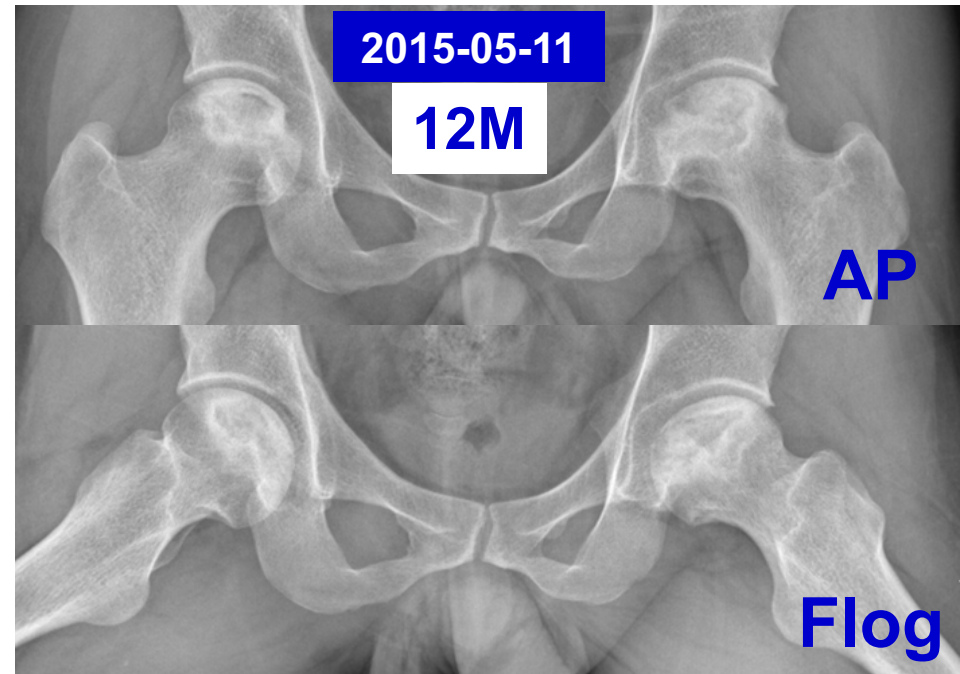
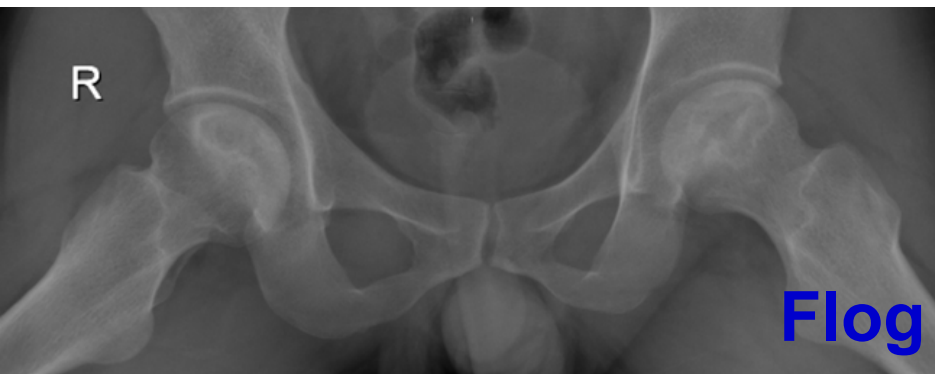

**asymptomatic left hip; no collapse of femoral head;  
weight-bearing walking without stick**





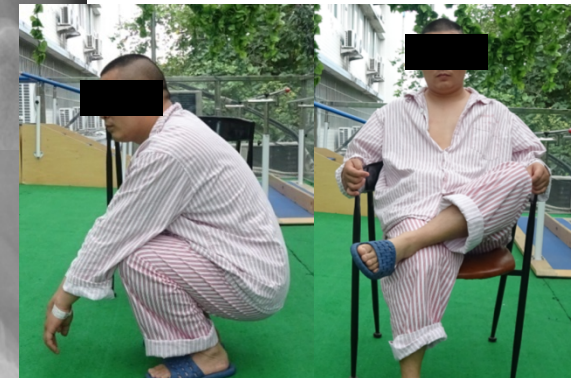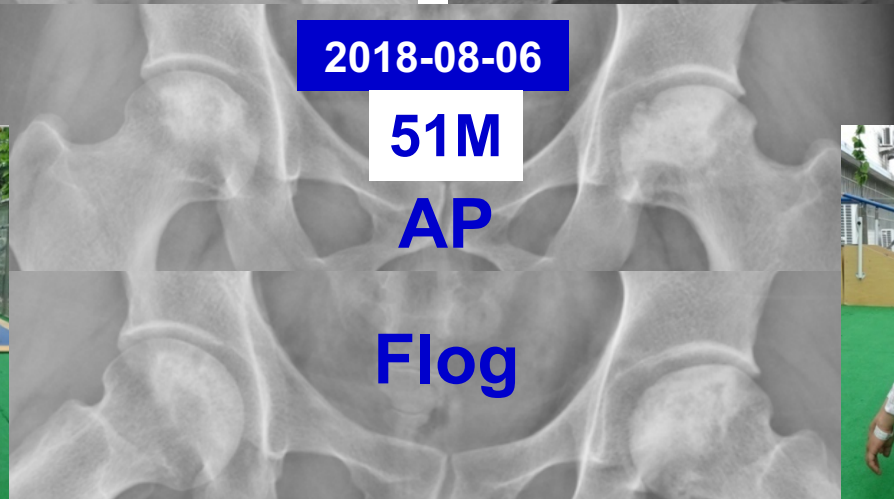
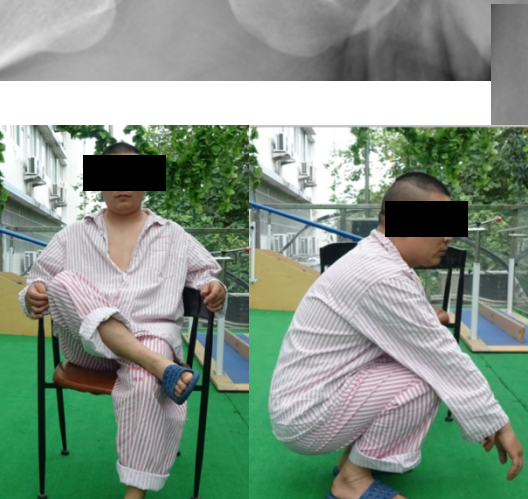
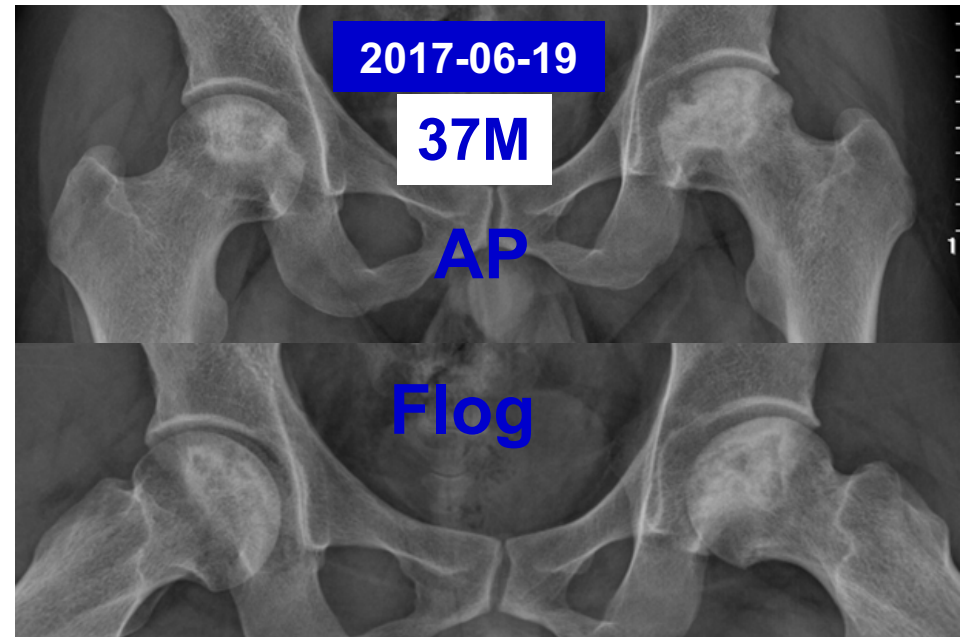
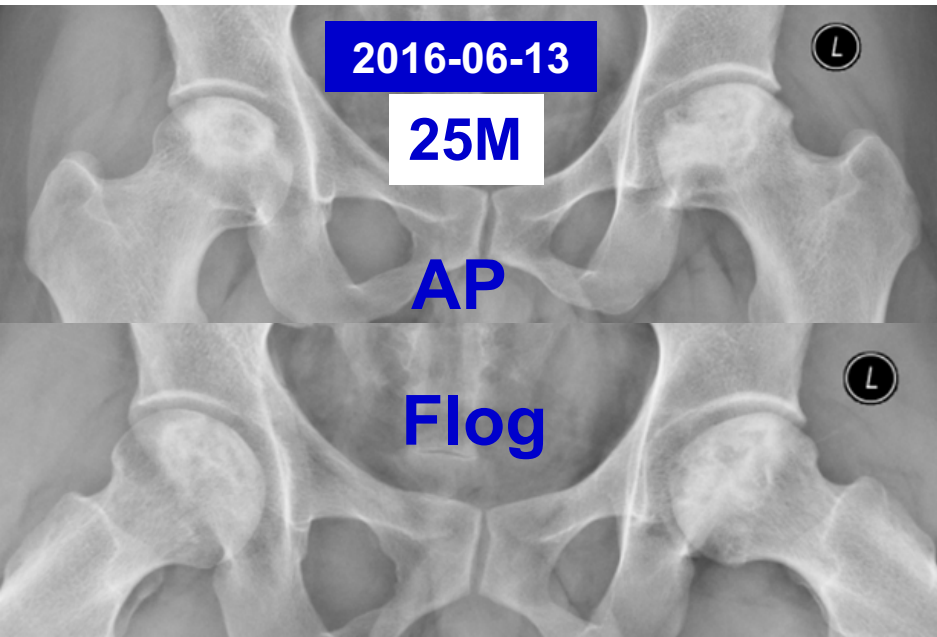
left hip pain for 5 years



(ARCO II)

femoral head collapse; weight-bearing walking

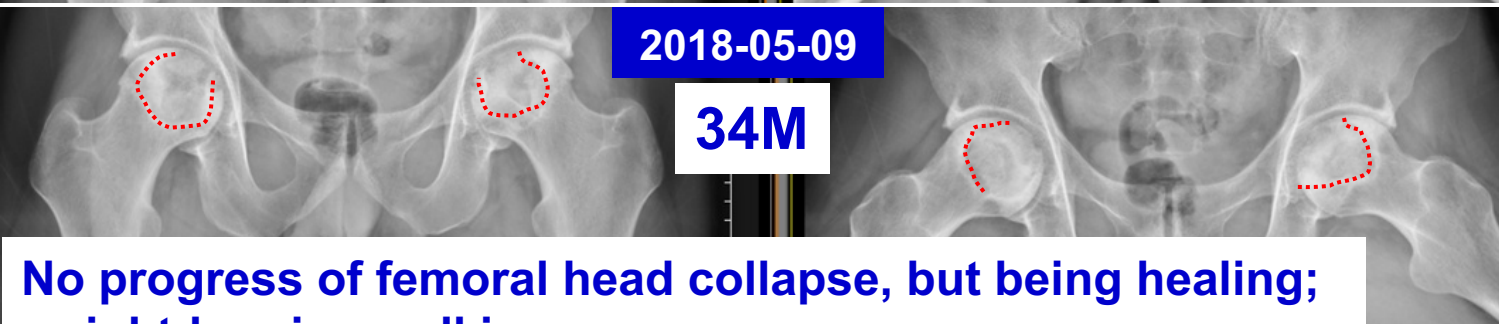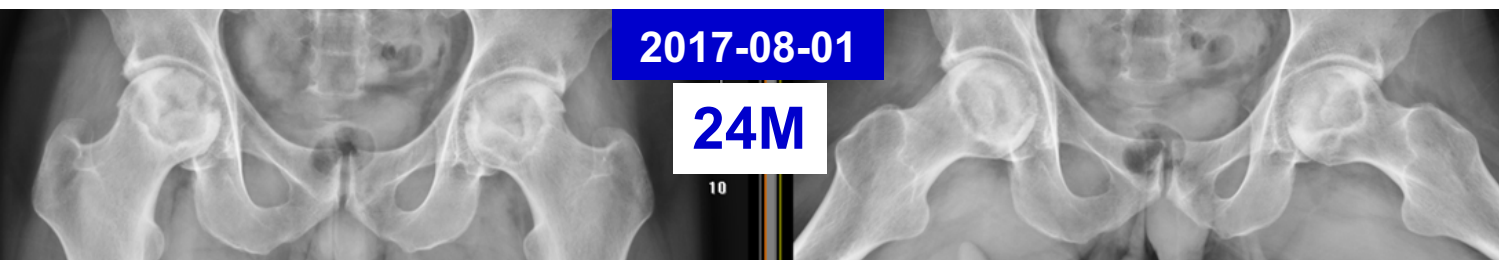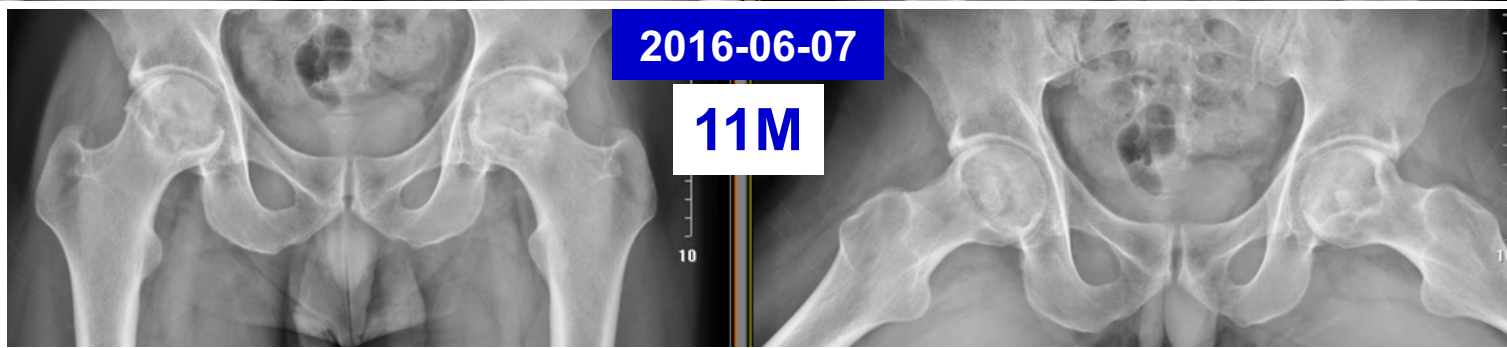
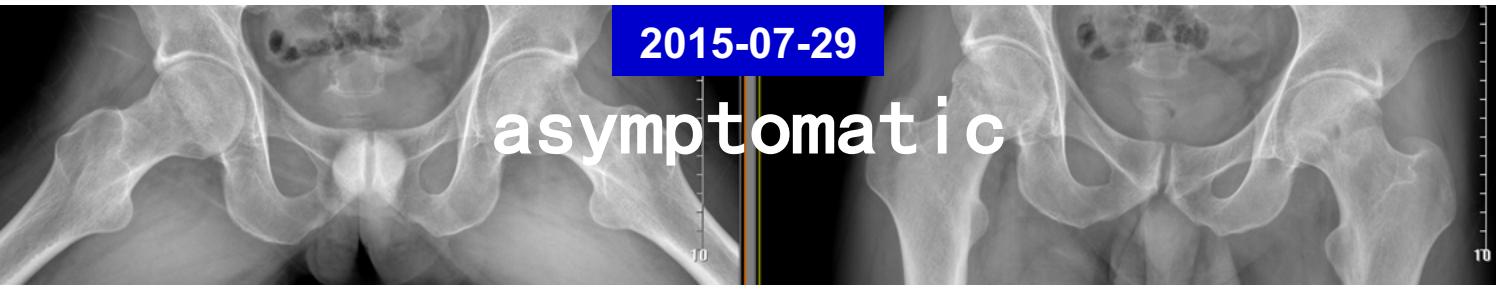
# Duan, Male, 34Y, steroid-ONFH



no progress in collapse of femoral head, but being healing  
weight-bearing walking

# Gong, Male, 45Y, steroid-ONFH

# Case 7



No progress of femoral head collapse, but being healing;  
weight-bearing walking