

## SUPPLEMENTAL MATERIAL

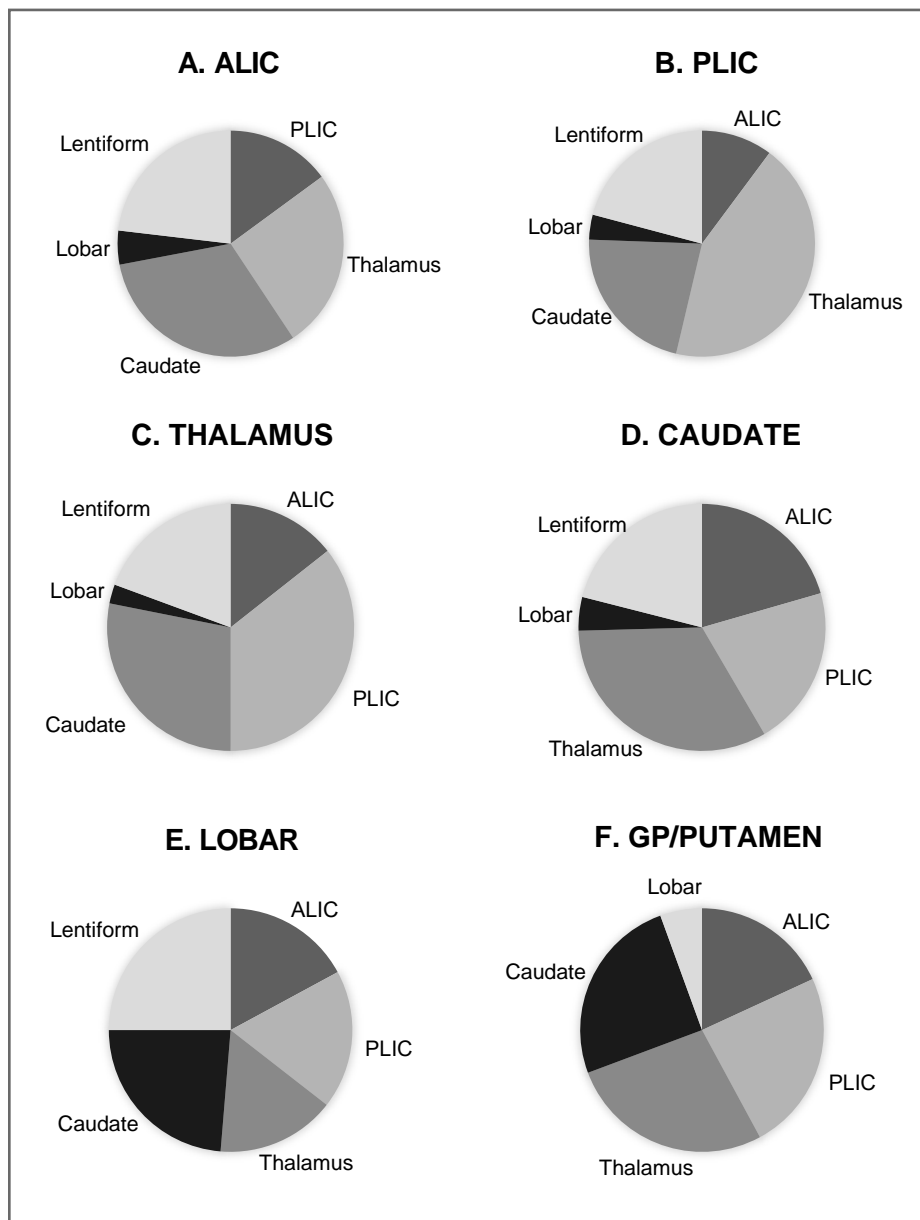
### **Influence of Intracerebral Hemorrhage Location on Outcomes in Patients with Severe Intraventricular Hemorrhage**

Vahid Eslami, MD<sup>1,2</sup>; Pouya Tahsili-Fahadan, MD<sup>1,2,3</sup>; Lucia Rivera-Lara, MD<sup>1,2</sup>; Dheeraj Gandhi, MD<sup>4</sup>; Hasan Ali, MPH<sup>2</sup>; Adrian Parry-Jones, MD<sup>5</sup>; Lilli S. Nelson, MBChB<sup>5</sup>; Richard E. Thompson, PhD<sup>6</sup>; Saman Nekoobakht-Tak, BS<sup>2</sup>; Rachel Dlugash, MSPH<sup>2</sup>; Nichol McBee, MPH<sup>2</sup>; Isaam Awad, MD<sup>7</sup>; Daniel F. Hanley, MD<sup>1,2</sup>; Wendy C. Ziai, MD<sup>1,2</sup>; on behalf of the CLEAR III Investigators

<sup>1</sup>Division of Neurosciences Critical Care, Department of Neurology, Johns Hopkins University School of Medicine, Baltimore, MD; <sup>2</sup>Division of Brain Injury Outcomes, Johns Hopkins University, Baltimore, MD; <sup>3</sup>Neuroscience Intensive Care Unit, Department of Medicine, Virginia Commonwealth University, Falls Church, VA; <sup>4</sup>University of Maryland, Baltimore, MD; <sup>5</sup>School of Medical Sciences, University of Manchester, Manchester Academic Health Sciences Centre, Salford Royal NHS Foundation Trust, UK; <sup>6</sup>Department of Biostatistics, Johns Hopkins Bloomberg School of Public Health, Baltimore, MD; <sup>7</sup>Department of Neurological Surgery, University of Chicago Medicine, Chicago, IL

Corresponding author:

Wendy C. Ziai, MD, MPH, The Johns Hopkins Hospital, 600 N Wolfe St/Phipps 455, Baltimore, MD 21287. Email [weziai@jhmi.edu](mailto:weziai@jhmi.edu)



**Supplementary Figure I.** Frequency of associated ICH locations for each primary ICH location: (A) anterior limb of internal capsule (ALIC), n=108; (B) posterior limb of internal capsule (PLIC), n=188; (C) thalamus, n=332; (D) caudate, n=219; (E) lobar, n=29; and (F) globus pallidus/putamen, n=127.