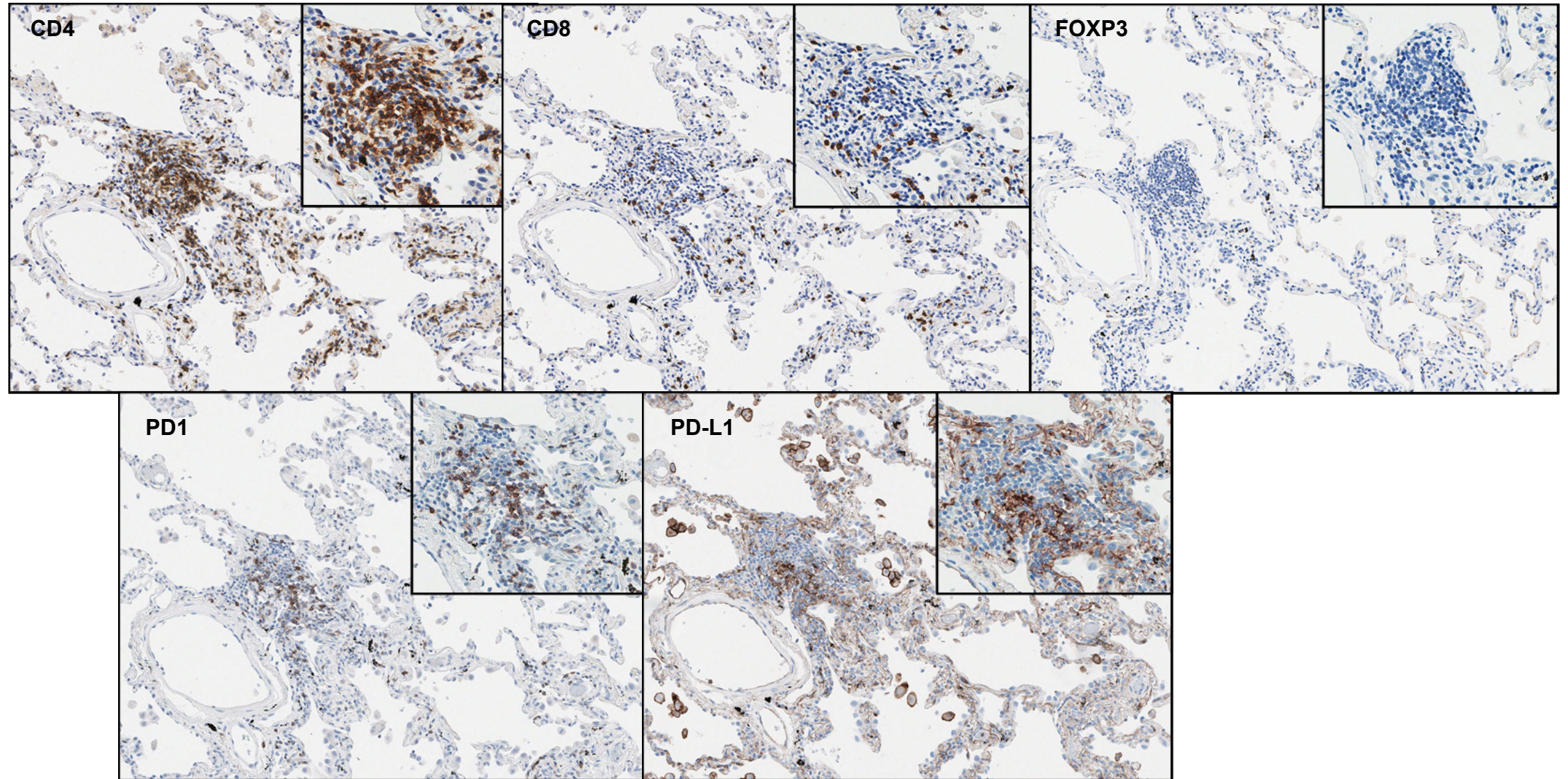


Supplementary Figure S4



Supplementary Figure S4. A representative IHC staining of lymphocytic markers in an AAH lesion with local lymphocyte infiltration score = 2.