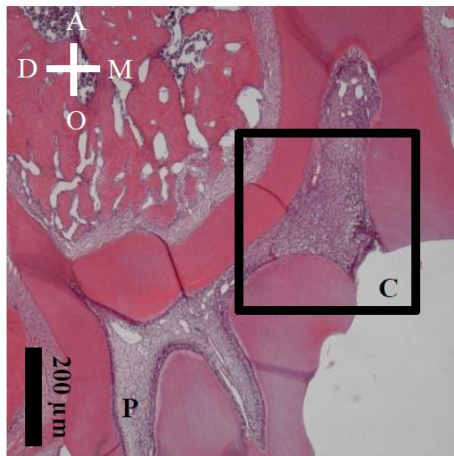


A. Deferoxamine



B. Deferoxamine

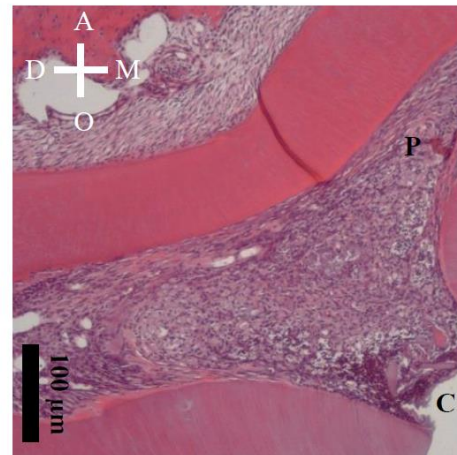


Figure S1. Representative histological images (H-E staining) after direct pulp capping using conventional glass-ionomer cement (Co-GIC) in 4-week samples. Sagittal sections (A) and magnified views of insets (B) are shown. Mineralized tissue was not induced beneath cavity. This result is consistent with the fact that CO-GIC is not accepted as a direct capping material. C = cavity, P = pulp, D = distal, M = mesial, O = occlusal, A = apical.