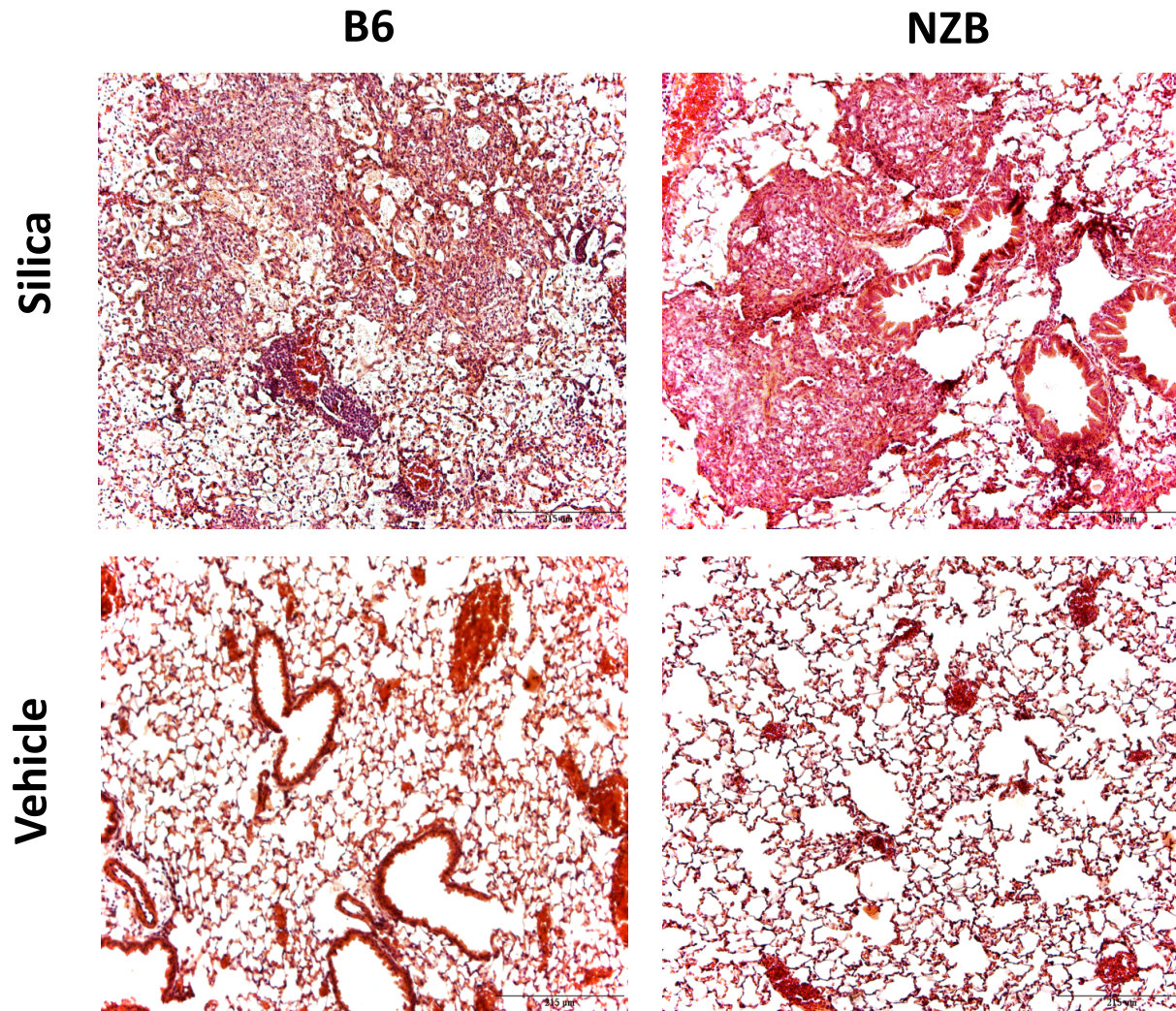


**Figure S.1.**



Lung injury and inflammation from mice one month after exposure.

Representative sections from mice of indicated strain; H&E, original magnification x40.