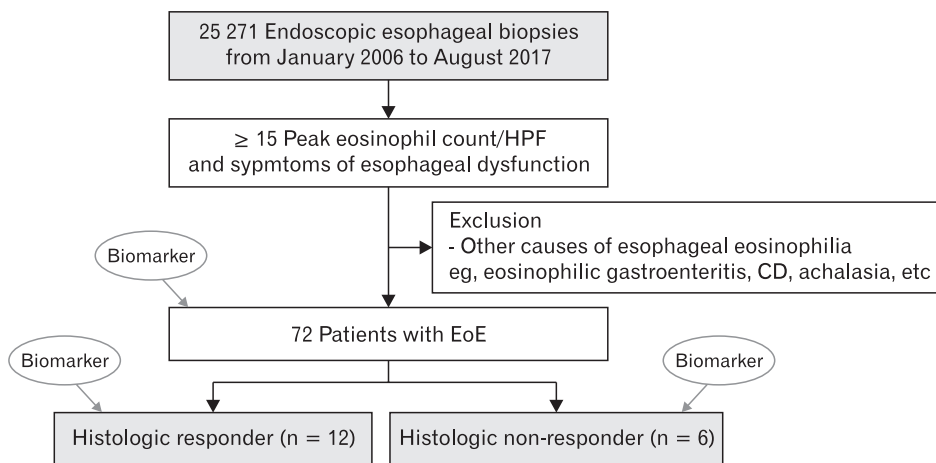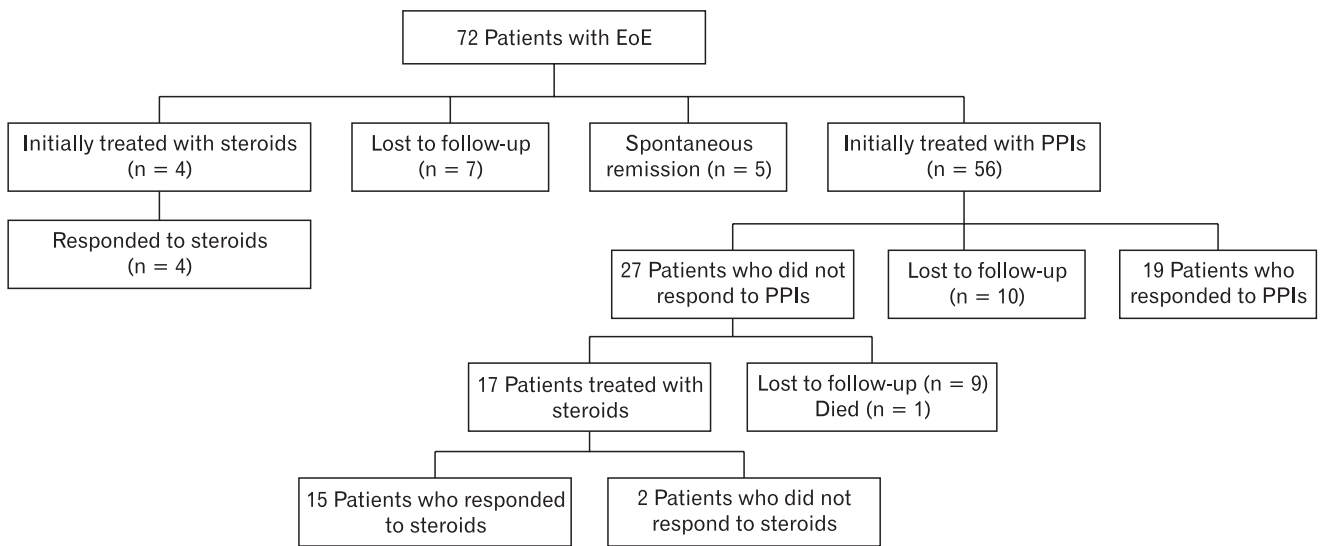
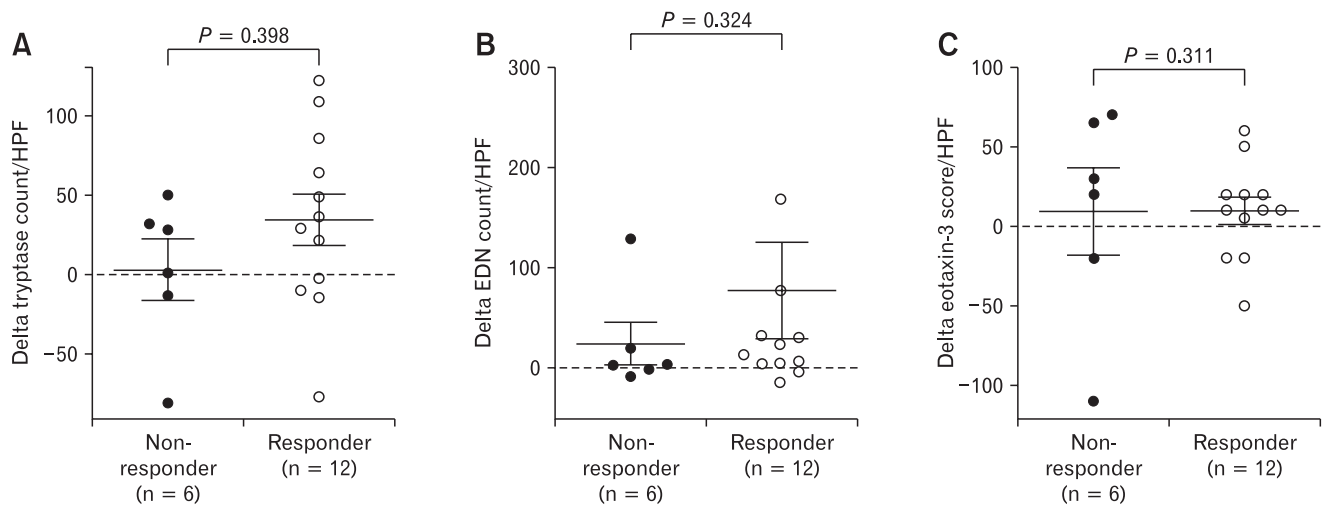


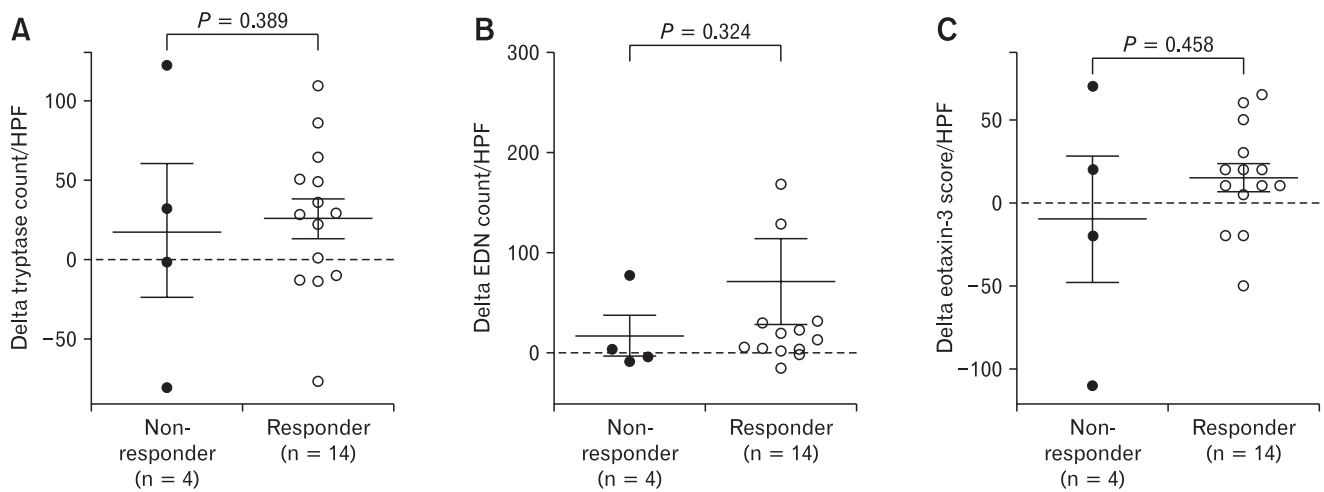
Supplementary Figure 1. Flow chart showing the study patients. HPF, high-power field; CD, Crohn's disease; EoE, eosinophilic esophagitis.



Supplementary Figure 2. Clinical course of the study patients. EoE, eosinophilic esophagitis; PPIs, proton pump inhibitors.



Supplementary Figure 3. Prediction of histologic response with initial immunohistochemical (IHC) staining for (A) tryptase, (B) eosinophilic-derived neurotoxin (EDN), and (C) Eotaxin-3. In this box and whiskers plot, the horizontal line represents the median, the box represents the 25th to 75th percentiles, and the whiskers end at the maximum and minimum values. HPF, high-power field.



Supplementary Figure 4. Prediction of endoscopic response with initial immunohistochemical (IHC) staining for (A) tryptase, (B) eosinophil-derived neurotoxin (EDN), and (c) eotaxin-3. For this box and whiskers plot, the horizontal line represents the median, the box represents the 25th to 75th percentiles, and the whiskers end at the maximum and minimum values. HPF, high-power field.