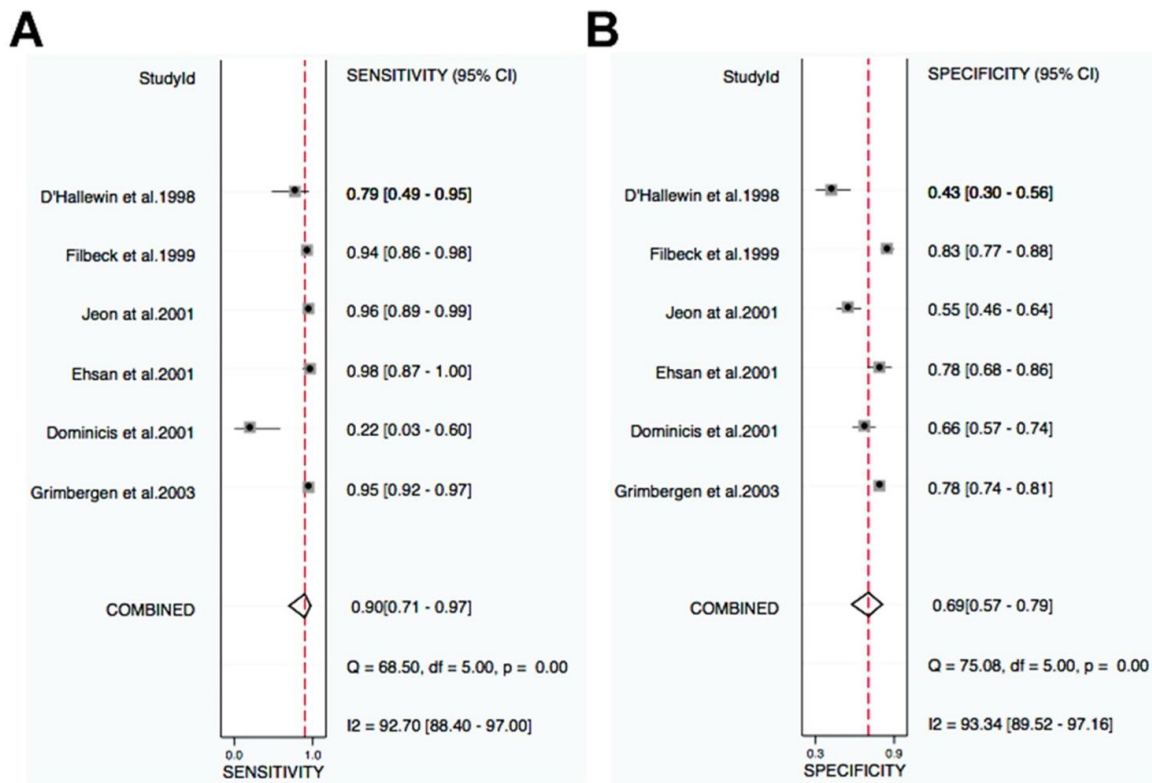
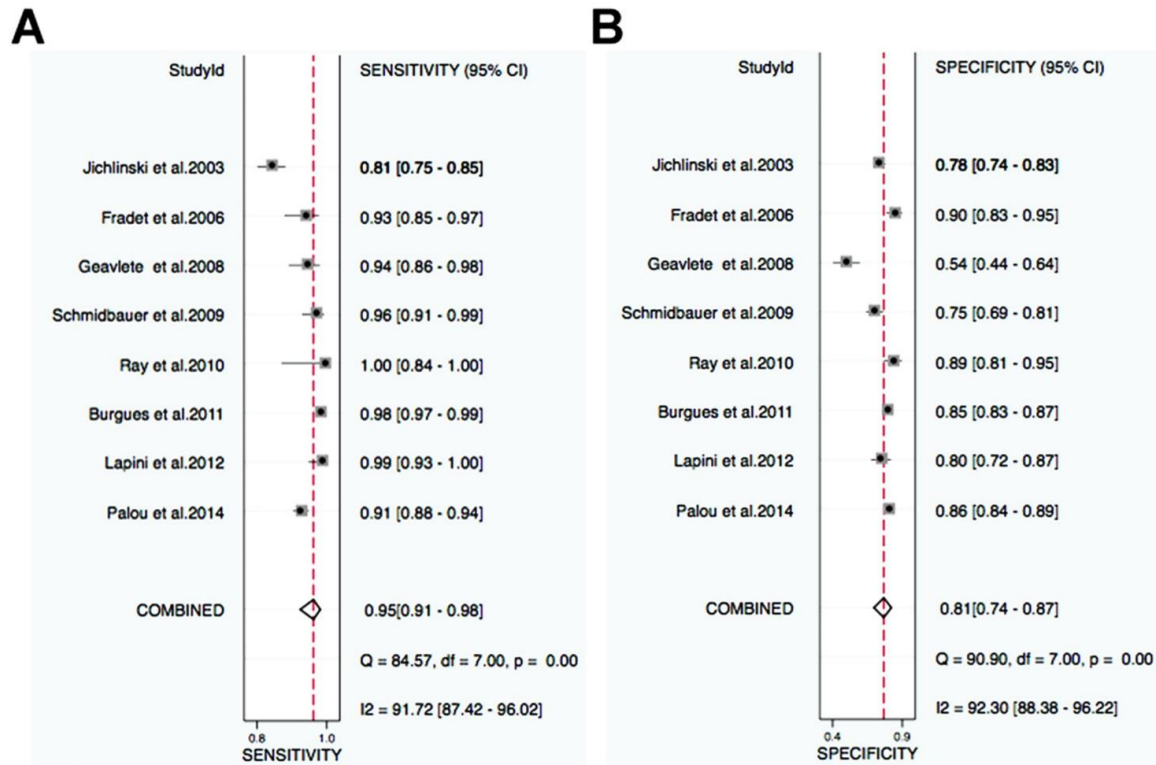


## Supplementary Information

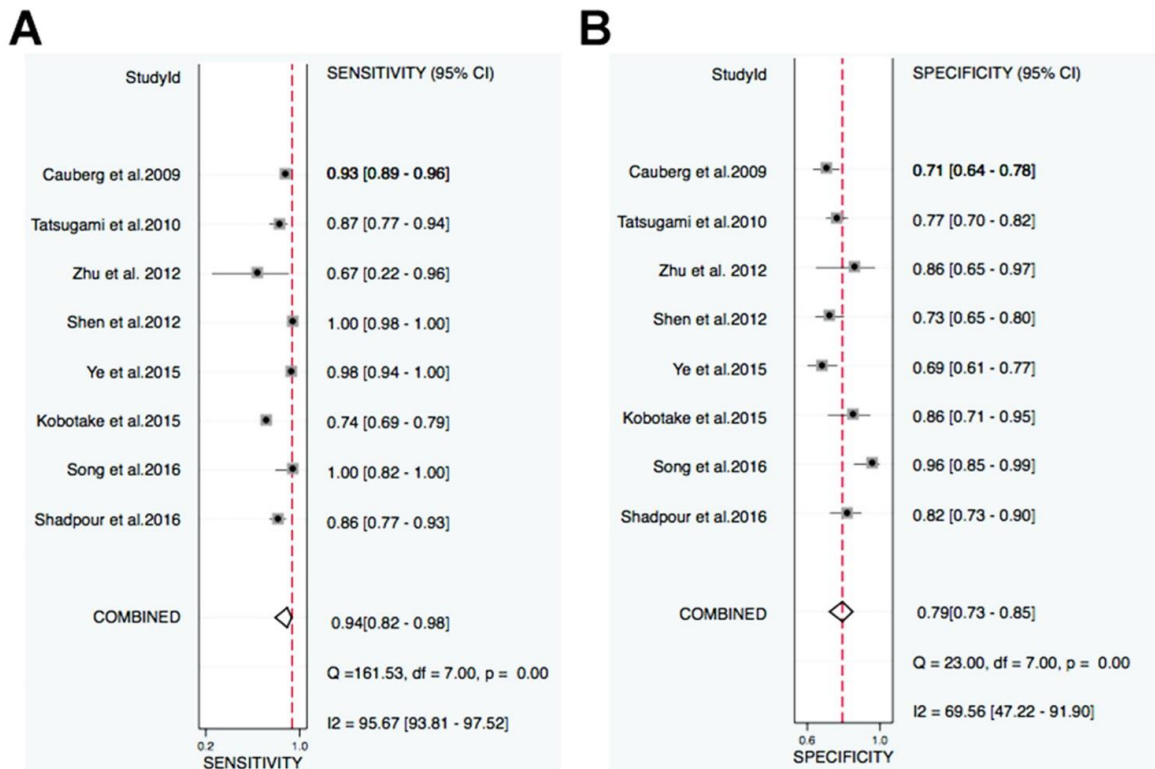


**Supplementary Figure 1.** The Forest Plot of study specific and pooled sensitivity (A) and specificity (B) for NBI in lesion level.

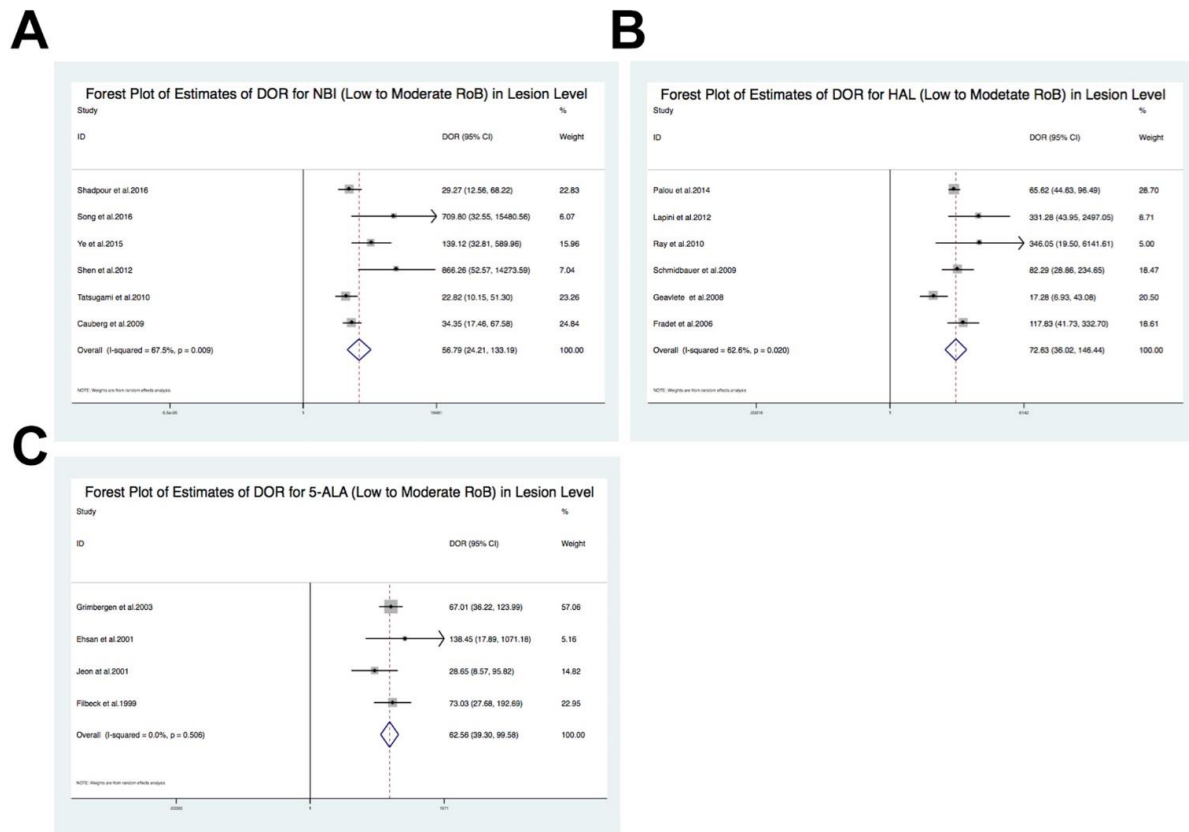


**Supplementary Figure 2.** The Forest Plot of study specific and pooled sensitivity (A) and specificity (B)

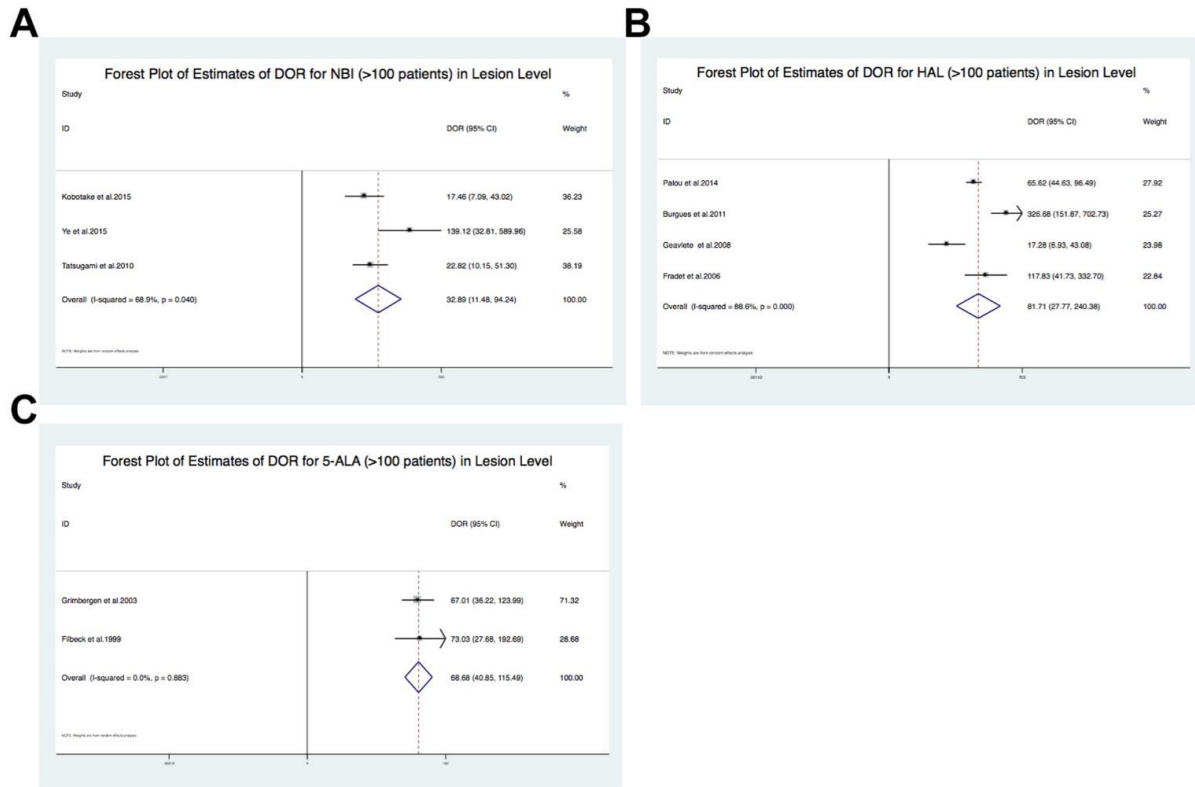
for HAL in lesion level.



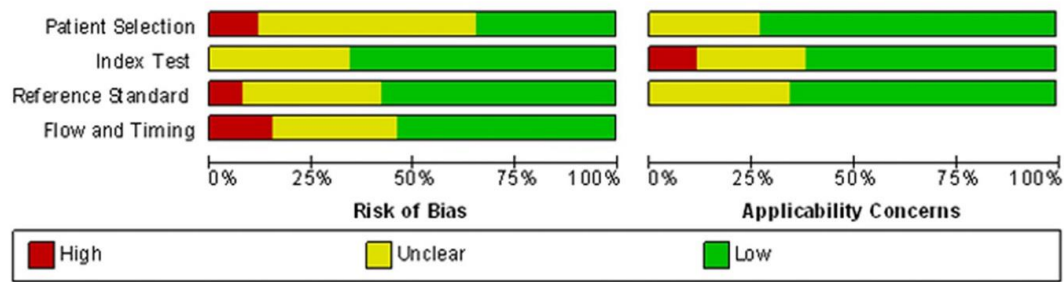
**Supplementary Figure 3.** The Forest Plot of study specific and pooled sensitivity (A) and specificity (B) for 5-ALA in lesion level.



**Supplementary Figure 4.** The Forest Plot of estimates of DOR for NBI (A), HAL (B) and 5-ALA (C) with low to moderate RoB in lesion level.



**Supplementary Figure 5.** The Forest Plot of estimates of DOR for NBI (A), HAL (B) and 5-ALA (C) with at least 100 patients in lesion level.



**Supplementary Figure 6.** Quality assessment of included studies. The distribution plot for risk of bias using QUADAS-2 tool. Studies are deemed to be at high, low or unclear risk of bias for each domain.

**Supplementary Table 1. Diagnostic performance results of individual studies for Meta-analysis**

Study ID	Patient-level analysis							Lesion-level analysis						
	Patient No.	SSY	SPY	FP R	FN R	PP V	NP V	Lesion No.	SSY	SPY	FPR	FN R	PP V	NP V
<b>NBI vs WLC</b>														
Shadpour et al.2016 <sup>1</sup>	50	NR	NR	NR	NR	NR	NR	175	69/80	70/85	15/85	11/80	69/84	74/75
Song et al.2016 <sup>2</sup>	63	16/16	46/47	1/47	0/1	16/17	23/23	66	19/19	45/47	2/47	0/1	19/21	7/7
Kobota et al.2015 <sup>3</sup>	135	NR	NR	NR	NR	NR	NR	379	78/84	227/263	36/63	6/84	78/114	203/203
Ye et al.2015 <sup>4</sup>	103	56/56	16/45	29/46	0/5	56/85	8/8	300	124/126	92/33	41/33	2/26	124/165	83/5
Shen et al.2012 <sup>5</sup>	78	47/47	9/22	13/22	0/4	47/47	7/7	309	160/160	98/34	36/34	0/60	160/196	72/2
Zhu et al.2012 <sup>6</sup>	12	NR	NR	NR	NR	NR	NR	31	4/6	19/22	3/22	2/6	4/7	20/20
Tatsugami et al.2010 <sup>7</sup>	104	NR	NR	NR	NR	NR	NR	313	55/63	156/203	47/203	8/63	55/102	144/144
Cauberg et al.2009 <sup>8</sup>	95	NR	NR	NR	NR	NR	NR	389	167/179	116/163	47/63	12/179	167/214	47/51
Herr et al.2008 <sup>9</sup>	427	90/90	311/324	13/24	0/0	90/103	265/265	NR	NR	NR	NR	NR	NR	NR
<b>HAL vs WLC</b>														
Palou et al.2014 <sup>10</sup>	283	NR	NR	NR	NR	NR	NR	149	379/416	820/948	128/948	37/416	379/507	699/702
Lapini et al.2012 <sup>11</sup>	96	NR	NR	NR	NR	NR	NR	234	82/83	101/126	25/26	1/83	82/107	80/81
Burgues et al.2011 <sup>12</sup>	305	NR	NR	NR	NR	NR	NR	165	404/441	900/1059	159/1059	7/41	404/563	863/863

<b>Ray et al.2010<sup>13</sup></b>	27	NR	NR	NR	NR	NR	NR	120	21/21	84/94	10/94	0/21	21/31	35/35
<b>Schmidbauer et al.2009<sup>14</sup></b>	66	52/52	2/8	6/8	0/52	52/58	3/3	364	109/113	151/201	50/201	4/13	109/159	158/158
<b>Geavlete et al.2008<sup>15</sup></b>	128	NR	NR	NR	NR	NR	NR	243	87/93	56/103	47/103	6/93	87/134	76/82
<b>Fradet et al.2006<sup>16</sup></b>	196	40/48	128/138	10/138	8/48	40/50	106/113	206	77/83	101/112	11/112	6/83	77/88	63/71
<b>Jichlinski et al.2003<sup>17</sup></b>	52	33/33	7/17	10/17	0/33	33/43	3/3	143	205/254	269/343	74/343	49/254	205/279	306/314
<b>5-ALA vs WLC</b>														
<b>Grimbergen et al.2003<sup>18</sup></b>	160	NR	NR	NR	NR	NR	NR	889	232/244	409/527	118/527	12/244	232/350	248/257
<b>Filbeck et al.2002<sup>19</sup></b>	279	168/168	93/102	9/102	0/168	168/177	81/81	NR	NR	NR	NR	NR	NR	NR
<b>Domincis et al.2001<sup>20</sup></b>	49	NR	NR	NR	NR	NR	NR	179	2/9	84/127	43/127	7/9	2/45	80/80
<b>Ehsan et al.2001<sup>21</sup></b>	30	NR	NR	NR	NR	NR	NR	151	39/40	71/91	20/91	1/40	39/59	59/59
<b>Jeon et al.2001<sup>22</sup></b>	62	NR	NR	NR	NR	NR	NR	257	71/74	69/126	57/126	3/74	71/128	54/124
<b>Zaak et al.2001<sup>23</sup></b>	605	288/363	271/460	189/460	75/363	288/477	55/108	NR	NR	NR	NR	NR	NR	NR
<b>Filbeck et al.2001<sup>24</sup></b>	123	NR	NR	NR	NR	NR	NR	341	75/80	185/223	38/223	5/80	75/113	78/78



**al.1999<sup>2</sup>**

4

<b>Riedl et</b>	52	26/2	10/1	8/18	0/2	26/3	6/6	NR	NR	NR	NR	NR	NR	NR
-----------------	----	------	------	------	-----	------	-----	----	----	----	----	----	----	----

**al.1999<sup>2</sup>**

5

<b>D'Halle</b>	16	NR	NR	NR	NR	NR	NR	113	11/1	27/6	36/6	3/1	11/4	34/3
<b>win et</b>									4	3	3	4	7	4

**al.1998<sup>2</sup>**

6

---

NMIBC: non-muscle-invasive bladder cancer; WLC: white light cystoscopy; 5-ALA: 5-aminolaevulinic acid; HAL: hexylaminolevulinate; NBI: narrow band imaging; NT: new technology; SSY: sensitivity; SPY: specificity; FPR: false positive rate; FNR: false negative rate; PPV: positive predictive value; NPV: negative predictive value; NR: not reported.

**Supplementary Table 2. Diagnostic performance results for sensitivity analysis of studies with low to moderate RoB and at least 100 patients at lesion level.**

	Low to moderate RoB			At least 100 patients		
	Median	Lower Quartile	Upper Quartile	Median	Lower Quartile	Upper Quartile
<b>NBI vs WLC (n=6)</b>				<b>NBI vs WLC (n=3)</b>		
Sensitivity	95.85	88.80	99.60	92.86	90.08	95.63
Specificity	74.99	71.66	80.98	76.85	73.01	81.58
Positive predictive value	79.84	75.87	82.02	68.42	61.17	71.79
Negative predictive value	99.33	97.90	100	100	98.82	100
False positive rate	25.01	19.02	28.34	23.15	18.42	26.99
False negative rate	4.15	0.40	11.20	7.14	4.37	9.92
<b>HAL vs WLC (n=6)</b>				<b>HAL vs WLC (n=4)</b>		
Sensitivity	95.00	92.97	98.21	92.19	91.48	92.97
Specificity	83.33	76.38	88.65	85.74	77.33	87.42
Positive predictive value	71.65	67.94	76.16	73.26	70.05	77.94
Negative predictive value	99.17	94.20	99.89	96.13	91.70	99.68
False positive rate	16.67	11.35	23.62	14.26	12.58	22.67
False negative rate	5.00	1.79	7.03	6.84	5.24	7.65
<b>5-ALA vs WLC (n=4)</b>				<b>5-ALA vs WLC (n=2)</b>		
Sensitivity	95.51	94.75	96.33	94.42	-	-
Specificity	77.82	71.90	79.26	80.28	-	-
Positive predictive value	66.19	63.44	66.31	66.33	-	-
Negative predictive value	100	99.12	100	98.25	-	-
False positive rate	22.18	20.74	28.10	19.72	-	-
False negative rate	4.49	3.67	5.25	5.58	-	-

NMIBC: non-muscle-invasive bladder cancer; WLC: white light cystoscopy; 5-ALA: 5-aminolaevulinic acid; HAL: hexylaminolevulinate; NBI: narrow band imaging; NR: not reported.

**Appendix: Full search strategy**

## 1. Searching in MEDLINE, Embase and CENTRAL

All databases were searched using both controlled vocabulary (namely MeSH in MEDLINE and Emtree in Embase) and a wide range of free-text terms

Search code for MEDLINE (accessed via PubMed) and CENTRAL

<b>Patients</b>		
Bladder cancer	#1	bladder neoplasms [MeSH] OR carcinoma OR tumor, urothelial cell [MeSH] OR transitional cell carcinoma*[tiab] OR bladder neoplasm*[tiab] OR bladder cancer[tiab] OR BCa[tiab]
<b>Index test</b>		
Photodynamic diagnosis	#2	“photodynamic diagnosis” [MeSH] OR “PDD” [tiab] OR “photodynamic” [tiab] OR hexaminolevulinate [tiab] OR HAL[tiab] OR “5-aminolevulinate acid”[tiab] OR 5-ALA[tiab] OR cystoscopic[tiab] OR cystoscopy
Narrow band imaging	#3	“narrow band imaging” [MeSH] OR NBI [tiab] OR cystoscopic[tiab] OR cystoscopy[tiab]
Cochrane Highly Sensitive Search Strategy	#4	(observational trial[Publication Type] OR diagnostic[Publication Type] OR detection[tiab] OR observational[tiab] OR trial[tiab] OR groups[tiab]) NOT (animals[mh] NOT humans[mh])
Search algorithm		#1 AND (#2 OR #3) AND #4

## 2. Searching other resources

Previous systematic reviews in the Cochrane Database of Systematic Reviews, the Database of Abstracts of Reviews of Effectiveness and the PROSPERO international prospective register of systematic reviews for completed or published systematic reviews

## References

1. Shadpour P, Emami M, Haghdani S. A Comparison of the Progression and Recurrence Risk Index in Non-Muscle-Invasive Bladder Tumors Detected by Narrow-Band Imaging Versus White Light Cystoscopy, Based on the EORTC Scoring System. *Nephrourol Mon* 2016; 8(1):e33240.
2. Song PH, Cho S, Ko YH. Decision Based on Narrow Band Imaging Cystoscopy without a Referential Normal Standard Rather Increases Unnecessary Biopsy in Detection of Recurrent Bladder Urothelial Carcinoma Early after Intravesical Instillation. *Cancer Res Treat* 2016; 48(1):273-80.
3. Kobatake K, Mita K, Ohara S, et al. Advantage of transurethral resection with narrow band imaging for non-muscle invasive bladder cancer. *Oncol Lett* 2015; 10(2):1097-1102.
4. Ye Z, Hu J, Song X, et al. A comparison of NBI and WLI cystoscopy in detecting non-muscle-invasive bladder cancer: A prospective, randomized and multi-center study. *Sci Rep* 2015; 5:10905.
5. Shen YJ, Zhu YP, Ye DW, et al. Narrow-band imaging flexible cystoscopy in the detection of primary non-muscle invasive bladder cancer: a "second look" matters? *Int Urol Nephrol* 2012; 44(2):451-7.
6. Zhu YP, Shen YJ, Ye DW, et al. Narrow-band imaging flexible cystoscopy in the detection of clinically unconfirmed positive urine cytology. *Urol Int* 2012; 88(1):84-7.
7. Tatsugami K, Kuroiwa K, Kamoto T, et al. Evaluation of narrow-band imaging as a complementary method for the detection of bladder cancer. *J Endourol* 2010; 24(11):1807-11.
8. Cauberg EC, Kloen S, Visser M, et al. Narrow band imaging cystoscopy improves the detection of non-muscle-invasive bladder cancer. *Urology* 2010; 76(3):658-63.
9. Herr HW, Donat SM. A comparison of white-light cystoscopy and narrow-band imaging cystoscopy to detect bladder tumour recurrences. *BJU Int* 2008; 102(9):1111-4.
10. Palou J, Hernandez C, Solsona E, et al. Effectiveness of hexaminolevulinate fluorescence cystoscopy for the diagnosis of non-muscle-invasive bladder cancer in daily clinical practice: a Spanish multicentre observational study. *BJU Int* 2015; 116(1):37-43.
11. Lapini A, Minervini A, Masala A, et al. A comparison of hexaminolevulinate (Hexvix((R))) fluorescence cystoscopy and white-light cystoscopy for detection of bladder cancer: results of the HeRo observational study. *Surg Endosc* 2012; 26(12):3634-41.
12. Burgues JP, Conde G, Oliva J, et al. [Hexaminolevulinate photodynamic diagnosis in non-muscle invasive bladder cancer: experience of the BLUE group]. *Actas Urol Esp* 2011; 35(8):439-45.
13. Ray ER, Chatterton K, Khan MS, et al. Hexylaminolaevulinate fluorescence cystoscopy in patients previously treated with intravesical bacille Calmette-Guerin. *BJU Int* 2010; 105(6):789-94.
14. Schmidbauer J, Remzi M, Klatte T, et al. Fluorescence cystoscopy with high-resolution optical coherence tomography imaging as an adjunct reduces false-positive findings in the diagnosis of urothelial carcinoma of the bladder. *Eur Urol* 2009; 56(6):914-9.
15. Geavlete B, Multescu R, Georgescu D, et al. Hexaminolevulinate fluorescence cystoscopy and transurethral resection of the bladder in noninvasive bladder tumors. *J Endourol* 2009; 23(6):977-81.
16. Fradet Y, Grossman HB, Gomella L, et al. A comparison of hexaminolevulinate fluorescence cystoscopy and white light cystoscopy for the detection of carcinoma in situ in patients with bladder cancer: a phase III, multicenter study. *J Urol* 2007; 178(1):68-73; discussion 73.
17. Jichlinski P, Guillou L, Karlsen SJ, et al. Hexyl aminolevulinate fluorescence cystoscopy: new diagnostic tool for photodiagnosis of superficial bladder cancer--a multicenter study. *J Urol* 2003; 170(1):226-9.
18. Grimbergen MCM, van Swol CFP, Jonges TGN, et al. Reduced Specificity of 5-ALA Induced Fluorescence in Photodynamic Diagnosis of Transitional Cell Carcinoma after Previous Intravesical Therapy. *European Urology* 2003; 44(1):51-56.
19. Filbeck T, Pichlmeier U, Knuechel R, et al. Do patients profit from 5-aminolevulinic acid-induced fluorescence diagnosis in transurethral resection of bladder carcinoma? *Urology* 2002; 60(6):1025-8.

20. De Dominicis C, Liberti M, Perugia G, et al. Role of 5-aminolevulinic acid in the diagnosis and treatment of superficial bladder cancer: improvement in diagnostic sensitivity. *Urology* 2001; 57(6):1059-62.
21. Ehsan A, Sommer F, Haupt G, et al. Significance of fluorescence cystoscopy for diagnosis of superficial bladder cancer after intravesical instillation of delta aminolevulinic acid. *Urol Int* 2001; 67(4):298-304.
22. Jeon SS, Kang I, Hong JH, et al. Diagnostic efficacy of fluorescence cystoscopy for detection of urothelial neoplasms. *J Endourol* 2001; 15(7):753-9.
23. Zaak D, Kriegmair M, Stepp H, et al. Endoscopic detection of transitional cell carcinoma with 5-aminolevulinic acid: results of 1012 fluorescence endoscopies. *Urology* 2001; 57(4):690-4.
24. Filbeck T, Roessler W, Knuechel R, et al. Clinical results of the transurethral resection and evaluation of superficial bladder carcinomas by means of fluorescence diagnosis after intravesical instillation of 5-aminolevulinic acid. *J Endourol* 1999; 13(2):117-21.
25. Riedl CR, Plas E, Pfluger H. Fluorescence detection of bladder tumors with 5-amino-levulinic acid. *J Endourol* 1999; 13(10):755-9.
26. D'Hallewin MA, Vanherzeele H, Baert L. Fluorescence detection of flat transitional cell carcinoma after intravesical instillation of aminolevulinic acid. *Am J Clin Oncol* 1998; 21(3):223-5.