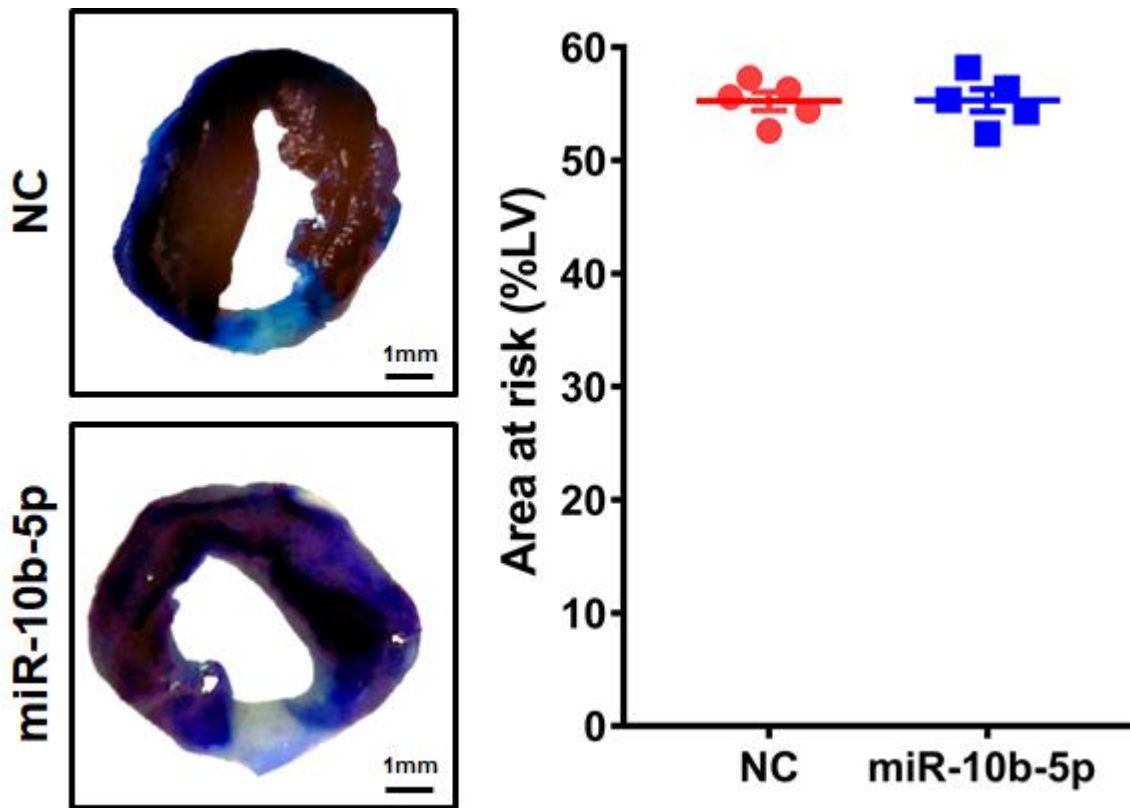


SUPPLEMENTAL MATERIAL

Figure S1. The ischemic area of NC and miR-10b-5p infection cardiac.



The sections of cardiac tissues were stained with Evans blue and TTC at day 2 post-surgery. The results of area at risk /left ventricular (LV) area were measured.