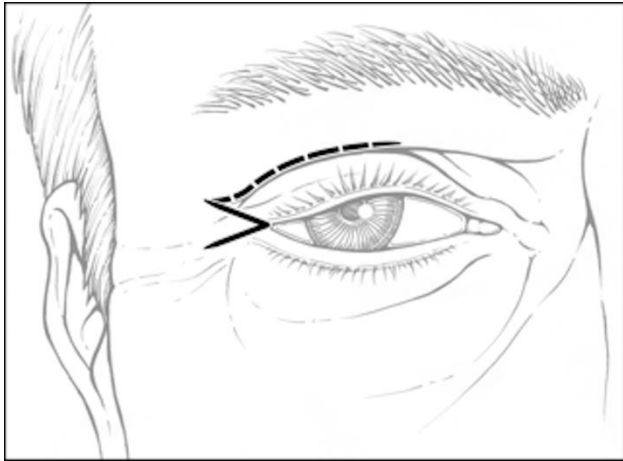
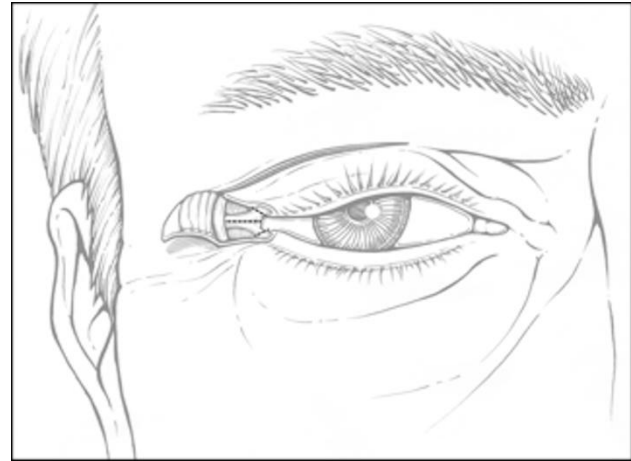


SDC 1

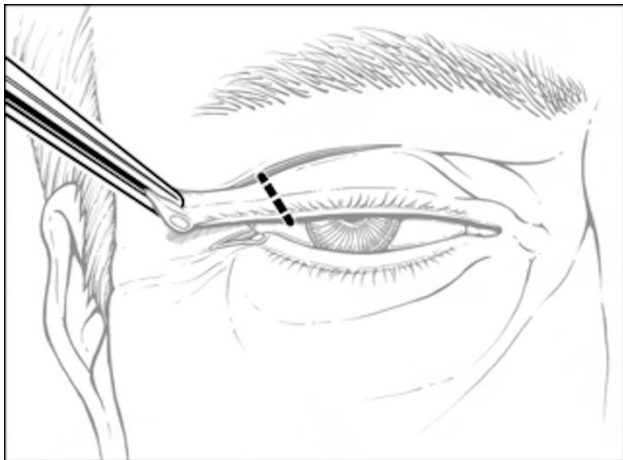
1A



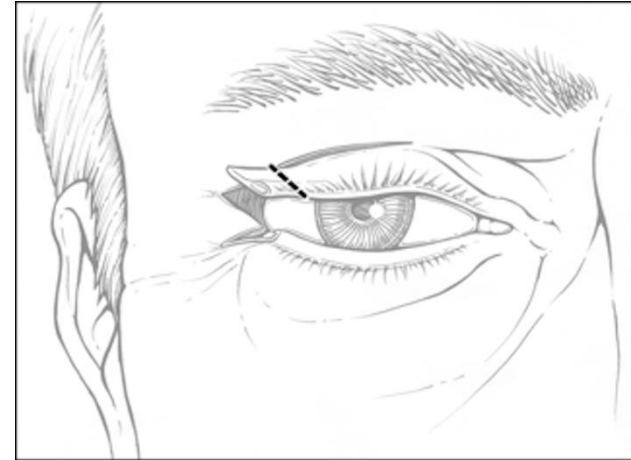
1B



1C



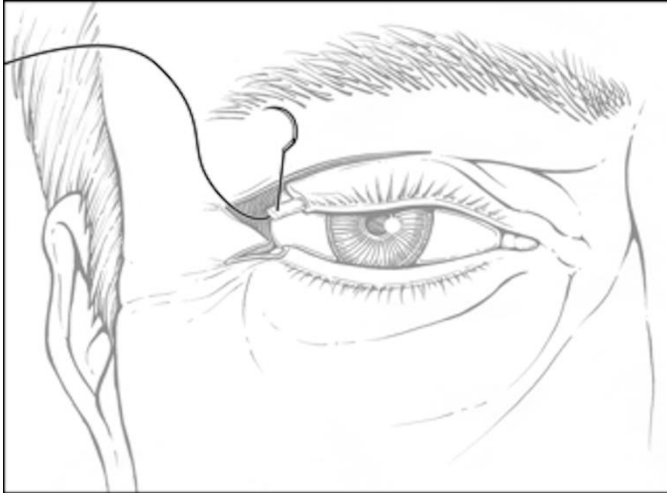
1D



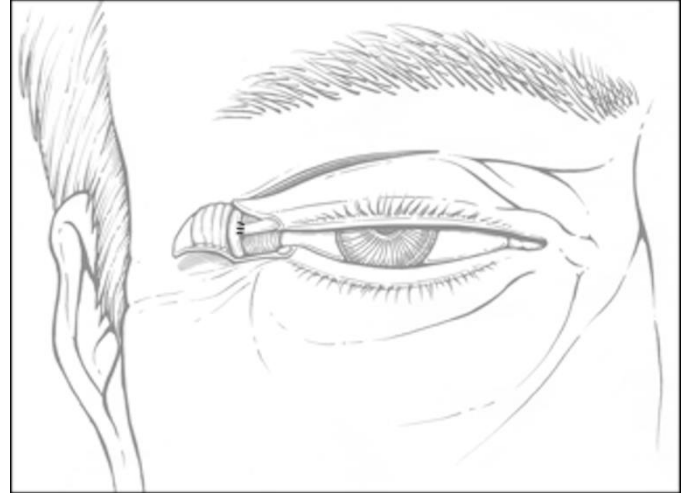
Supplemental Digital Content 1A demonstrates the lateral canthal "V" incision, with the option to carry superiorly into the lid crease. In Supplemental Digital Content 1B, the lateral canthotomy and cantholysis of the upper and lower eyelids is seen. Supplemental Digital Content 1C-and 1D demonstrate the shortening of the upper lid and creation of the tarsal strip.

SDC 1E-1H

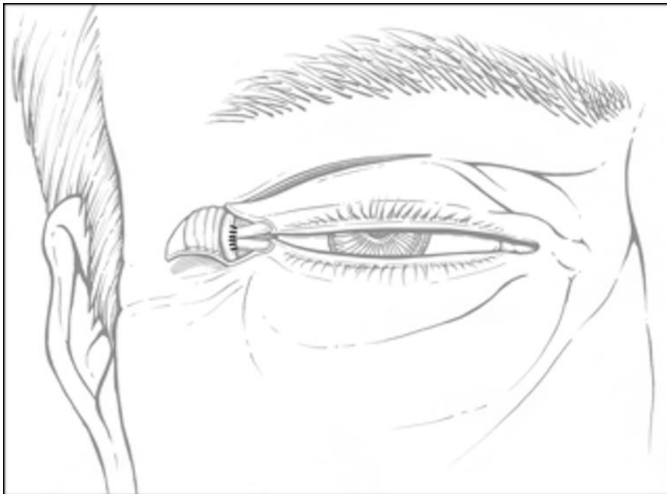
1E



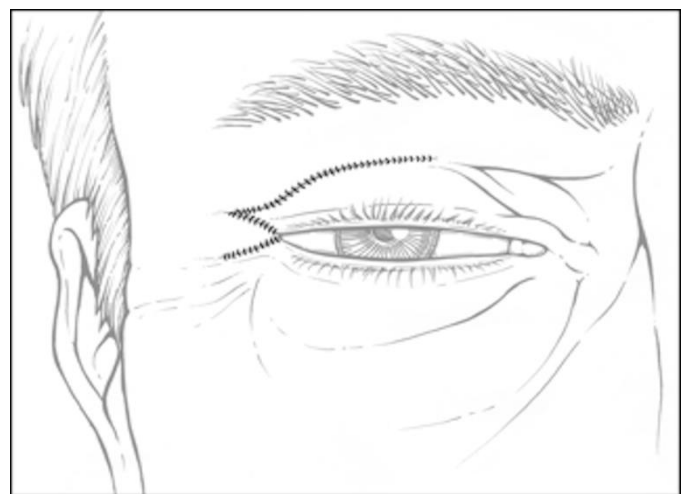
1F



1G



1H



Supplemental Digital Content 1E, 1F and 1G demonstrate the anchoring of the upper and lower tarsal strips. In Supplemental Digital Content 1H, the incision is closed, showing the preservation of the lateral canthal architecture.