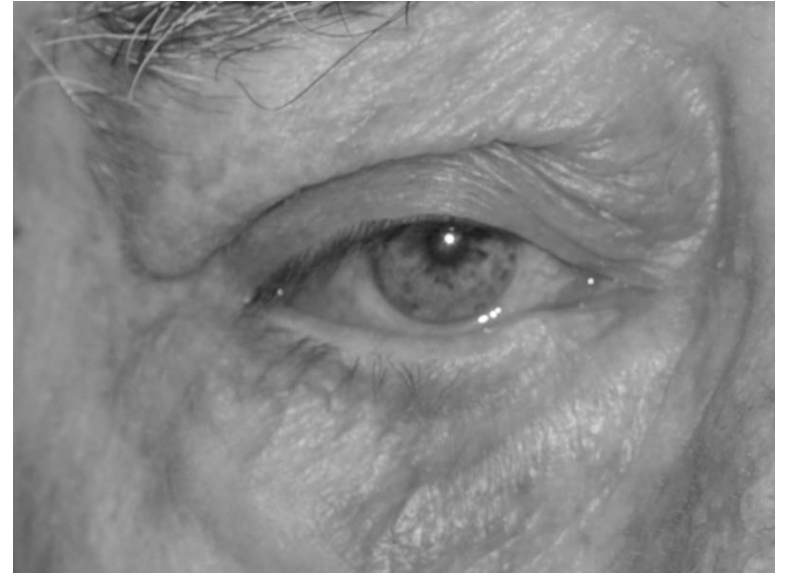
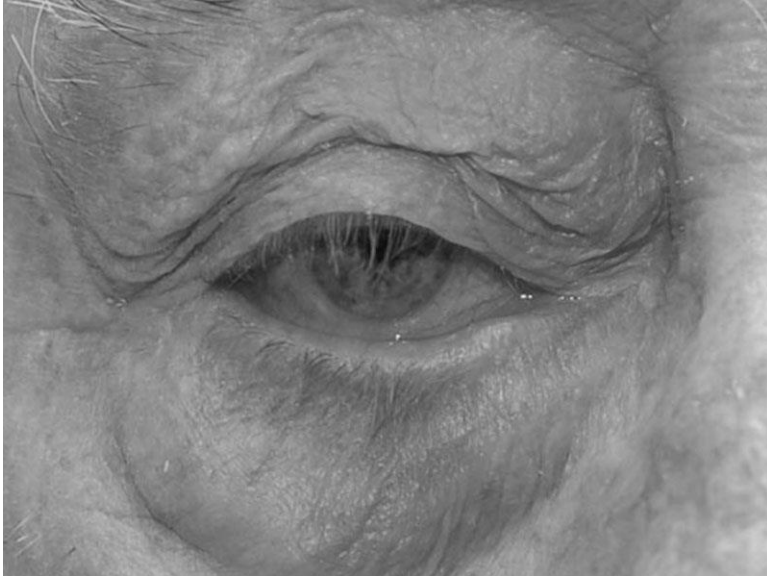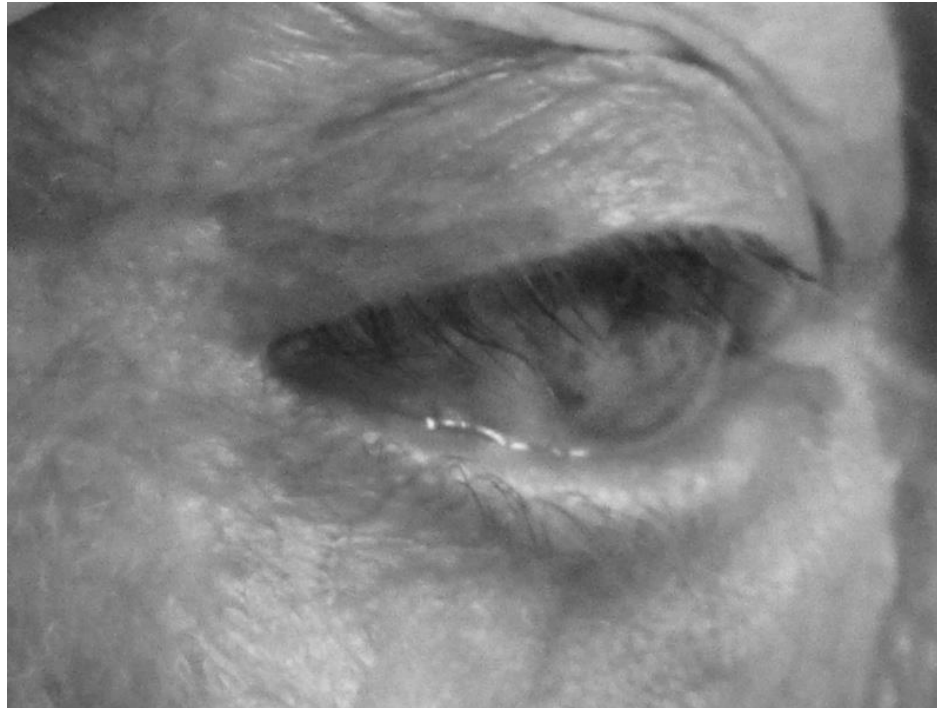


# SDC 2



Supplemental Digital Content 2A, B, C: The pre- and post-operative appearance of a patient after undergoing simultaneous repair of severely lax upper and lower eyelids with the lateral canthal "V" incision and tarsal strip fixation.

## SDC 2c



Supplemental Digital Content 2c: The appearance of a healed lateral canthus after floppy eyelid surgery repair utilizing the lateral canthal "V" incision.