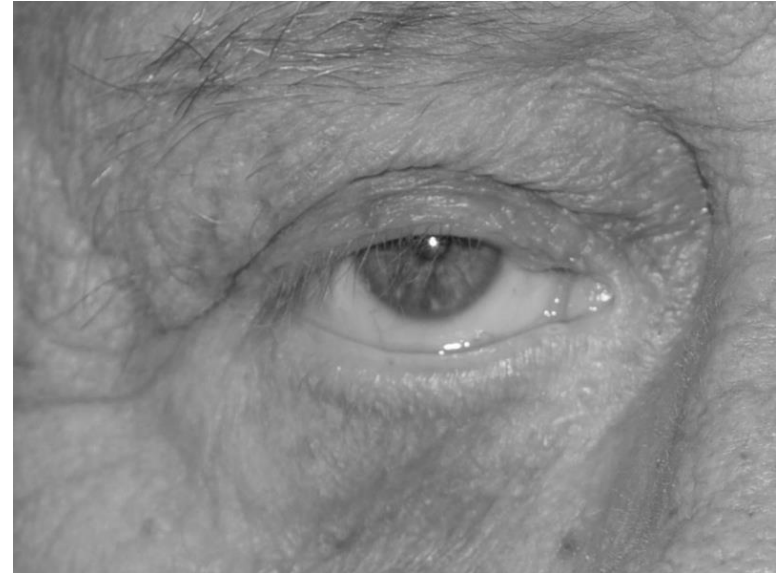
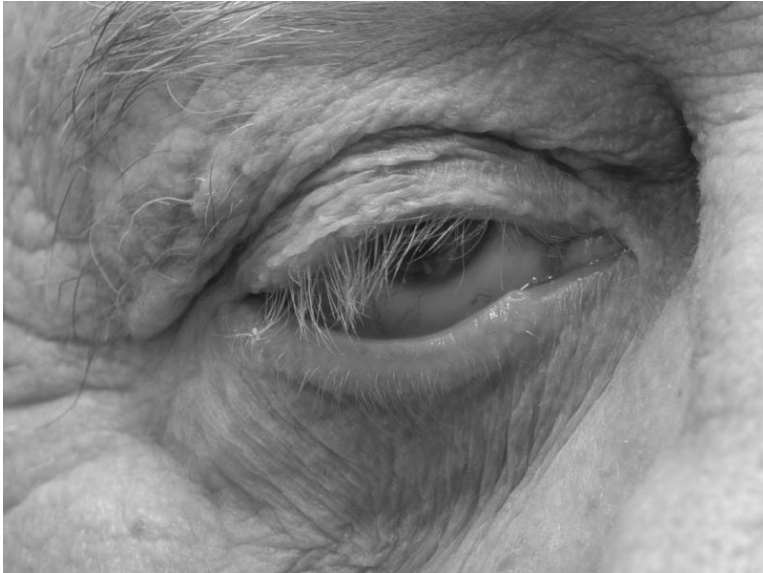

SDC 3



Supplemental Digital Content 3A and B: The pre- and post-operative appearance of a patient after undergoing simultaneous repair of severely lax upper and lower eyelids with the lateral canthal "V" incision and tarsal strip fixation.