

Supplementary file

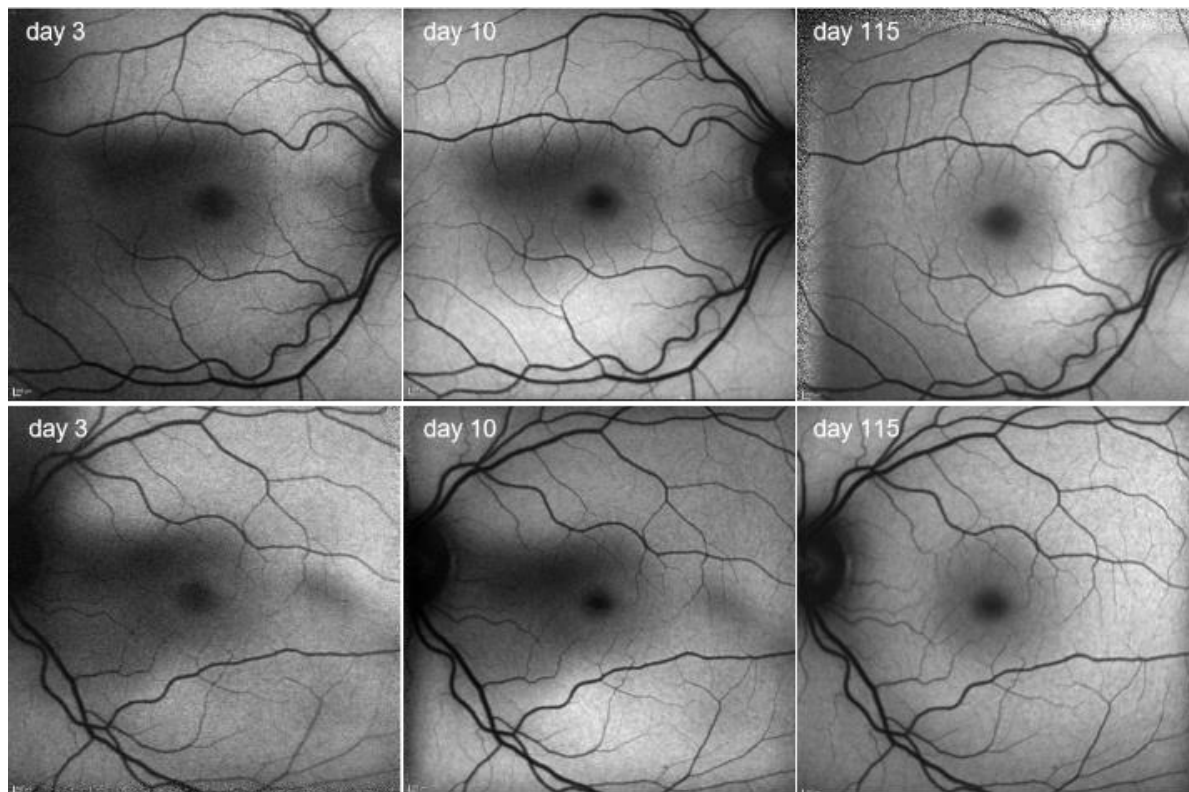


Figure 6: Fundus autofluorescence images of patient 4 obtained with a confocal scanning laser ophthalmoscope (cSLO) demonstrating substantially diminishes autofluorescence in the parafoveal areas in both eyes on day 3 after the incident. Images on day 115 show apparently normal autofluorescence (excitation wavelength of 488nm and an emission filter of 500nm was used; macular pigment markedly reduces autofluorescence and therefore the foveal aspects cannot be evaluated).