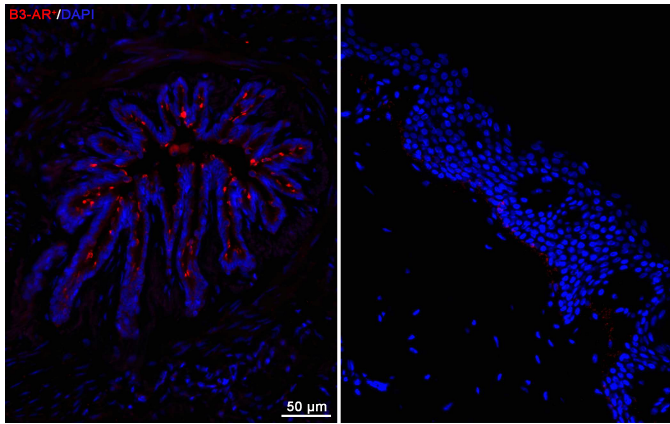


Supplementary – Figure 1



pulmonary bronchus

epidermis