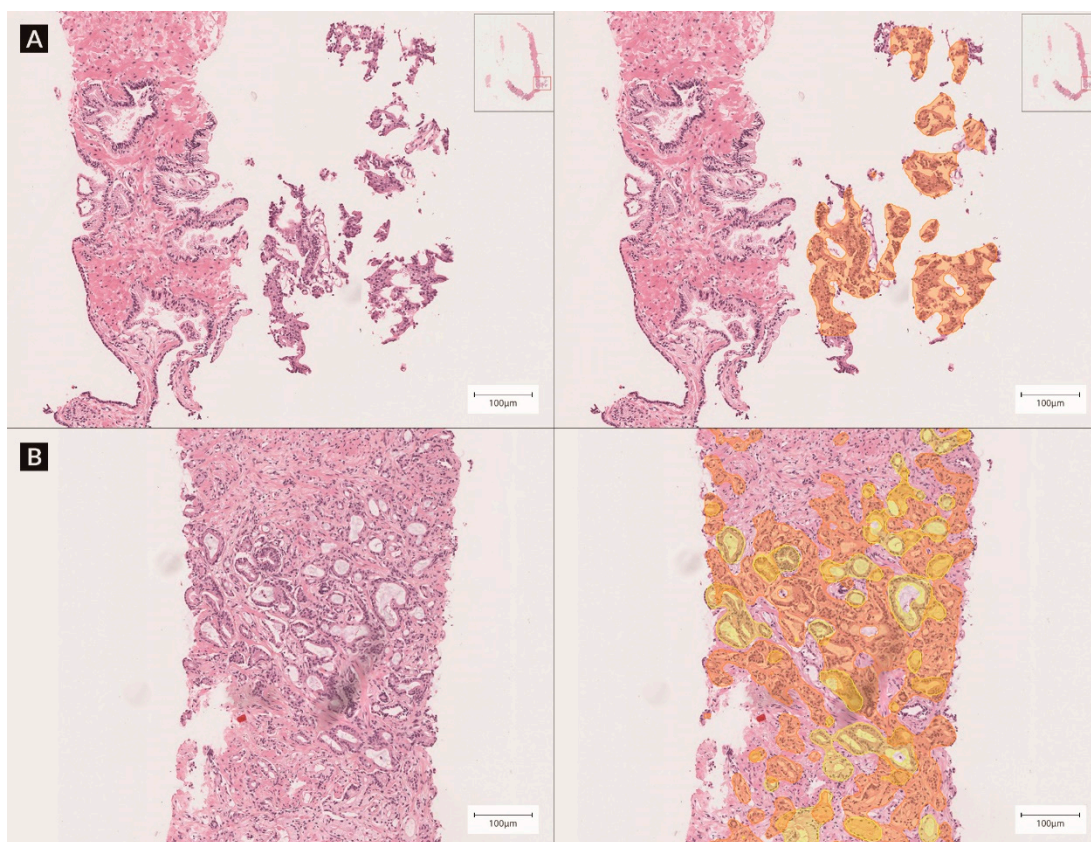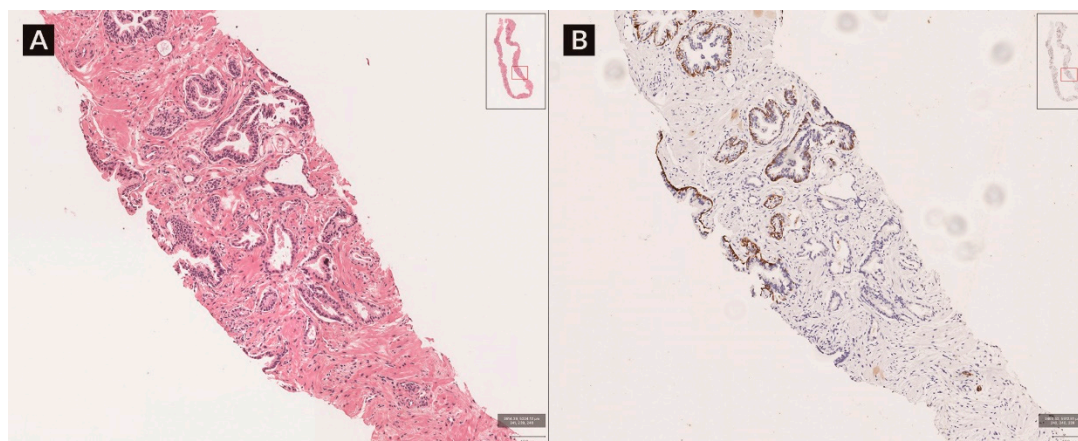
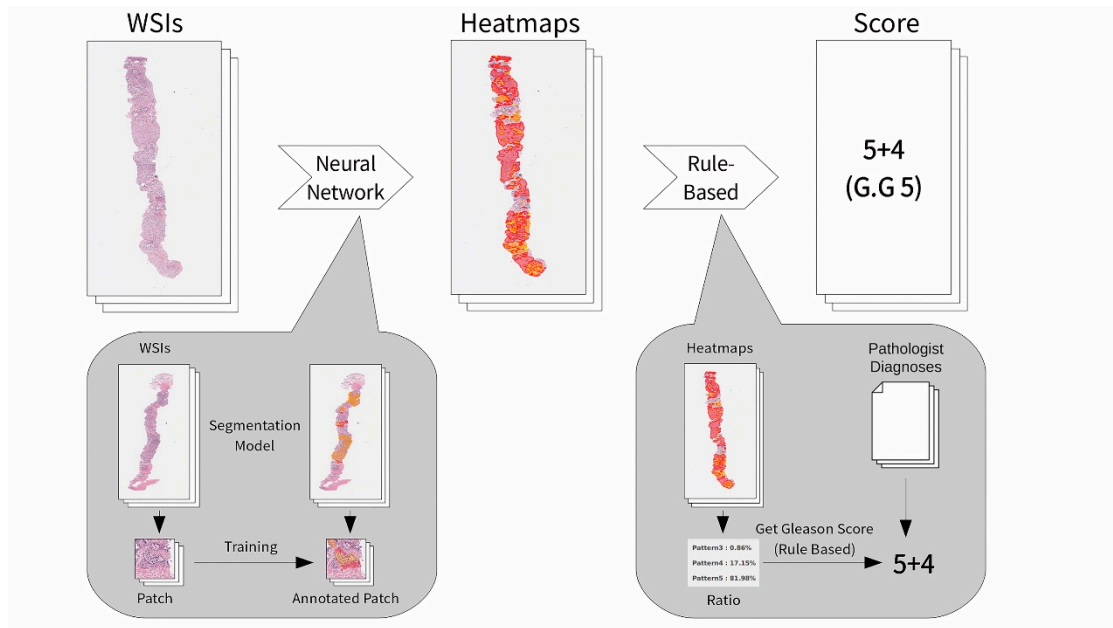


**Figure S1.** Analysis result of poor quality images by DeepDx Prostate. (A) Contains tissue fragments that have separated from the main body. (B) Contains a blurred area.



**Figure S2.** Representative image of atypical small acinar proliferation case and high molecular weight cytokeratin (HMW-CK) staining. Suspicious regions in (A) are confirmed as carcinoma in (B) through HMW-CK staining.



**Figure S3.** The overall algorithm workflow of our system.

**Table S1.** Diagnoses for cases with atypical small acinar proliferation (ASAP) and respective immunohistochemical (IHC) staining requests.

No.	Original diagnoses	Pathologist 1 *	Pathologist 2	Pathologist 3	DeepDx Prostate	IHC Requested
1	ASAP	benign	benign	ASAP	benign	yes
2	ASAP	group 1	group 1	ASAP	group 1	yes
3	ASAP	ASAP	benign	ASAP	benign	yes
4	ASAP	benign	ASAP	benign	benign	
5	ASAP	group 2	group 1	group 1	group 2	
6	ASAP	benign	benign	ASAP	benign	yes
7	ASAP	group 1	group 3	ASAP	group 3	yes
8	ASAP	benign	benign	ASAP	benign	yes
9	ASAP	group 1	group 1	group 1	group 2	
10	ASAP	benign	benign	benign	benign	
11	ASAP	group 1	group 1	group 1	group 2	

\* The genitourinary specialist.