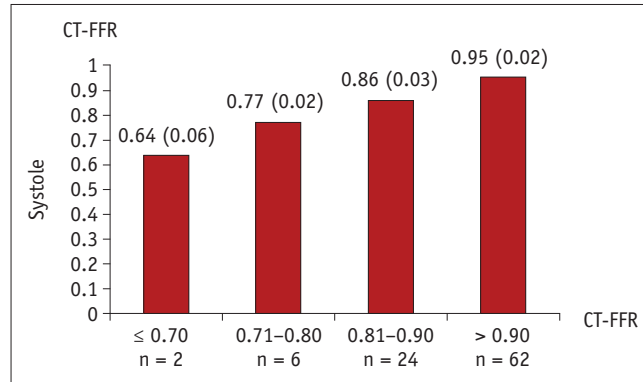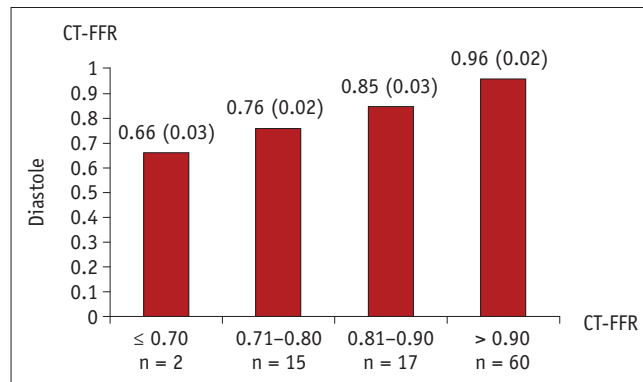
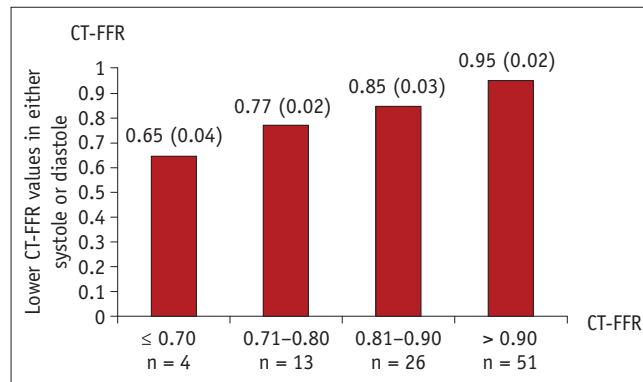


A



B



C

Supplementary Fig. 2. Distribution of CT-FFR values for proximal RCA in this study.