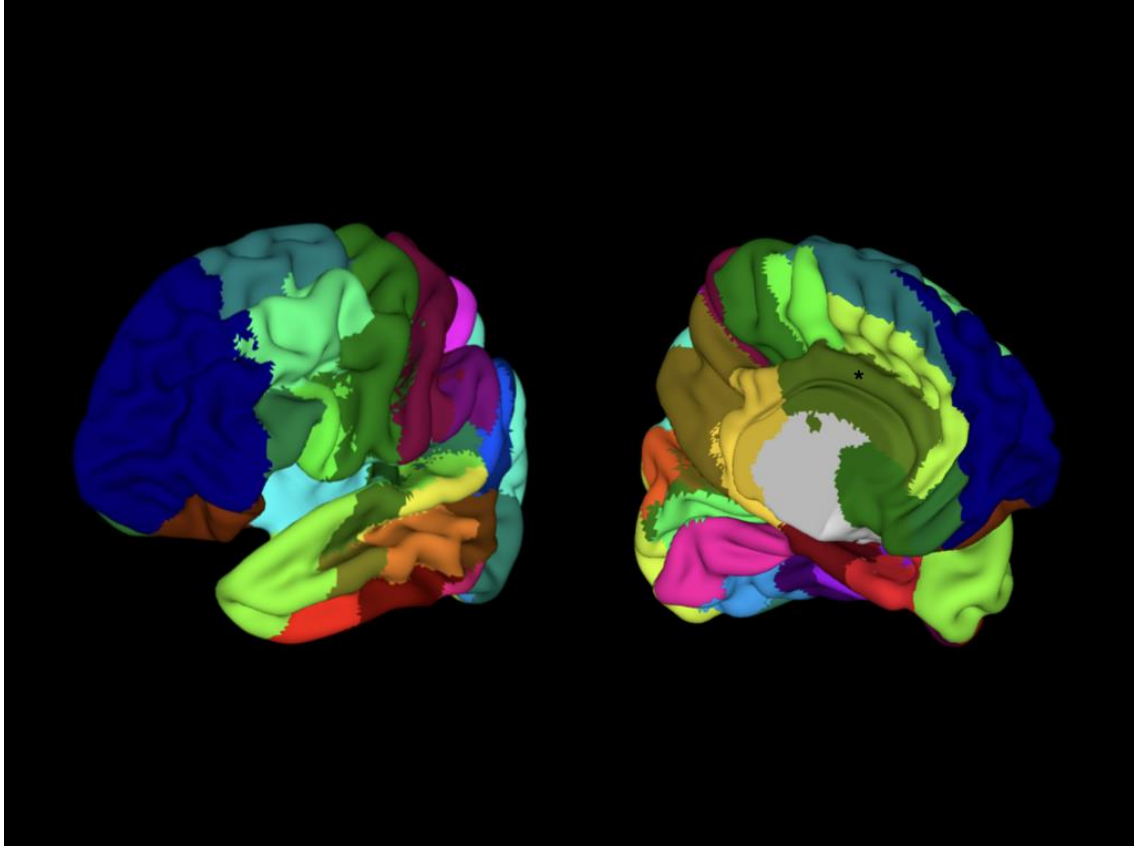
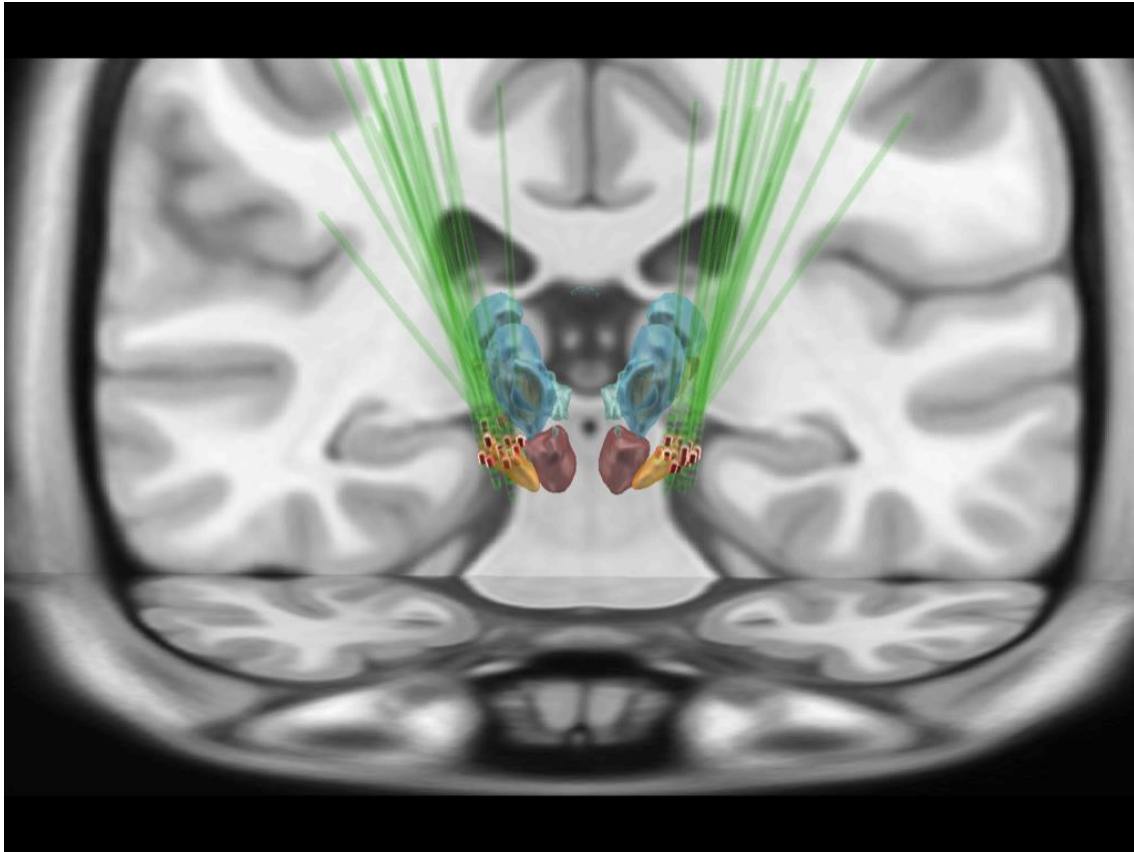


*Supplementary Material*



**Supplementary Figure 1.** Brain parcellations for connectivity correlations according to the human Harvard-Oxford atlas. Dark blue = prefrontal cortex (frontal pole); light blue = insular cortex; purple = post central gyrus; dark green = cingulate gyrus anterior division (\*).



**Supplementary Figure 2.** Coronal view of the lead placement and the active contact (red highlighted) from all patients with pain before surgery. Orange = STN, red = red nucleus.