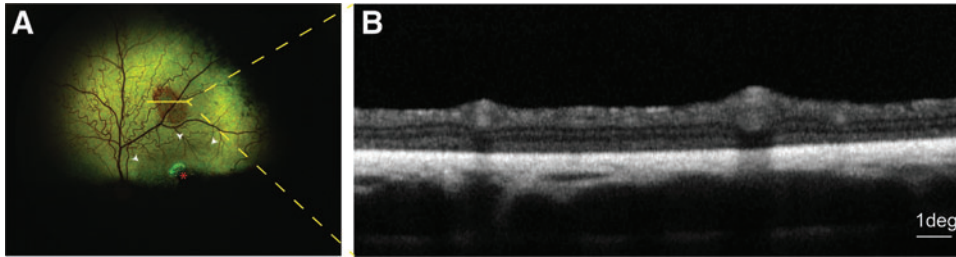


Supplementary Data



Supplementary Figure S1. Suspected light-induced tapetal alteration **(A)** Fundus photography taken at 20 weeks postdosage that illustrates an area of focal brown coloration outside of the treated area (*white arrowheads*), the *yellow line* represents the localization of the OCT-B scan illustrated in **(B)**, the *red asterisk* shows the retinotomy site associated in this case with a focal area of retinal atrophy. **(B)** OCT B-scan through the tapetal change in **(A)** that showed no structural abnormalities of the neuroretina. The retinal thinning observed corresponds to the natural progression of the disease in the untreated (outside of bleb delimitation—*white arrowheads*) retina of an *RPGR* mutant dog at that age. OCT, optical coherence tomography; *RPGR*, retinitis pigmentosa GTPase regulator.
