

Supplementary Figures

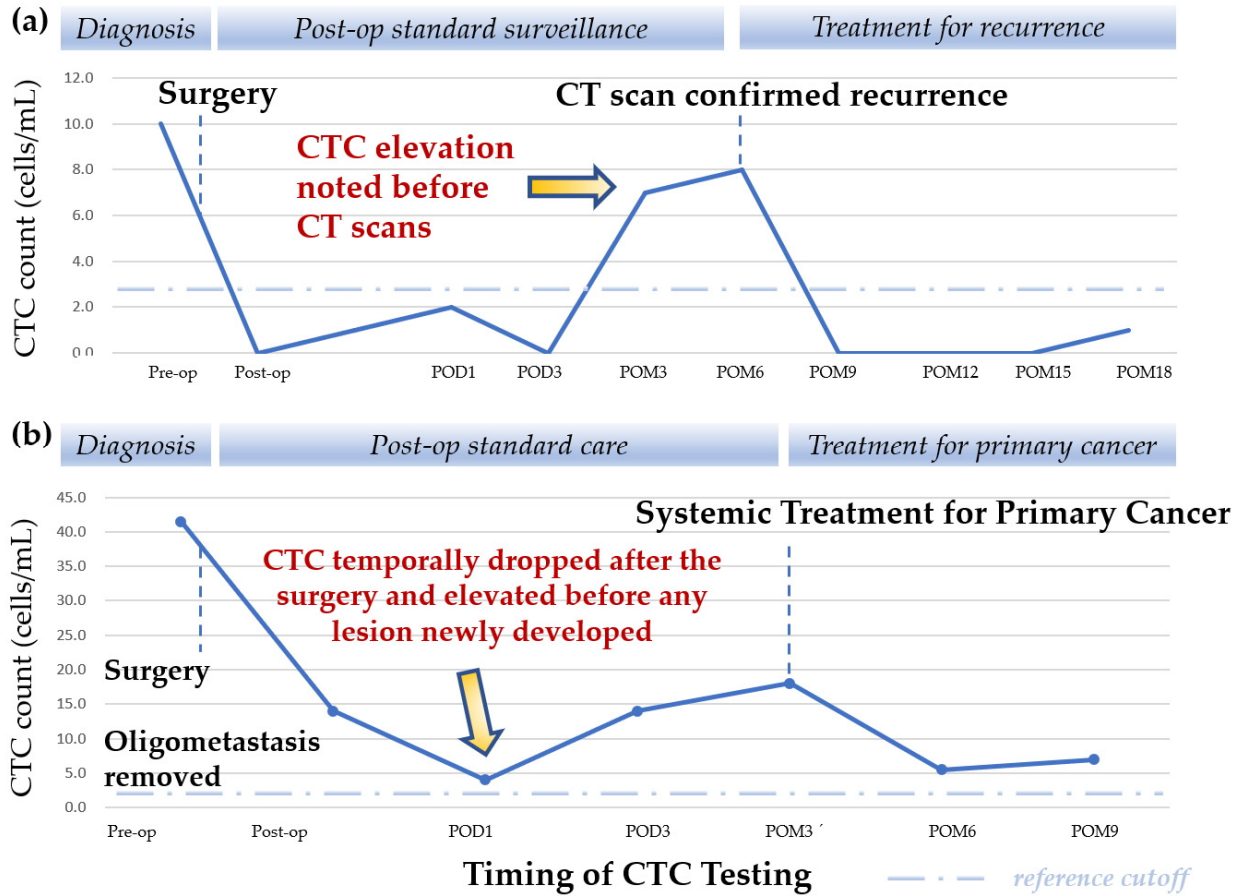


Figure S1. Demonstrations of Possible Role of CTC testing in lung cancer and pulmonary oligometastasis. (a) shows a representative case of CTC testing predicting the recurrence from the primary lung cancer. (b) displays the CTC dynamics during surveillance in a patient later proven to be an oligometastasis from another solid tumor.

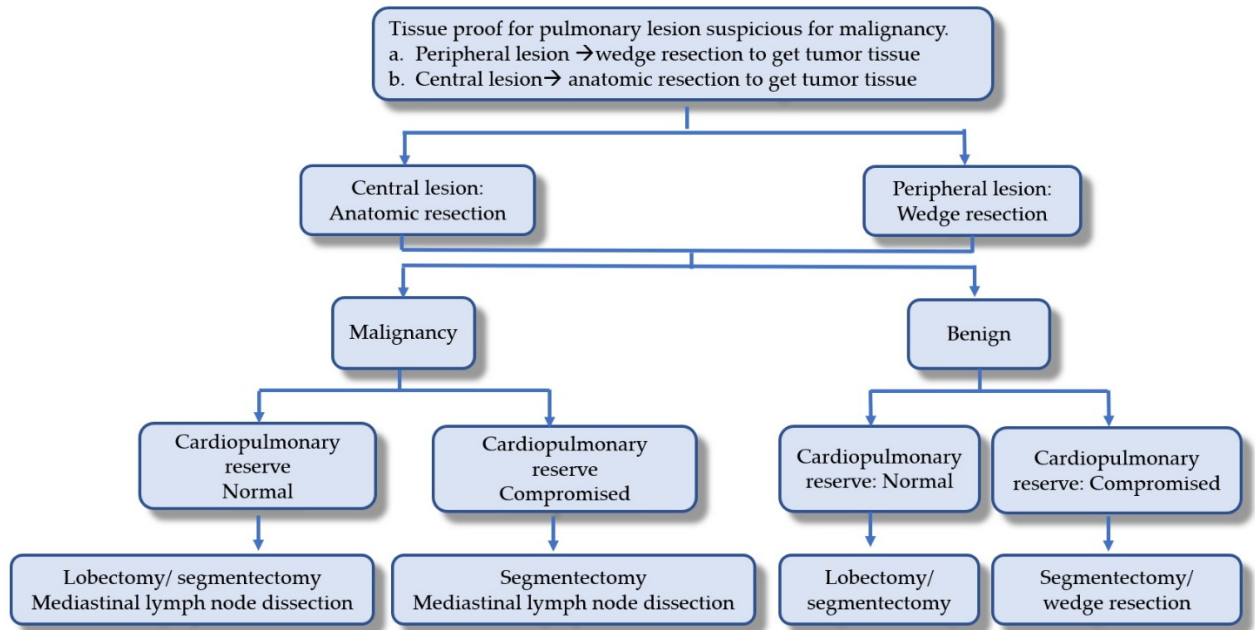


Figure S2. The algorithm of surgical management for pulmonary lesions with a suspicion of malignancy.

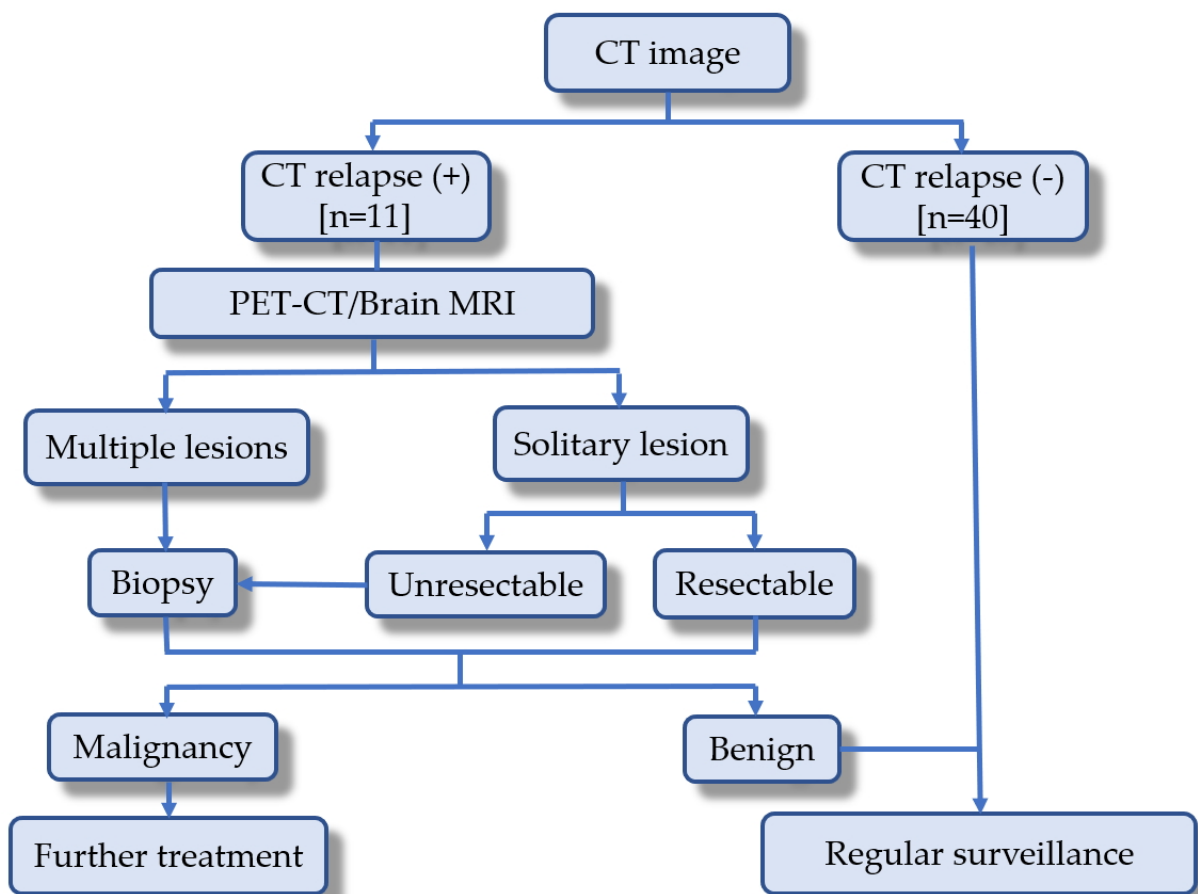


Figure S3. Surveillance algorithm and corresponding management for possible relapse lesions. (Abbreviations: CT, computed tomography; PET, positron emission tomography; MRI, Magnetic Resonance Imaging.).