

APPENDIX:

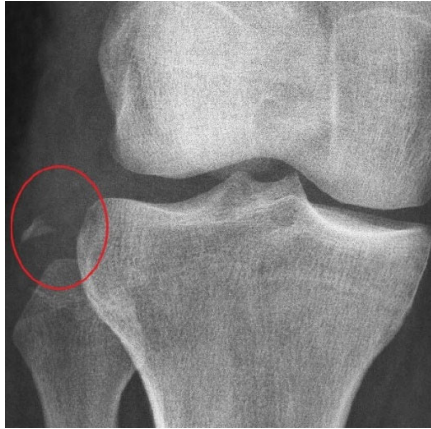


Figure A1 – Segond fracture on coronal radiograph

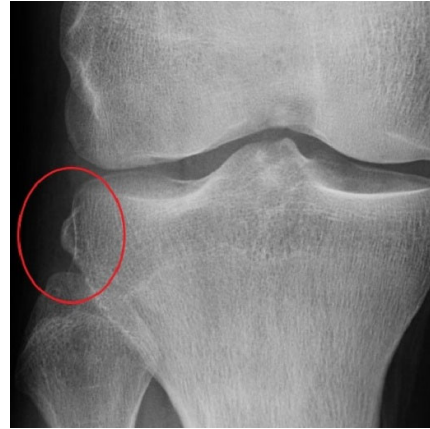

Figure A2 – “Healed Segond” on coronal radiograph

Figure A3 – Healing of identified Segond fractures

