

SUPPLEMENTAL MATERIAL

Peripheral emboli in high resolution DWI after complete endovascular recanalization

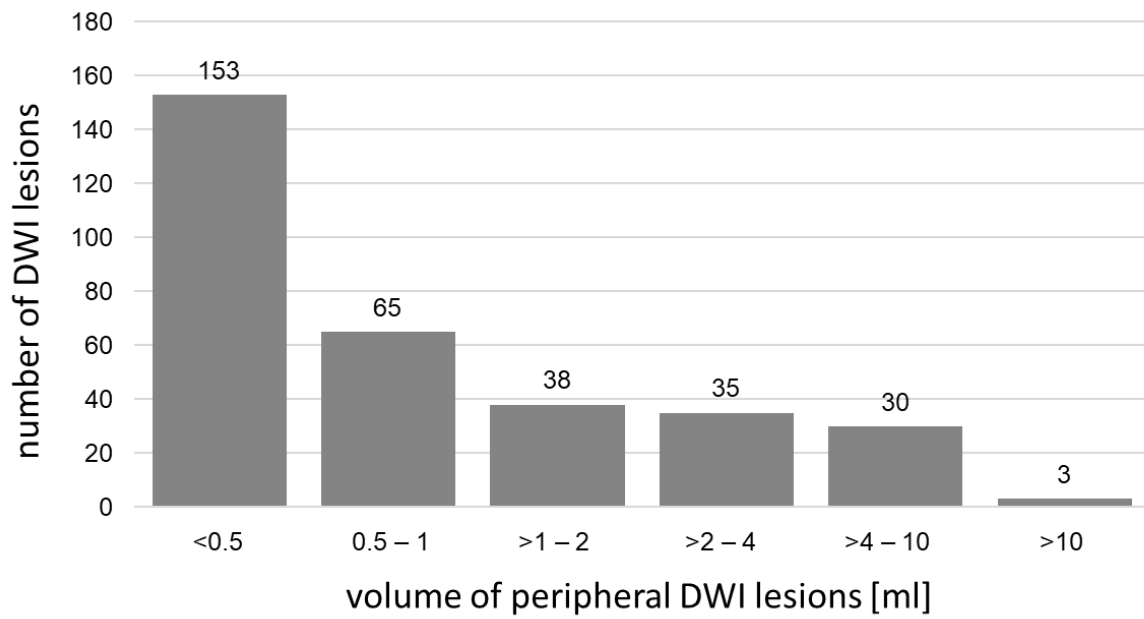


Figure I: Bar chart showing the distribution of peripheral DWI lesions sorted by their volume. 47.2% of peripheral lesions were smaller than 50ml.

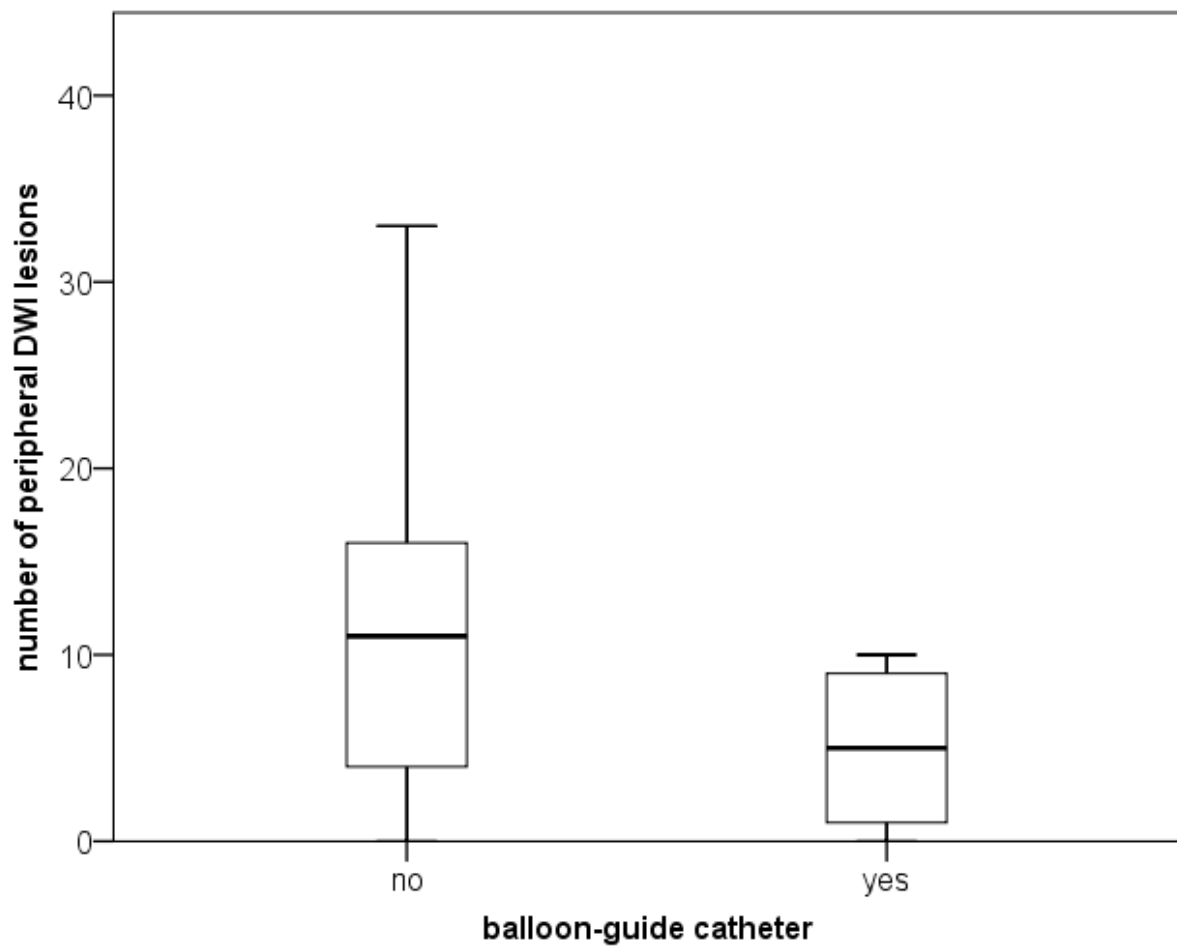


Figure II: Box plot showing a tendency towards a lower number of peripheral lesions on high resolution DWI with the use of a balloon-guide catheter (n=5; median 5, IQR 0.5-9.5) compared to not using a balloon-guided catheter (n=21; median 11, IQR 4-21.5). The difference was not statistically significant (p=0.057).