

Supplementary material

Dupilumab for the Treatment of Atopic Dermatitis in an Austrian Cohort-Real-Life Data Shows Rosacea-Like Folliculitis

Tamara Quint ¹, Patrick M. Brunner ¹, Christoph Sinz ¹, Irene Steiner ², Robin Ristl ², Kornelia Vigl ³, Detlev Pirkhammer ³, Martin Zikeli ⁴, Susanne Kimeswenger ⁵, Wolfram Hötzenecker ⁵, Katharina Neubauer ⁶, Norbert Reider ⁶ and Christine Bangert ^{1,*}

¹Department of Dermatology, Medical University of Vienna, Vienna/Austria

²Institute of Medical Statistics, Medical University Vienna, Vienna/Austria

³Department of Dermatology, Rudolfstiftung City Hospital, Vienna/Austria

⁴Department of Dermatology, Wiener Neustadt Public Hospital, Wiener Neustadt/Austria

⁵Department of Dermatology, Kepler University Hospital, Linz/Austria

⁶Department of Dermatology, Medical University of Innsbruck, Innsbruck/Austria

* Correspondence: christine.bangert@meduniwien.ac.at; Tel.: +43-1-40400-77200

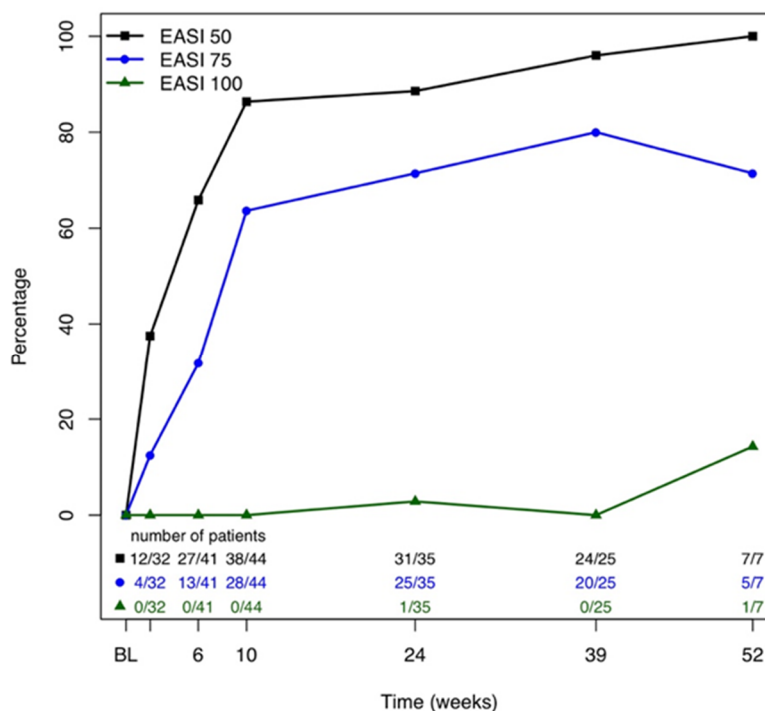


Figure S1. Effectiveness of dupilumab: EASI 50, 75 and 100.