

THE LANCET

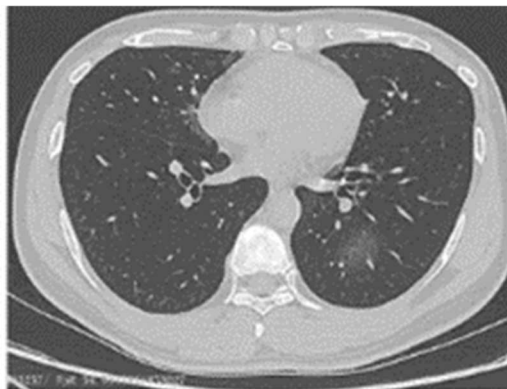
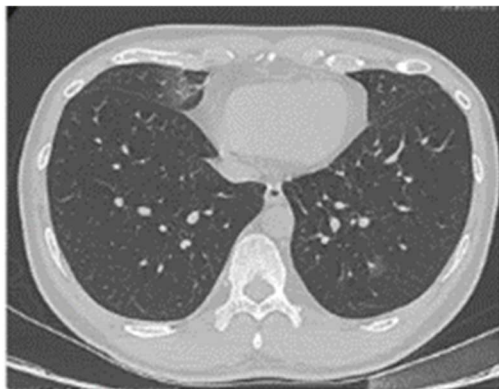
Haematology

Supplementary appendix

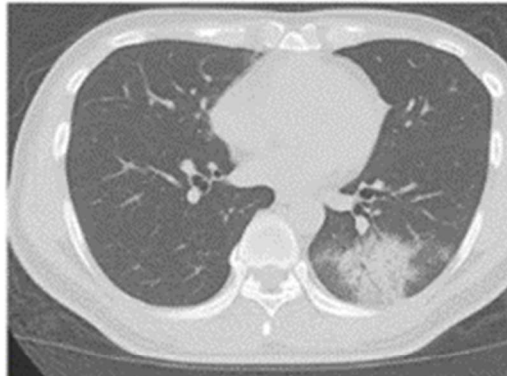
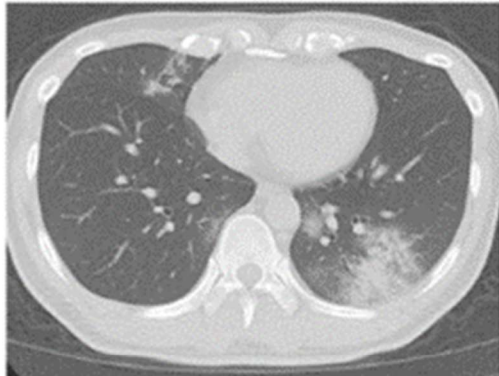
This appendix formed part of the original submission and has been peer reviewed. We post it as supplied by the authors.

Supplement to: Chen W, Yang B, Li Z, Wang P, Chen Y, Zhou H. Sudden severe thrombocytopenia in a patient in the recovery stage of COVID-19. *Lancet Haematol* 2020; published online May 25. [https://doi.org/10.1016/S2352-3026\(20\)30175-7](https://doi.org/10.1016/S2352-3026(20)30175-7).

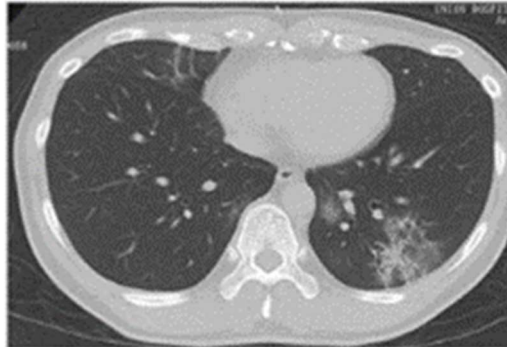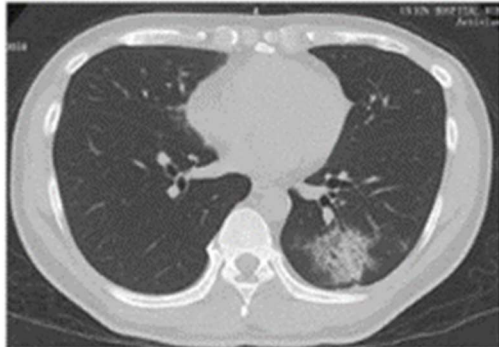Day 13



Day 23



Day 29



Day 42

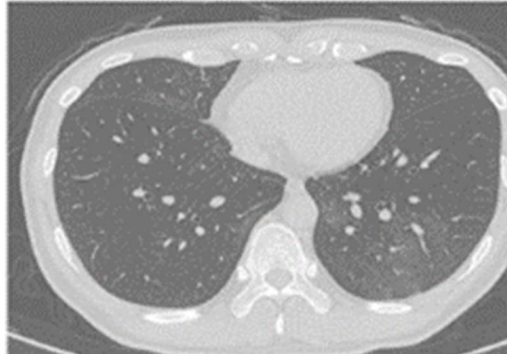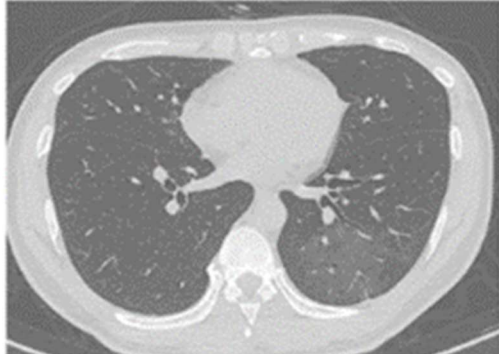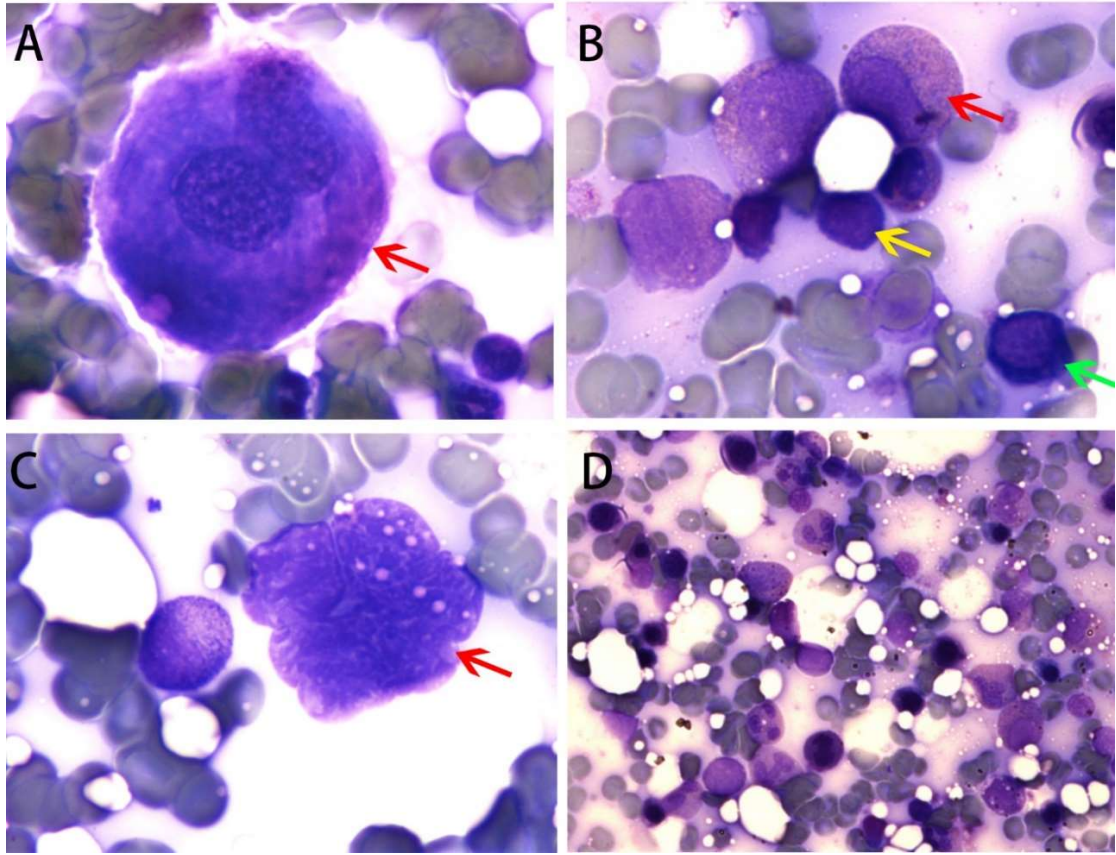


Table 1. The laboratory results at admission and platelet nadir time.

Date		2-11	2-20
Day after onset		Day 20	Day 29
Leukocytic count (cells×10 ⁹ /L)	[Ref] 3.50-9.50	4.74	3.93
Hemoglobin (g/L)	[Ref] 130-175	144	145
Platelet count (cells×10 ⁹ /L)	[Ref] 125 -350	190	2
Neutrophils (cells×10 ⁹ /L)	[Ref] 1.80-6.30	2.55	2.19
Lymphocyte count (cells×10 ⁹ /L)	[Ref] 1.10-3.20	1.67	1.40
D-dimer (mg/L FE)	[Ref] < 0.50	0.22	0.22
Fibrinogen (g/L)	[Ref] 2.00-4.00	5.37	4.40
PT (s)	[Ref] 11.00-16.00	12.90	13.70
APTT (s)	[Ref] 28.00-43.50	40.30	38.70

Table 2. The dynamics of lymphocyte subsets.

Date		2-12	2-20	3-7
Day after onset		Day 21	Day 29	Day 45
CD3 ⁺ T lymphocytes (%)	[Ref] 58.17-84.22	72.72	55.39	73.54
CD4 ⁺ T lymphocytes (%)	[Ref] 25.34-51.37	46.03	31.99	52.81
CD8 ⁺ T lymphocytes (%)	[Ref] 14.23-38.95	21.12	17.94	19.85
CD19 ⁺ B lymphocytes (%)	[Ref] 4.10-18.31	18.62	34.80	16.47
CD56 ⁺ NK lymphocytes (%)	[Ref] 3.33-30.47	6.42	6.31	6.36



A. red arrow: granular megakaryocyte (x1000); B. red arrow: metamyelocyte, yellow arrow: mature lymphocyte, green arrow: rubricyte (x1000); C. red arrow: nude-nuclear megakaryocyte (x1000); D. examine under low magnification (x400).

References

- [1] Yang, M., M.H. Ng, and C.K. Li, *Thrombocytopenia in patients with severe acute respiratory syndrome (review)*. *Hematology*, 2005. 10(2): p. 101-5.
- [2] Magdi, M. and A. Rahil, *Severe Immune Thrombocytopenia Complicated by Intracerebral Haemorrhage Associated with Coronavirus Infection: A Case Report and Literature Review*. *European journal of case reports in internal medicine*, 2019. 6(7): p. 001155-001155.
- [3] Lee, C.Y., et al., *Acute immune thrombocytopenic purpura in an adolescent with 2009 novel H1N1 influenza A virus infection*. *J Chin Med Assoc*, 2011. 74(9): p. 425-7.
- [4] Kaneko, H., et al., *Relapse of idiopathic thrombocytopenic purpura caused by influenza A virus infection: a case report*. *J Infect Chemother*, 2004. 10(6): p. 364-6.
- [5] Joob, B. and V. Wiwanitkit, *Thrombocytopenia: An important presentation of new emerging H7N9 influenza*. *Platelets*, 2014. 25(4): p. 308.
- [6] Karimi, O., et al., *Thrombocytopenia and subcutaneous bleedings in a patient with Zika virus infection*. *Lancet*, 2016. 387(10022): p. 939-940.
- [7] Sharp, T.M., et al., *Zika Virus Infection Associated with Severe Thrombocytopenia*. *Clin Infect Dis*, 2016. 63(9): p. 1198-1201.